

JPET#197020

Title Page

**Chronic Treatment with a Broad Spectrum MMP Inhibitor, Doxycycline,
Prevents the Development of Spontaneous Aortic Lesions in the Mouse Model
of Vascular Ehlers-Danlos Syndrome**

**Hyun-Jin Tae, Shannon Marshall, Jing Zhang, Mingyi Wang, Wilfried Briest, and Mark I.
Talan**

**Laboratory of Cardiovascular Science, National Institute on Aging, Baltimore, MD 21224
(H-J. T., S.M., J. Z., M. W., M.I.T.);**

**Leibniz-Institute for Age Research, Fritz-Lipmann-Institute (FLI) 07745 Jena, Germany
(W.B.).**

JPET#197020

Running Title: **vEDS - doxycycline treatment**

Corresponding author: Mark Talan. MD, PhD

National Institute on Aging

5600 Nathan Shock drive

Baltimore MD, 21224

Phone : 1-410-558-8214

Fax : 1-410-558-8050

E-mail : talnm@mail.nih.gov

23 pages, tables - 1, supplemental tables - 2, 38 references

Word count in the Abstract : 246

Introduction : 556

Discussion : 612

Abbreviations : EDS - Ehlers-Danlos Syndrome; vEDS - Ehlers-Danlos syndrome type IV or vascular subtype; HT - Heterozygous knock out *COL3A1*- deficient mice; Doxy - doxycycline; WT - wild type *COL3A1*- deficient, C.129S4(B6); MMP - metalloproteinase ; IEL - internal elastic lamina ; SEM - standard error of the means; ANOVA - analysis of variance;

Sections: Cardiovascular

Abstract

Aim: There is no proven therapy or prevention for vascular type of Ehlers-Danlos syndrome (vEDS), a genetic disorder associated with mutation of pro-collagen type III and characterized by increased fragility of the vascular and hollow organ walls. Heterozygous *COL3A1*-deficient mice (HT) recapitulate a mild presentation of one of the variants of vEDS, haploinsufficiency for collagen III. Adult HT are characterized by increased metalloproteinase (MMP) activity, reduced collagen content in the arterial walls, and spontaneous development of various severity lesions in aorta. We hypothesized that chronic treatment with MMP inhibitor would increase the collagen content and prevent the development of spontaneous aortic lesions. **Methods and Results:** Heterozygous *COL3A1*-deficient mice (HT) were treated since weaning with broad spectrum MMP inhibitor, doxycycline, added to food. At the age of 9 months MMP-9 expression was twice as high in tunica media of aorta in untreated HT, while total collagen content was 30% lower ($p < 0.01$) and cumulative score of aortic lesions was 8 times higher than in wild type mice WT ($p < 0.01$). After 9 months of doxycycline treatment, MMP-9 activity, collagen content and lesions in aorta of HT were at the level of WT ($p > 0.05$). **Conclusion:** In the mouse model of collagen III haploinsufficiency treatment with broad spectrum MMP inhibitor started early in life normalized increased MMP activity and reduced aortic collagen content in adult and prevented development of spontaneous aortic lesions. Findings provide experimental justification for clinical evaluation of benefit of doxycycline at least in haploinsufficient variety of vEDS patients.

Introduction

Ehlers-Danlos Syndrome (EDS) is a group of connective tissue disorders caused by collagen mutation. According to the Villefranche nosology the disease is subdivided into 6 clinical types (Beighton et al., 1997). Among them, Ehlers-Danlos syndrome type IV or vascular subtype (vEDS, aka Sack-Barabas syndrome, OMIM130050) is the most serious type associated with mutation of pro-collagen type III (*COL3A1*) (Pepin et al., 2000; Germain 2002, 2007). Type III collagen is a homotrimeric fibrillar collagen found abundantly in the wall of arteries, the gastrointestinal tract, the uterus, and in the skin. Within arteries, type III collagen is integrated into the elastin lamellae of the media and the collagenous network of the adventitia (Baxter 2005). As a result of collagen III mutation, the vEDS is associated with increased fragility of the vascular and hollow organ walls. Arterial ruptures, the most serious complication of vEDS, are potentially deadly and usually occur without warning (Arteaga-Solis 2000, Barabas 2000); As a result, life expectancy for vEDS patients is reduced to <50 year (Pepin et al., 2000; Watanabe and Shimada, 2008). Currently there is no established prevention or treatment for vEDS except “common sense” life style modification and genetic counseling (Lum et al., 2011). Recently, results of completed clinical trial (Ong et al, 2010) suggested serious protective benefits of Celiprolol (combination of β_1 adrenergic receptor antagonist with a partial β_2 AR agonist), however the study had some significant limitations because in 40% of participants the mutation was not confirmed through genetic testing.

The absence of reliable animal model for the vEDS hampers the search for effective treatment. A *COL3A1* knockout mouse (*COL3A1*^{tm1Jae}) has been developed previously (Liu et al., 1997) via targeted replacement of the promoter and first exon of the *COL3A1* gene with a

JPET#197020

PGK neo cassette. Resulting total absence of collagen III product from the mutated allele in homozygous knockouts produced a severe, unsustainable, phenotype with >90% perinatal mortality, while heterozygotes, which represent a haploinsufficiency for collagen III, one of the many representation of vEDS, were reported to have no phenotype. We, on the contrary, have recently shown through careful histological evaluation that haploinsufficiency for *COL3A1* in mice characterized by a significant number of spontaneous lesions in the aortic wall of adult mice (started at 9 months of age), and thus recapitulates a mild presentation of vEDS in humans and can serve as an experimental model (Cooper et al., 2010).

MMPs are important players in numerous biological and pathological processes. The ability to degrade extracellular matrix is an important component in the formation of aortic aneurysms (Sternlicht & Werb, 2001). MMPs have a variety sub-types; gelatinases MMP-2 and MMP-9 are mainly involved in degradation of denatured collagen and thus their elevation might induce collagen deficiency in aorta (Collier *et al.*, 1988, Wilhelm *et al.*, 1989, Trocmé *et al.*, 1998, Visse & Nagase, 2003). Therefore normalizing MMP-2 and 9 with broad spectrum MMP inhibitor seemed a logical approach to shift the balance of collagen turnover in a model of collagen haploinsufficiency.

We have reported previously that 3-mo pre-treatment with broad spectrum MMP inhibitor, doxycycline (Doxy), protected aortas of 9-mo old heterozygous *COL3A1*KO mice from lesions induced by physical manipulations (Briest et al 2011). In the present study, we tested a hypothesis that treatment with Doxy starting from weaning would protect aortas of heterozygous *COL3A1* KO mice from development of spontaneous lesions in adulthood.

Materials and Methods

Subjects

Heterozygous *COL3A1*-deficient (HT) mice [strain C.129S4(B6)-*COL3A1**tm1Jae/J*] (Liu et al., 1997) were rederived (The Jackson Laboratory, Bar Harbor, ME) and bred in the vivarium of the National Institute on Aging. The *COL3A1* genotype was determined by polymerase chain reaction (5`-CTTCTCACCCCTTCTTCATCCC-3`, 5`-AGCCTGTTCAAATCGGTACC-3` and neo 5`-GCTATCAGGACATAGCGTTGG-3`) after weaning. Animals were housed and studied in conformance with the National Institutes of Health *Guide for the Care and Use of Laboratory Animals* (1996), with institutional Animal Care and Use Committee approval. Mice were maintained on ad libitum food (NIH-07 mouse/rat diet; National Institutes of Health, Bethesda, MD) with permanent access to filtered water.

Experimental Protocol

Two groups of *COL3A1*-deficient, C.129S4(B6) mice, heterogeneous (HT) and wild type (WT) were treated for 9 months with Doxy starting at 3 weeks of age, i.e., from weaning (HT+Doxy, n=20 WT+Doxy, n=20). Treatment was provided with food (compound ID 5281011) containing 800mg/kg of Doxy (Doxy Diet pellets; BioServ, Frenchtown, NJ). Preliminary measured food intake for this strain was averaged at 3.5 g/day and the average body weight of animals was 25g (Cooper et al., 2010), thus the average drug dose for the experiment was 100 mg/kg per day. Other two groups of WT (n=15) and HT (n=12) mice remained untreated, were maintained on a regular diet (NIH-07 mouse/rat diet), and served as controls. After 9 months, mice were euthanized by overdose of Isoflurane. Hearts, lungs, livers, spleens,

JPET#197020

kidneys and testis were harvested, weighed, and examined with respect to gross histological pathology.

Tissue Collection

The aorta was dissected free from the surrounding connective tissue and pinned onto a wax block before fixation in 10% formalin for 2 days. Cross-sections of the aorta (2 mm in thickness) were placed in 8% agar to create a block with an average of 20 sections of the aorta. The block was stored in 70% ethanol until it was processed and embedded in paraffin (AML Laboratories, Baltimore, MD).

Histological Analysis

Sections (5 μ m) from each block of aortic sections were stained with hematoxylin & eosin and Masson's trichrome. We count the number of lesions present in aortas and rate the severity of each lesion on a subjective scale of 1 to 4 according to previously reported criteria (Cooper et al., 2010, see also Results). Because of their mild nature, as well as a high frequency in WT mice, grade 1 lesions were excluded from statistical analysis. The sum of the scores of lesions \geq grade 2 was added for each animal to produce a cumulative score. Radius of lumen and thickness of each layer in aorta were measured with digital image analyzer (MCID; Inter-Focus Imaging Ltd., Cambridge, UK). Pathologists assessing histological samples for lesions, collagen content, or MMPs expression were blinded with respect to group origin of the samples.

Collagen Detection by Picro-Sirius Red Staining

To examine collagen content in the vessel wall, 5 μ m sections of aorta were stained with picro-sirius red. Digital images of stained sections were obtained from light microscopy using

JPET#197020

polarized filters and analyzed using a MCID digital imaging analysis system (GE Healthcare, USA). The total collagen content in aortic wall as well as collagen content of tunicae adventitia and media separately was calculated as a percentage of the total area of the wall or its respective components (Seeland et al., 2007).

Immunohistochemical staining

For metalloproteinase (MMP) MMP-2 and MMP-9 immunohistochemical analysis aorta sections (5 μ m thick) were cut and placed onto superfrost glass slides. After deparaffinization, sections were incubated in 3% H₂O₂ for 5 min to inactivate endogenous peroxidase. Deparaffinized and rehydrated specimens were boiled in 10 mM citrate buffer (pH 6.0) for 5 min. The samples were cooled to room temperature and incubated with bovine serum albumin (Sigma) for 30 min at room temperature followed by incubation with antibodies overnight at 4°C with MMP-2 (Calbiochem 1:100), MMP-9 (Santa Cruz, 1:200) antibodies. The sections were washed with phosphate-buffered saline (PBS) three times (5 min each) and incubated for 1hr with biotinylated anti-goat and anti-mouse IgG secondary antibodies. After rinsing, immune complexes were visualized by the standard ABC method using the ABC kit. Nuclei were counterstained with hematoxylin, and then examined under microscope.

Statistical Analysis

Numerical data were analyzed and expressed as means \pm S.E.M. A multiple-sample comparison (analysis of variance [ANOVA] and the multiple range tests as post hoc test using the criterion of the least significant differences) was applied to assess the differences between groups. A value of $P < 0.05$ was considered to be significant. Aortic collagen content was

JPET#197020

analyzed using 1-way ANOVA followed by Tukey's post hoc comparison.

Results

Organ anatomy and histology

During the study all mice gained weight according to their age and to the end of 9 months there were no differences in body weight among WT and HT mice untreated or treated with Doxy (Supplemental Table 1). Weight of heart, liver, kidney, spleen, lung, thymus and testis expressed as a ratio to a body weight also did not differ among groups (Supplemental Table 1). Organs had no unusual microscopy or lesions.

Morphometry and histopathology of the aorta

The representative, picro-sirius red stained, slices of aorta viewed under polarized light are presented in Fig.1. There was a trend for reduction of total collagen content in the entire aorta wall and separately in tunica media and adventitia in both thoracic and abdominal segments of aorta among untreated HT mice in comparison with untreated WT mice; there was also a trend for normalization of reduced collagen content in aorta among HT mice treated with Doxy (HT+Doxy) (Supplemental Table 2). However, statistically significant reduction of collagen in HT mice (25 % less than in WT) with its normalization in HT+Doxy mice was observed only in the tunica media of thoracic aorta (Fig. 1 E). Lumen diameter of aorta did not differ between WT and HT mice and was not affected by a Doxy treatment (Table 1). Thickness of t. adventitia was not different among groups and was not affected by treatment. However, thickness of t.

JPET#197020

media was reduced in HT mice compared with WT ($p < 0.05$), but increased in Doxy treated HT mice to the level of WT (Table 1).

Spectrum of lesions in aortic wall among HT mice had been characterized previously (Cooper et al, 2010, Briest et al, 2011) and could be divided into 4 grades according to their severity. All grades of lesions included fragmentation of the internal elastic lamina (IEL). Grade 1 lesions appeared as a small break in the IEL with no significant spindle cell proliferation (not shown). The broken ends of the lamina frequently curled under into the media. In grade 2 lesions, the distance between the fragmented ends of the IEL was wider than in grade 1 (Fig. 2 A, B). Grade 3 lesions were larger, with florid medial spindle cell proliferation and often fragmentation of 1-2 medial elastic laminae (Fig. 2C). In grade 4 lesions (Fig.2D), there was marked and abrupt attenuation of the wall thickness with abundant fibrosis and more severe fragmentation of several elastic laminae (Ramot et al., 2009, Briest et al., 2011). Cooper et al (2010) reported that grade 1 lesions were seen in 55% of studied mice and were distributed equally among WT mice, HT mice of both sexes. For this reason, grade 1 lesions were excluded from statistical analysis. Cumulative lesion score (lesions \geq grade 2) for each group is shown in Fig. 2E. Lesion score was significant, 8-fold higher in HT mice compared to WT. Doxy treatment did not affect cumulative lesion score in WT. The lesion score in HT+Doxy mice was significantly smaller than in HT mice and did not differ from both WT groups.

Immunohistochemistry for MMP-2 & MMP-9

Representative sections of aortas from different groups subjected to immunohistochemical staining for MMP-2 and MMP-9 are shown in Figure 3 A-F. There was a trend for increase of MMP-2 in tunica media among untreated HT mice and its normalization in Doxy treated HT

JPET#197020

animals (Fig. 3G), however statistically significant differences were observed only for MMP-9 (Fig. 3H): MMP-9 expression was significantly elevated in HT mice compared to WT mice and normalized in HT+Doxy mice.

Discussion

Currently there is no animal model for vEDS associated with missense and splicing mutations representing majority of vEDS patients. We have reported a mouse experimental model of heterozygosity for COL3A1 null mutation (Cooper et al 2010). This genetic abnormality represents roughly 4% of vEDS patients, characterized by a milder presentation and delayed onset of symptoms (Leistriz et al., 2011). Our mouse model does not present a significant mortality from aortic or arterial ruptures; it does exhibit, however, a greatly increased number of histologically identifiable lesions of aorta. The HT mice from this model also have lower collagen content in aorta compared with WT (Cooper et al., 2010, Briest et al., 2011) and increased expression of MMPs, particularly MMP-9 (Briest et al., 2011). Thus, this model allows testing of therapeutic interventions to arrest or to alleviate the progression and complications of vEDS.

Doxycycline is a tetracycline antibiotic that is also a non-selective and broad spectrum MMP inhibitor. The effect of Doxy to alleviate the progression of abdominal aortic aneurysm was proven in animal research (Chung et al., 2008; Sheth et al., 2010; Turner et al., 2008; Tedesco et al., 2009; Xiong et al., 2008; Yang et al., 2010) and demonstrated in some clinical studies (Curci et al., 2000; Mosorin et al., 2001; Baxter et al., 2002; Lindeman et al., 2009). Doxy in a sub-

JPET#197020

antimicrobial dose is also the only MMP inhibitor approved by FDA. It is currently used for treatment of periodontal disease (Wennstrom et al., 2001) and rosacea (Del Rosso et al., 2007).

HT mice used in this study demonstrated previously described characteristics of haploinsufficiency for collagen III; reduced collagen content in aorta, particularly tunica media and increased MMP activity, especially MMP-9 (Cooper et al., 2010; Briest et al., 2011). Two gelatinases, MMP-2 and MMP-9 had been considered functionally similar and important in vascular remodeling, particularly in Smooth Muscle Cells (SMC) migration and matrix degradation (Yasumitsu et al., 1992). Eventually it became clear, that their expression in the vascular wall is differently controlled (Whatling et al., 2004); MMP-9 happened to be more important for organization of collagen by SMC than MMP-2, and its expression was more apparent in the presence of vascular injuries (Johnson and Galis, 2004). In the light of these findings it came to no surprise than we observed predominantly elevated expression of MMP-9 in the vascular wall of 9-mo old mice haploinsufficient for collagen III, at the age when aortic lesions in these KO mice became apparent, while MMP-2 expression in aortic wall remained at the level of wild type mice. In our previous study (Briest et al., 2010) we also observe elevated expression on MMP-9 in the aortic wall associated with lesions, but predominant elevation of MMP-2 expression in the skin of COL3A1 heterozygous mice.

Results of the experiment confirmed our hypothesis, treatment with a broad spectrum MMP inhibitor, doxycycline started early in life (immediately after weaning) resulted in normalization of increased MMP activity and normalization of the reduced aortic collagen content in adult, 9-mo old mice. The treatment also prevented development of spontaneous aortic lesions in HT mice. These findings are in concert with our previous report that in the same experimental

JPET#197020

model, 3-mo long treatment with Doxy prevented development of induced lesions of aorta (Briest et al., 2011).

Taking together our findings provide experimental justification for clinical evaluation of doxycycline at least in haploinsufficient variety of vEDS patients. The recommendation for testing this therapeutic intervention for the rest of vEDS patients, whose collagen III is not reduced in volume but have an altered structure, cannot be done on the basis of existing experimental evidences, and development of the adequate mouse model is a crucial next step.

JPET#197020

Authorship Contribution

Participated in research design: Tae, Marshall, Briest, Talan.

Conducted experiments: Tae, Marshall, Zhang.

Performed data analysis: Tae, Talan.

Contributed to interpretation of results: Tae, Talan, Wang

Wrote or contributed to the writing of the manuscript: Tae, Talan, Marshall.

The authors declared that they had no conflicts of interests with respect to their authorship or the publication of this article.

References

- Arteaga-Solis E, Gayraud B, Ramirez F (2000) Elastic and collagenous networks in vascular diseases. *Cell Struct Funct* **25**: 69–72.
- Barabas AP (2000) Ehlers-Danlos syndrome type IV. *N Engl J Med* **343**: 366; author reply 368.
- Baxter BT (2005) Heritable diseases of the blood vessels. *Cardiovasc Pathol* **14**: 185–188.
- Baxter BT, Pearce WH, Waltke EA, Littooy FN, Hallett JW, Jr., Kent KC, Upchurch GR, Jr., Chaikof EL, Mills JL, Fleckten B, Longo GM, Lee JK and Thompson RW (2002) Prolonged administration of doxycycline in patients with small asymptomatic abdominal aortic aneurysms: report of a prospective (Phase II) multicenter study. *J Vasc Surg* **36**: 1-12.
- Beighton P, De Paepe A, Steinmann B, Tsipouras P, Wenstrup RJ (1998) Ehlers-Danlos syndromes: revised nosology, Villefranche (1997) Ehlers-Danlos National Foundation (USA) and Ehlers-Danlos Support Group (UK). *Am J Med Genet* **77**: 31–37.
- Briest W, Cooper T, Tae H, Krawczyk M, McDonnell N, Talan M (2011) Doxycycline Ameliorates the Susceptibility to Aortic Lesions in a Mouse Model for the Vascular Type of Ehlers Danlos Syndrome. *J Pharmacol Exp Ther* **37**: 621-627.
- Chung AW, Yang HH, Radomski MW, Van Breemen C (2008) Long-Term Doxycycline Is More Effective Than Atenolol to Prevent Thoracic Aortic Aneurysm in Marfan Syndrome Through the Inhibition of Matrix Metalloproteinase-2 and -9. *Circ Res*. **102**: e73– e85.
- Collier IE, Wilhelm SM, Eisen AZ, Marmer BL, Grant GA, Seltzer JL, Kronberger A, He CS, Bauer EA, Goldberg GI (1988) H-ras Oncogene-transformed Human Bronchial Epithelial Cells

JPET#197020

(TBE-1) Secrete a Single Metalloprotease Capable of Degrading Basement Membrane Collagen. *J. Biol. Chem* **263**: 6579-6587.

Cooper T, Zhong Q, Krawczyk M, Tae H, Muller G, Schubert R, Myers L, Dietz H, Talan M, Briest W (2010) The haploinsufficientCol3a1 mouse is a model for the vascular Ehlers-Danlos Syndrome. *Vet Pathol* **47**: 1028-1039.

Curci JA, Mao D, Bohner DG, Allen BT, Rubin BG, Reilly JM, Sicard GA and Thompson RW (2000) Preoperative treatment with doxycycline reduces aortic wall expression and activation of matrix metalloproteinases in patients with abdominal aortic aneurysms. *J Vasc Surg* **31**: 325-342.

Del Rosso JQ, Schlessinger J and Werschler P (2007) Comparison of anti-inflammatory dose doxycycline versus doxycycline 100 mg in the treatment of rosacea. *J Drugs Dermatol* **7**: 573-576.

Germain DP (2002) Clinical and genetic features of vascular Ehlers-Danlos syndrome. *Ann Vasc Surg* **16**: 391-397.

Germain DP (2007) Ehlers-Danlos syndrome type IV. *Orphanet J Rare Dis* **2**: 32.

Johnson C, Galis ZS (2004) Matrix metalloproteinase-2 and -9 differentially regulate smooth muscle cell migration and cell-mediated collagen organization. *Arterioscler Thromb Vasc Biol* **24**:54-60.

JPET#197020

Leistriz DF, Pepin MG, Schwarze U and Byers PH (2011) COL3A1 haploinsufficiency results in a variety of Ehlers-Danlos syndrome type IV with delayed onset of complications and longer life expectancy. *Genet Med* **13**:717-722.

Lindeman JH, Abdul-Hussien H, van Bockel JH, Wolterbeek R and Kleemann R (2009) Clinical trial of doxycycline for matrix metalloproteinase-9 inhibition in patients with an abdominal aneurysm: doxycycline selectively depletes aortic wall neutrophils and cytotoxic T cells. *Circulation* **119**: 2209-2216.

Liu X, Wu H, Byrne M, Krane S, Jaenisch R (1997): Type III collagen is crucial for collagen I fibrillogenesis and for normal cardiovascular development. *Proc Natl Acad Sci USA* **94**: 1852–1856.

Lum YW, Brooke BS, Arnaoutakis GJ, Williams TK, Black JH 3rd (2011) Endovascular Procedures in Patients With Ehlers Danlos Syndrome: A Review of Clinical Outcomes and Iatrogenic Complications. *Ann Vasc Surg.* **26**: 25-33. .

Mosorin M, Juvonen J, Biancari F, Satta J, Surcel HM, Leinonen M, Saikku P, Juvonen T (2001) Use of doxycycline to decrease the growth rate of abdominal aortic aneurysms: a randomized, double-blind, placebo-controlled pilot study. *J Vasc Surg* **34**: 606-610.

Ong KT, Perdu J, De Backer J, Bozec E, Collignon P, Emmerich J, Fauret AL, Fiessinger JN, Germain DP, Georgesco G, Hulot JS, DePaepe A, Plauchu H, Jeuemaitre X, Laurent S, Boutouyrie P et al. (2010) Effect of celiprolol on prevention of cardiovascular events in vascular Ehlers-Danlos syndrome: a prospective randomised, open, blinded-endpoints trial. *Lancet* **376**: 1476–1484.

JPET#197020

Pepin M, Schwarze U, Superti-Furga A and Byers PH (2000) Clinical and genetic features of Ehlers-Danlos syndrome type IV, the vascular type. *N Engl J Med* **342**: 673-680.

Plancke A, Holder-Espinasse M, Rigau V, Manouvrier S, Claustres M, Van Kien PK (2009) Homozygosity for a null allele of COL3A1 results in recessive Ehlers-Danlos syndrome. *Eur J Hum Genet* **17**: 1411-1416.

Ramot Y, Manno RA, Okazaki Y, Krakovsky M, Lamensdorf I, Meiron M, Toren A, Zehavi-Goldstein E, Vezzali E, Nyska A (2009) Spontaneous aortitis in the Balb/c mouse. *Toxicol Pathol* **37**: 667–671.

Sastry PS (2002) Matrix metalloproteinase inhibitor therapy to prevent complications as well as therapy for Ehler-Danlos syndrome. *Med Hypotheses* **59**: 314–315.

Seeland U, Selejan S, Engelhardt S, Muller P, Lohse MJ and Bohm M (2007) Interstitial remodeling in beta1-adrenergic receptor transgenic mice. *Basic Res Cardiol* **102**: 183-193.

Sheth RA, Maricevich M, Mahmood U (2010) In vivo optical molecular imaging of matrix metalloproteinase activity in abdominal aortic aneurysms correlates with treatment effects on growth rate. *Atherosclerosis* **212**: 181–187.

Sternlicht MD, Werb Z (2001) How matrixmetalloproteinases regulate cell behavior *Annu. Rev. Cell Dev. Biol* **17**: 463–516.

Tedesco MM, Terashima M, Blankenberg FG, Levashova Z, Spin JM, Backer MV, Sho E, McConnell MV, Dalman RL (2009) Analysis of in situ and ex vivo vascular endothelial growth

JPET#197020

factor receptor expression during experimental aortic aneurysm progression. *Arterioscler Thromb Vasc Biol* **29**: 1452–7.

Trocmé C, Gaudin P, Berthier S, Barro C, Zaoui P, Morel F(1998) Human B lymphocytes synthesize the 92-kDa gelatinase, matrix metalloproteinase-9. *J Biol Chem* **273**: 20677-20684.

Turner GH, Olzinski AR, Bernard RE, Bernard RE, Aravindhana K, Karr HW, Mirabile RC, Willette RN, Gough PJ, Jucker BM (2008) In vivo serial assessment of aortic aneurysm formation in apolipoprotein E-deficient mice via MRI. *Circ Cardiovasc Imaging* **1**: 220–226.

Visse R and Nagase H (2003) Matrix Metalloproteinases and Tissue Inhibitors of Metalloproteinases : Structure, Function, and Biochemistry. *Circ Res.* **92**: 827-839.

Wang M, Lakatta EG (2002) Altered regulation of matrix metalloproteinase-2 in aortic remodeling during aging. *Hypertension* **39**: 865-873.

Watanabe A and Shimada T (2008) Vascular type of Ehlers-Danlos syndrome. *J Nippon Med Sch* **75**: 254-261.

Wennstrom JL, Newman HN, MacNeill SR, Killoy WJ, Griffiths GS, Gillam DG, Krok L, Needleman IG, Weiss G and Garrett S (2001) Utilization of locally delivered doxycycline in non-surgical treatment of chronic periodontitis. A comparative multi-centre trial of 2 treatment approaches. *J Clin Periodontol* **28**: 753-761.

Wilhelm SM, Collier IE, Marmer BL, Eisen AZ, Grant GA, Goldberg GI (1990) SV40-transformed human lung fibroblasts secrete a 92-kDa type IV collagenase which is identical to that secreted by normal human macrophages. *J Biol Chem* **264**: 17213-17221.

JPET#197020

Xiong W, Knispel RA, Dietz HC, Ramirez F, Baxter BT (2008) Doxycycline delays aneurysm rupture in a mouse model of Marfan syndrome. *J Vasc Surg* **47**: 166–172.

Yang HH, Kim JM, Chum E, van Breemen C, Chung AW (2010) Effectiveness of combination of losartan potassium and doxycycline versus single-drug treatments in the secondary prevention of thoracic aortic aneurysm in Marfan syndrome. *J Thorac Cardiovasc Surg* **140**: 305–312.

Yasumitsu H, Miyazaki K, Umenishi F, Koshikawa N, Umeda M. (1992) Comparison of extracellular matrix-degrading activities between 64-kDa and 90-kDa gelatinases purified in inhibitor-free forms from human schwannoma cells. *J Biochem (Tokyo)* **111**: 74–80.

JPET#197020

Footnotes

This Work was fully supported by the Intramural Research Program of the National Institute on Aging (NIA), the National Institutes of Health.

Figure legends

Figure 1. Collagen content of aorta in 9-mo old mice. x400 representative Picro-Sirius Red stained slides of aortas of 9-mo old mice viewed under polarized light. Arrows indicate tunica media. Wild type *COL3A1*-deficient (C.129S4(B6) untreated mice (WT) (A), WT, doxycycline treated (WT+Doxy) (B), Heterozygous *COL3A1*-deficient untreated mice (HT) (C), and HT doxycycline treated (HT+Doxy), (D). Average content of collagen in thoracic aorta (TA) (E) and abdominal aorta (AA) (F). Values are means±S.E.M. ANOVA with Duncan post-hoc test, * - p<0.05.

Figure 2. Spontaneously developed lesions in aortas of 9-mo old mice. A-D – typical representations of spontaneous lesions. Sections stained with Masson's trichrome. (A) – lesion grade 2 in WT. (B) Section of aorta from lesion grade 2 in HT. (C) - lesion grade 3 lesion; a large defect in the internal elastic lamina and significant sub-intimal spindle cell proliferation with deposition of collagen. (D) Lesion grade 3, similar to grade 4 but defect area much large. (E) - Cumulative lesion score (lesions ≥ grade 2) in each group. Values are means±S.E.M. * - p<0.05, ANOVA with Tukey post-hoc test.

Figure 3. MMP-2 and MMP-9 in aortas of 9-mo old mice untreated or treated with doxycycline since weaning. Representative immunohistochemical staining of aorta from different groups for MMP-2 (A, B, C) and for MMP-9 (D, E, F). Quantitative presentation of MMP-2 (G) and MMP-9 (H) in tunica media. Values are means±S.E.M. * - p<0.05, ANOVA with Tukey post-hoc test.

JPET#197020

Table 1. Average thickness of aortic wall in 9-mo old WT and HT untreated or treated with Doxycycline since weaning

	WT	WT+Doxy	HT	HT+Doxy	ANOVA
Diameter of Lumen (μm)	664.05 \pm 44.37	619.64 \pm 21.05	667.65 \pm 44.45	606.57 \pm 20.17	
Thickness of Adventitia (μm)	23.12 \pm 2.97	19.84 \pm 1.11	20.79 \pm 3.82	16.69 \pm 1.18	
Thickness of Media (μm)	28.57 \pm 1.14 ^{AB}	30.74 \pm 0.92 ^A	25.56 \pm 1.29 ^B	29.51 \pm 1.27 ^A	*

Values are means \pm S.E.M; * - $p < 0.05$, ANOVA with post-hoc Tukey test. Different letters indicate significant difference from other groups.

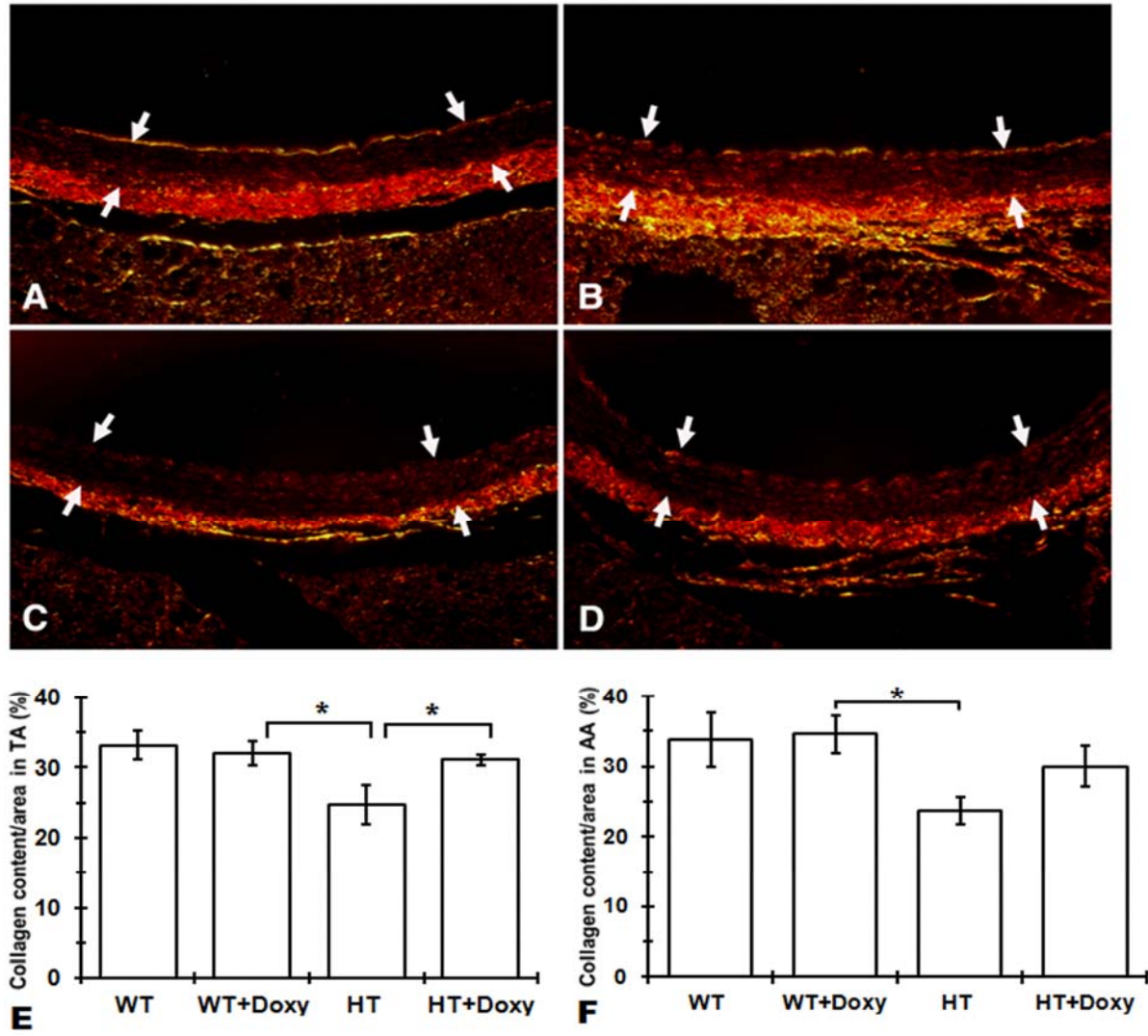


Figure 1.

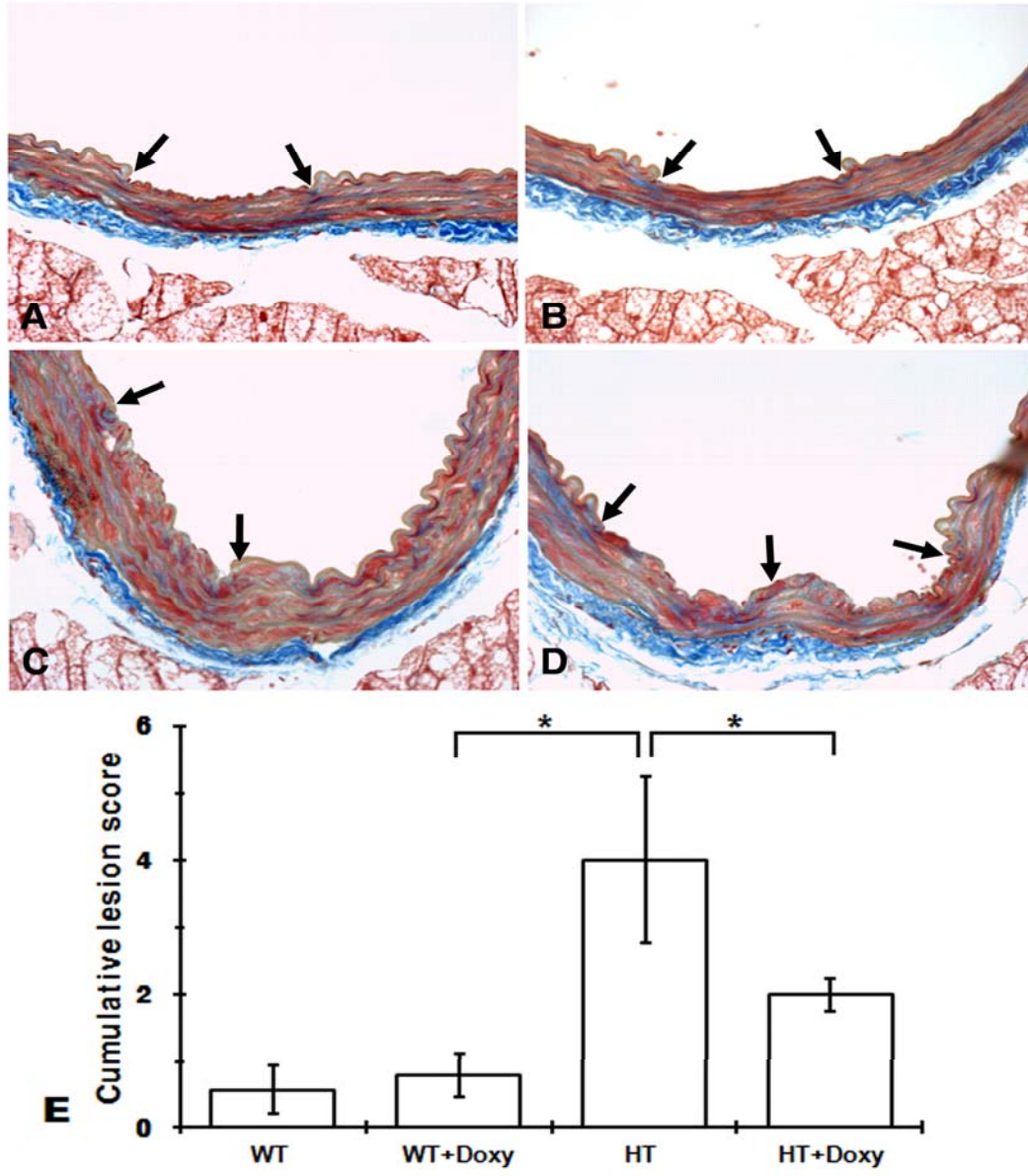


Figure 2.

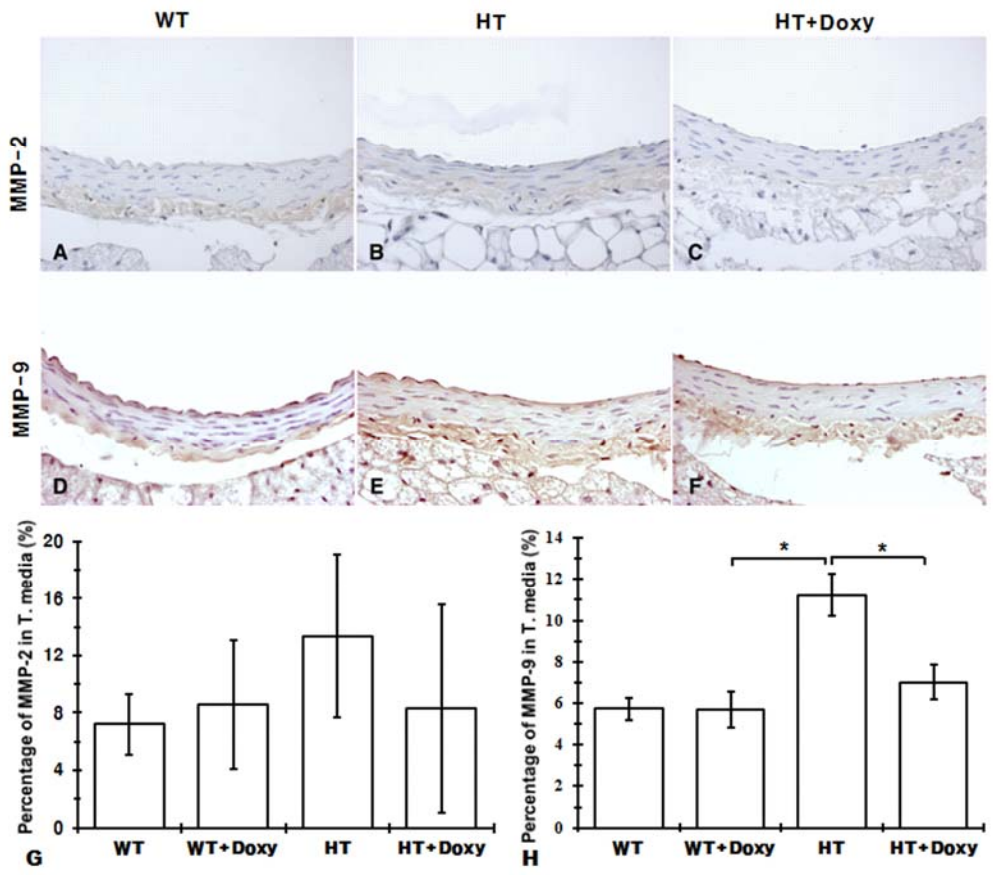


Figure 3.