

JPET #203067

Title Page

**Neuroprotective Effects of Cilostazol on Retinal Ganglion Cell damage in
Diabetic Rats**

Kyoung In Jung, Jie Hyun Kim, Hae-Young Lopilly Park, Chan Kee Park

Department of Ophthalmology and Visual Science, Seoul St. Mary's Hospital,
College of Medicine, The Catholic University of Korea, Seoul, Korea

Running Title Page

Running title: Neuroprotective effects of cilostazol in diabetic retina

* Address correspondence and reprint requests to Chan Kee Park, M.D., Ph.D
Department of Ophthalmology and Visual Science, Seoul St. Mary's Hospital ,
College of Medicine, The Catholic University of Korea, Seoul, Korea
505 Banpo-dong, Seocho-ku, Seoul 137-701, Korea
Tel.: 82-2-2258--6199, FAX: 82-2-599-7405
E-mail: ckpark@catholic.ac.kr

The number of text pages: 13

The number of tables: 1

The number of figures: 5

The number of references: 48

The number of words in the Abstract: 224

The number of words in Introduction: 649

The number of words in Discussion: 1245

The English in this document has been checked by at least two professional editors,
both native speakers of English. For a certificate, please see:

<http://www.textcheck.com/certificate/Kp0r0w>

JPET #203067

Abbreviations:

DR	Diabetic retinopathy
GFAP	Glial fibrillary acidic protein
OLETF	Otsuka Long-Evans Tokushima Fatty
LETO	Long-Evans Tokushima Otsuka
RGC	Retinal ganglion cell
VEGF	Vascular endothelial growth factor

Section: Endocrine and Diabetes

JPET #203067

Abstract

Neurodegeneration is an important component of diabetic retinopathy with increasing evidence that retinal ganglion cell (RGC) death occurs early in diabetes. We investigated the effects of cilostazol, which has been widely used to manage diabetic complications, on retinal ganglion cell death in diabetic retina. Four-week-old Otsuka Long-Evans Tokushima Fatty (OLETF) rats and Long-Evans Tokushima Otsuka (LETO) rats as matched nondiabetic controls were treated with daily oral cilostazol at 30mg/kg or 0.9 % saline solution. In OLETF rats at the age of 40 weeks, glial fibrillary acidic protein (GFAP) immunofluorescence staining was upregulated in vertical sections and showed a more ramified pattern in whole-mount retinas compared with that in LETO rats. Vascular endothelial growth factor (VEGF) expression was limited to the ganglion cell layer in LETO rats, but extended into the outer plexiform layer in OLETF rats. Immunofluorescence staining and western blotting demonstrated that cilostazol treatment reduced GFAP and VEGF expression in the retinas of OLETF rats. Terminal deoxynucleotidyl transferase-mediated dUTP nick-end labeling (TUNEL) staining revealed an increase in the RGC layer in OLETF compared with LETO rats ($P<0.05$), and cilostazol treatment reduced the number of TUNEL-positive cells in OLETF rats ($P<0.05$). Relieving retinal ischemia by systemic cilostazol treatment had a noticeable protective effect on RGCs in diabetic rats. Cilostazol treatment may be useful for the management of diabetic retinal vascular dysfunction and neuronal degeneration.

Introduction

Diabetic retinopathy (DR) is a common microvascular complication of diabetes and a leading cause of blindness in developed countries (Cheung et al., 2010; Cheung and Wong, 2008; Miller et al., 1997). Despite advances in diabetes care, proliferative diabetic retinopathy and other complications develop after 30 years in up to 20% of patients with diabetes who have been treated with intensive metabolic control (Nathan et al., 2009).

Diabetics develop a prothrombic state, involving endothelial dysfunction, platelet dysfunction, and impaired coagulation (Mina et al., 2007; Natarajan et al., 2008; Schafer and Bauersachs, 2008). DR is characterized by a progressive alteration of retinal microvasculature (Miller et al., 1997). Over time endothelial cells die resulting in capillary closure and areas of non-perfusion, which lead to retinal hypoxia. Increased areas of tissue non-perfusion stimulate the production of angiogenic factors such as vascular endothelial growth factor (VEGF) from the retina leading to pathological neovascularization and subsequent loss of vision (Miller et al., 1997).

Although microvascular changes are undeniably integral to retinopathy, the retina is a vascularized neural tissue, not a network of blood vessels. New insights into retinal physiology suggest that the retinal dysfunction associated with diabetes may be viewed as a change in the retinal neurovascular unit (Antonetti et al., 2012). The neurovascular unit refers to the physical and biochemical relationships among neurons, glia, and specialized vasculature and the close interdependency of these tissues in the central nervous system. There is increasing evidence that retinal ganglion cell (RGC) death occurs early in diabetes and that neurodegeneration is an important component of diabetic retinopathy (Abu-El-Asrar et al., 2004; Barber et al., 1998). Several studies have established that there are significantly more neuronal

JPET #203067

cells undergoing apoptosis, particularly in the ganglion cell layer (GCL), in retinas of diabetic rats than in those of control rats (Asnaghi et al., 2003; Barber et al., 1998; Sima et al., 1992). When diabetes exerts its primary damage on vascular cells and increases permeability or vascular occlusion, neuronal and glial cell integrity is compromised by the entry of circulating macrophages, antibodies, inflammatory cytokines, and excitotoxic amino acids into the retina (Antonetti et al., 2006). Some have proposed that diabetes causes retinal neuropathy through a microvascular mechanism (Abu-El-Asrar et al., 2004; Antonetti et al., 2006; Barber, 2003; Barber et al., 1998).

If the neurovascular unit is similarly involved in diabetes, then new therapeutic approaches addressing both vascular dysfunction and neural degeneration may be required. In fact, many recent studies have identified the central role of VEGF as a main focus for developing treatment in vascular lesions observed in DR, and blocking VEGF action is a main focus for developing a treatment for this debilitating disease. Although anti-VEGF treatment may block vascular leakage and neovascularization, it may also impair the neuronal protective effect of VEGF (Zhang et al., 2009). Therefore, we considered that the improvement of ischemia to reduce VEGF release may be critical before blocking VEGF to enhance neurovascular unit circuit in the early stage of DR.

Cilostazol, a reversible selective inhibitor of phosphodiesterase-3A, has antiplatelet, antithrombotic and vasodilatory properties (Chapman and Goa, 2003). Inhibition of phosphodiesterase-3A leads to increased intracellular levels of cAMP, which, in turn exerts vasculoprotective actions (Chapman and Goa, 2003). Cilostazol appears to have a favorable effect in preventing the progression of carotid atherosclerosis and intracranial arterial stenosis (Katakami et al., 2010; Kwon et al., 2005). Given the

JPET #203067

prothrombotic state and increased baseline risks for cerebral and myocardial infarction associated with diabetes, antiplatelet therapy such as cilostazol has been recommended to control the hypercoagulable state in diabetic patients (Ajjan and Grant, 2011; Angiolillo, 2009; Geng et al., 2012; Hillegass et al., 2011).

In the present study, we evaluated the effects of cilostazol, which has been widely used to manage diabetes, on neurodegeneration in experimental diabetes as a therapeutic strategy of relieving ischemia; specifically, its effects on glial activation, VEGF expression, and retinal cell death (especially ganglion cells) triggered by diabetes.

Materials and Methods

Animals

All animals were cared for and all procedures for this study were performed in accordance with the Laboratory Animals Welfare Act, Guide for the Care and Use of Laboratory Animals and Guidelines and Policies for Rodent Experiments provided by the Institutional Animal Care and Use Committee of the School of Medicine, Catholic University of Korea.

In vivo treatment of rats

Four-week-old Otsuka Long-Evans Tokushima Fatty (OLETF) rats and Long-Evans Tokushima Otsuka (LETO) rats as the matched nondiabetic controls were obtained from the Otsuka Pharmaceutical Co., Ltd. (Tokushima, Japan). They were housed in the animal facility for 25 weeks before use; They were kept in a clean room at $22.5\text{ }^{\circ}\text{C} \pm 1\text{ }^{\circ}\text{C}$ and relative humidity of $50\% \pm 10\%$, with an automatic 12-h light-dark cycle. They were allowed free access to gamma-ray sterilized diet (Pico 5053,

JPET #203067

LabDiet / America) and autoclaved tap water in a specific pathogen-free environment. After 25 weeks, the OLETF and LETO rats were randomly divided into two groups for daily oral administration (mixed in the chow) with either Cilostazol (Pletal; Otsuka Pharmaceutical Co. Tokyo, Japan) at 30mg/kg or 0.9% saline (NaCl) solution (control group) for 15 weeks.

Measurements of plasma glucose

An intraperitoneal glucose tolerance test was performed in each rat after a 12-h fasting period. An intraperitoneal injection of 25% glucose solution (dose, 2 g/kg) was administered. Blood glucose levels were measured before glucose injection and at 30, 60, 90, and 120 min after glucose loading, using a blood glucose monitoring system (Acucheck; Roche Diagnostics Ltd., Indianapolis, IN, USA).

Tissue preparations

For immunofluorescence staining, eyes were enucleated at each time point and dissected, and the posterior eyecups were placed in chilled fixative (4% paraformaldehyde in 0.1 M phosphate buffer, pH 7.4). The retina was dissected from the choroid, and isolated retinas were trimmed into small pieces. After washing several times with PBS, the fixed retinas were cryoprotected in 0.1 M phosphate buffer containing 30% sucrose for 6 h at 4°C and then stored in this buffer at -70°C. For Western blot analysis, retinal tissues were quickly dissected, frozen in liquid nitrogen, and stored at -70 °C.

Immunofluorescence staining

Retinal samples were embedded in 3% agar in deionized water, and vibratome

JPET #203067

sections (thickness, 50 μ m) were cut. After several washes in PBS, the sections were incubated in 10% normal donkey serum in PBS for 1 h at room temperature to block nonspecific binding sites. Then, the sections were incubated with mouse anti-GFAP (Glial fibrillary acidic protein; Chemicon, Temecula, CA, USA) or anti-VEGF antibody (Abcam, Cambridge, UK) overnight at 4°C. After several more washes with PBS, the sections were incubated with Alexa 546-labeled goat anti-mouse IgG (A-11010; Molecular Probes, Eugene, OR, USA). For double-labeling studies, the sections were incubated with mouse anti-NeuN antibody (MAB377; Chemicon, Temecula, CA, USA) in 0.1 M PBS containing 0.5% Triton X-100 overnight at 4°C, rinsed for 30 min with 0.1 M PBS, and incubated with Alexa 488-labeled goat anti-mouse IgG (A-11001; Molecular Probes) for 1.5 h at room temperature. After the sections were washed in 0.1 M PBS for 30 min, nuclei were stained with DAPI. The sections were mounted using VECTASHIELD mounting medium, covered with coverslips, and examined under a confocal laser scanning microscope (Zeiss, Germany).

Western blot analysis.

Retinas of LETO and OLETF rats were homogenized respectively in RIPA buffer (1% Triton X-100, 5% SDS, 5% deoxycholic acid, 0.5 M Tris-HCl, pH 7.5, 10% glycerol, 1 mM EDTA, 1 mM phenylmethylsulfonyl fluoride, 5 mg/ml aprotinin, 1 mg/ml leupeptin, 1 mg/ml pepstatin, 200 mM sodium orthovanadate, and 200 mM sodium fluoride). The homogenates were incubated for 10 min on ice and clarified by centrifugation at 12,000 rpm for 25 min at 4°C. Total protein in the retinal extracts was measured using a standard BCA assay (Pierce, Rockford, IL, USA). Retinal extracts (40 mg total protein per sample) were mixed with sample buffer (60 mM

JPET #203067

Tris-HCl, pH 7.4, 25% glycerol, 2% SDS, 14.4 mM 2-mercaptoethanol, and 0.1% bromophenol blue) at a 4:1 ratio, boiled for 5 min, and resolved by SDS-PAGE. The proteins were transferred from the gel onto a nitrocellulose membrane. The membrane was stained with Ponceau S (Sigma, St. Louis, MO, USA) to visualize the protein bands and ensure equal protein loading and uniform transfer. The blots were washed and blocked by incubation in 5% skim milk in TBST buffer (20 mM Tris-HCl, pH 7.6, 137 mM NaCl, and 0.1% Tween 20) for 45 min. Then, the blots were incubated with antibodies against GFAP (Cell Signaling, Boston, MA, USA), VEGF (Abcam), or actin (A4700; Sigma) for 24 h, followed by incubation with horseradish peroxidase-conjugated goat anti-rabbit IgG as the secondary antibody. Immunoreactive proteins were detected by enhanced chemiluminescence (Amersham, Piscataway, NJ, USA). Relative intensity was measured using an ImageMaster VDS (Pharmacia Biotech, Piscataway, NJ, USA), and the fold changes in protein levels were determined. The results were provided as mean \pm standard error of the mean (n=5).

Terminal deoxynucleotidyl transferase-mediated dUTP nick-end labeling

Terminal deoxynucleotidyl transferase-mediated dUTP nick-end labeling (TUNEL) assay was performed according to the manufacturer's instructions (In Situ Cell Detection Kit; Roche, Mannheim, Germany). Briefly, cryopreserved retinal tissue from 40-week-old OLETF and LETO rats were immersion-fixed with freshly prepared 4% paraformaldehyde in 0.1 M phosphate buffer (pH 7.4) for 20 min. Vibratome sections (thickness, 50 μ m) were cut from the frozen retinas, thawed, and rinsed in 0.01 M PBS (pH 7.4). To increase tissue permeability, the sections were incubated in 0.1% sodium citrate containing 0.1% Triton X-100 for 2 min on ice. After rinsing in

JPET #203067

PBS, 50 μ L of TUNEL reaction mix (calf thymus terminal deoxynucleotidyl transferase and nucleotides) were added to each sample. After incubation for 60 min in the dark at 37°C, the sections were rinsed and nuclei were stained with DAPI (H-1200; Vector Laboratories, Burlingame, CA, USA). The Sections were washed, covered with coverslip, and observed under a confocal laser scanning microscopy (Zeiss, Germany).

Statistical analysis

All data are expressed as means \pm SD. Statistical analyses were performed using SPSS software, version 17.0 (SPSS Inc., Chicago, IL, USA). Differences between the LETO and OLETF rats were analyzed using the Mann-Whitney *U* test. Results with a p-value <0.05 were considered statistically significant.

Results

Body weight and glucose levels in OLETF and LETO rats

At 25 and 40 weeks of age, the body weights of OLETF rats were higher than those of the control LETO rats (Table 1). At 25 and 40 weeks of age, the plasma fasting glucose level was similar between OLETF and LETO rats (Figure 1). At 25 and 40 weeks, the postprandial 2-h glucose levels were higher in OLETF rats, irrespective of cilostazol treatment than in LETO rats (Figure 1, $P<0.05$). Treatment with cilostazol did not reduce both the fasting glucose level and postprandial 2-h glucose level.

Immunofluorescence staining of GFAP and VEGF, and the effect of cilostazol

GFAP immunostaining was performed to evaluate glial cell activation in response to retinal stress caused by diabetes and the effect of cilostazol (Figure 2). At 40 weeks

JPET #203067

of age, GFAP immunoreactivity in vertical sections of LETO retinas was restricted to astrocytes and the end feet of Müller cells at the inner limiting membrane, whereas OLETF retinas showed more GFAP immunoreactivity in astrocytes and in the processes of the Müller glia that spanned the entire inner retina. In whole mounts, OETF retinas displayed more GFAP immunostaining and a more ramified pattern compared with immunostaining in LETO retinas. Cilostazol treatment induced a decrease in GFAP immunostaining and a reduced branching pattern in OLETF retinas.

VEGF expression was increased in OLETF rat retinas compared with LETO rat retinas (Figure 3). In OLETF rats, VEGF immunostaining was observed extensively throughout the retina, from the ganglion cell layer to the outer plexiform layer. Co-localization with NeuN, a RGC marker, demonstrated that the VEGF immunoreactivity in the GCL occurred in the cytoplasm of RGCs in both LETO and OLETF rats. Cilostazol treatment decreased VEGF immunoreactivity in both LETO and OLETF rats with a more remarkable reduction in OLETF rats.

Western blot analysis of GFAP and VEGF, and effects of cilostazol

To quantitatively evaluate GFAP and VEGF levels, we performed an immunoblot analysis of retinal proteins (Figure 4). At 40 weeks of age, the protein levels of both GFAP and VEGF were significantly higher in OLETF rat retinas ($P<0.05$), which is consistent with the immunofluorescence observations. Cilostazol treatment decreased the protein levels of both GFAP and VEGF in OLETF and LETO rat retinas, although the changes were statistically significant only in OLETF rats ($P<0.05$).

JPET #203067

Apoptotic cell death, and the effect of cilostazol

Apoptotic cell death was determined by TUNEL staining (Figure 5). Very few TUNEL-positive retinal cells were observed in LETO rats. Comparatively, the OLETF rats exhibited more TUNEL-positive retinal cells, especially in the ganglion cell layer ($P<0.05$). Cilostazol treatment reduced the number of TUNEL-positive cells significantly in OLETF rats ($P<0.05$).

Discussion

To preserve vision in DR, it is essential to treat both the vascular and neural elements of the retina. Given the specialized compartmentalization in the retina, glia, neuron, and vascular integrity are required for its metabolic functions. Glial activation and retinal ischemia in diabetic rats were confirmed by elevated GFAP and VEGF, respectively. Retinal stress and ischemia were improved by cilostazol treatment. Another important finding of this study was that cilostazol treatment attenuated RGC death, or retinal neurodegeneration, induced by diabetes. The study results suggest that cilostazol may exert neuroprotection in DR by curtailing retinal ischemia, and enhancing the neurovascular circuit.

In the present study, VEGF expression was increased in diabetic rats. Several mechanisms have been shown to participate in the regulation of VEGF expression; hypoxia is one of the most important, although prolonged hyperglycemia, advanced glycation end products, and various growth factors and inflammatory cytokines also regulate VEGF mRNA expression (Ferrara, 2004; Simo et al., 2006). In response to the hypoxia underlying DR, Müller cells, retinal endothelial cells, and pericytes express VEGF, thereby stimulating angiogenesis (neovascularization) and increasing capillary permeability. Given the vascular state in DR, VEGF upregulation

JPET #203067

in diabetic rats reflects an ischemic state of the retina. Increased expression of cytokine/chemokines such as VEGF may serve to maintain neuronal function under stressful conditions such as DR. Over time, however, this becomes maladaptive, as progressive vascular damage ultimately results in macular edema and neovascularization (Antonetti et al., 2006).

Beyond glucose-induced microvascular disease, DR affects neurons, and glia as well as vascular cells (Aizu et al., 2002; Fong et al., 2003). In the present study, the GFAP expression level was higher in diabetic OLETF rats than in LETO rats. Elevated GFAP, or glial reactivity, occurs in many neurodegenerative diseases and after ischemia-reperfusion, and it is considered a sensitive indicator of central nervous system injury (O'Callaghan, 1991; Osborne and Larsen, 1996). Bai et al. recently demonstrated that retinal Müller cell-derived VEGF is a major contributor to ischemia-induced retinal vascular leakage and pre-retinal and intra-retinal neovascularization (Bai et al., 2009). Therefore, the combination of Müller cell activation and VEGF upregulation could also reflect an ischemic state in DR.

We demonstrated that the increased VEGF and GFAP distribution throughout the retina in DR was reversed by cilostazol administration. Cilostazol also attenuates the increase in VEGF in the kidneys of diabetic rats (Wang et al., 2008). In one report, renal VEGF expression increased 1.6-fold in diabetes, and this was ameliorated by cilostazol administration; the effect was more evident in the high-dose group than in low-dose group (Wang et al., 2008). Cilostazol did not improve blood glucose levels; thus, its beneficial effects are clearly unrelated to the correction of hyperglycemia (Shindo et al., 1993). In post-ischemic rat retinas, cilostazol was also reported to have a significant protective effect against ischemia-induced retinal damage by suppressing the interaction between leukocytes and endothelial cells

JPET #203067

(Iwama et al., 2007). Given that VEGF is a hypoxia-induced angiogenic factor, the suppression of VEGF induced by cilostazol may imply that retinal ischemia was resolved. In addition, the inhibition of increased VEGF may eventually result in reduced vascular leakage and pathological neovascularization. The efficacy of cilostazol on VEGF expression in DR can be also explained by its pharmacological properties. The pharmacological actions of cilostazol are mediated mainly through elevated intracellular cyclic AMP due to inhibition of phosphodiesterase-3A activity. Since platelets contain phosphodiesterase-3A, this mechanism appears to explain the inhibition of platelet function (Ikeda, 1999). Cilostazol inhibits not only platelet aggregation but also thromboxane A₂ formation and platelet factor 4 release. These inhibitory effects on platelet functions are due to decreased intracellular Ca²⁺ concentration caused by elevated cyclic AMP levels. An arterial vasodilation by cilostazol mediated through its direct action on vascular smooth muscle cells (Shiraishi et al., 1998). Those antiplatelet and antithrombotic, and vasodilation effect of cilostazol may support the protective results of it on diabetic retinopathy which is characterized by retinal microvascular alterations and subsequent ischemia. Given that milrinone also has the effect of phosphodiesterase 3-inhibitor as cilostazol, it would be worthwhile to investigate it as a neuroprotective agent on diabetic retinopathy (Wesley et al., 2009).

TUNEL staining in diabetic retinas revealed cellular apoptosis, especially in the ganglion cell layer. The expression of apoptotic mediators such as caspase-3, Fas, and Bax has been reported in ganglion cells of human subjects with diabetes mellitus (Abu-El-Asrar et al., 2004). In the current study, ganglion cells in diabetic retinas were the most vulnerable population. This corresponds with previous studies reporting that neural retinal defects are among the earliest detectable changes in

JPET #203067

diabetes (Abu-El-Asrar et al., 2004; Barber et al., 1998). The oxygen tension of the inner retina is relatively hypoxic with a pO₂ of only about 25 mmHg compared with 80 mmHg in the outer retina (Ahmed et al., 1993; Pournaras, 1995; Wangsa-Wirawan and Linsenmeier, 2003). Thus, ganglion cells in the inner retina may be more susceptible to ischemia induced by diabetes.

Reducing ischemia by cilostazol treatment not only decreased VEGF production, but also reduced retinal neuronal apoptosis. Considering that retinal neuropathy could be caused by a microvascular mechanism, relief of ischemia by cilostazol may decrease retinal neurodegeneration. Schmelzer et al. demonstrated that cilostazol had a direct effect on nerve blood flow, suggesting that improvement in endoneural perfusion may provide an alternative or additional mechanism for improving nerve electrophysiology (Kihara et al., 1995). Recent studies have demonstrated that cilostazol can reduce the degree of neuronal cell death after transient cerebral ischemia (Lee et al., 2006). With regard to retina, neuroprotective effect of cilostazol has been reported in an animal model of ischemia-reperfusion injury or optic nerve axotomy (Iwama et al., 2007; Kashimoto et al., 2008). However, there have been no studies concerning the effect of cilostazol on diabetic retina.

Given that diabetic patients have an increased risk for atherothrombotic events attributable in part to platelet dysfunction, increased platelet reactivity warrants the therapeutic use of platelet-inhibiting agents such as cilostazol to reduce ischemic risk (Ajjan and Grant, 2011; Angiolillo, 2009). Although initially used to improve claudication in patients with peripheral vascular disease, (Thompson et al., 2002) cilostazol has been suggested to be useful for the prevention of vascular complications in patients with diabetes mellitus (Suehiro A, 1993). Retinopathy is a uniquely specific and non-invasively assessable symptom of diabetic microvascular

JPET #203067

damage, and thus may serve as a novel biomarker of vascular disease risk in asymptomatic patients with diabetes. The existing literature supports the theory that DR reflects widespread microcirculatory disease in not only eyes but also vital organs elsewhere in the body (Hiller et al., 1988). Some studies have investigated the use of systemic therapies such as ruboxistaurin, which is a selective protein kinase C inhibitor, or pimagedine, which is an aminoguanidine that inhibits the formation of advanced glycation end products, to reduce progression of DR. However, their effectiveness has not been verified (Bolton et al., 2004; Davis et al., 2009).

In the current study we demonstrated that cilostazol may culminate in the protection of retinal ganglion cells by improving ischemia caused by diabetes, as reflected by a reduction in VEGF release. Indeed, current treatments for DR are mostly intended to block VEGF, by laser treatment, and by anti-VEGF drugs (Stewart, 2012). However, VEGF is a survival factor for retinal neurons which are vulnerable to ischemic insult (Nishijima et al., 2007). The fundamental effort to lower ischemia rather than blocking already released VEGF following ischemic damage could provide additional insight in terms of prevention and treatment of neurodegeneration and microvasculopathy of the retina.

JPET #203067

Acknowledgment

JPET #203067

Authorship Contribution

Participated in research design: C.K. Park

Conducted experiments: Kim

Contributed new reagents or analytic tools: Kim

Performed data analysis: Jung, C.K. Park, H.Y. Park

Wrote or contributed to the writing of the manuscript: Jung, C.K. Park

-References-

- Abu-El-Asrar AM, Dralands L, Missotten L, Al-Jadaan IA and Geboes K (2004) Expression of apoptosis markers in the retinas of human subjects with diabetes. *Investigative ophthalmology & visual science* **45**:2760-2766.
- Ahmed J, Braun RD, Dunn R, Jr. and Linsenmeier RA (1993) Oxygen distribution in the macaque retina. *Investigative ophthalmology & visual science* **34**:516-521.
- Aizu Y, Oyanagi K, Hu J and Nakagawa H (2002) Degeneration of retinal neuronal processes and pigment epithelium in the early stage of the streptozotocin-diabetic rats. *Neuropathology* **22**:161-170.
- Ajjan RA and Grant PJ (2011) The role of antiplatelets in hypertension and diabetes mellitus. *J Clin Hypertens (Greenwich)* **13**:305-313.
- Angiolillo DJ (2009) Antiplatelet therapy in diabetes: efficacy and limitations of current treatment strategies and future directions. *Diabetes care* **32**:531-540.
- Antonetti DA, Barber AJ, Bronson SK, Freeman WM, Gardner TW, Jefferson LS, Kester M, Kimball SR, Krady JK, LaNoue KF, Norbury CC, Quinn PG, Sandirasegarane L and Simpson IA (2006) Diabetic retinopathy: seeing beyond glucose-induced microvascular disease. *Diabetes* **55**:2401-2411.
- Antonetti DA, Klein R and Gardner TW (2012) Diabetic retinopathy. *N Engl J Med* **366**:1227-1239.
- Asnaghi V, Gerhardinger C, Hoehn T, Adeboje A and Lorenzi M (2003) A role for the polyol pathway in the early neuroretinal apoptosis and glial changes induced by diabetes in the rat. *Diabetes* **52**:506-511.
- Bai Y, Ma JX, Guo J, Wang J, Zhu M, Chen Y and Le YZ (2009) Muller cell-derived VEGF is a significant contributor to retinal neovascularization. *The Journal of pathology* **219**:446-454.

JPET #203067

- Barber AJ (2003) A new view of diabetic retinopathy: a neurodegenerative disease of the eye. *Prog Neuropsychopharmacol Biol Psychiatry* **27**:283-290.
- Barber AJ, Lieth E, Khin SA, Antonetti DA, Buchanan AG and Gardner TW (1998) Neural apoptosis in the retina during experimental and human diabetes. Early onset and effect of insulin. *The Journal of clinical investigation* **102**:783-791.
- Bolton WK, Cattran DC, Williams ME, Adler SG, Appel GB, Cartwright K, Foiles PG, Freedman BI, Raskin P, Ratner RE, Spinowitz BS, Whittier FC and Wuerth JP (2004) Randomized trial of an inhibitor of formation of advanced glycation end products in diabetic nephropathy. *American journal of nephrology* **24**:32-40.
- Chapman TM and Goa KL (2003) Cilostazol: a review of its use in intermittent claudication. *Am J Cardiovasc Drugs* **3**:117-138.
- Cheung N, Mitchell P and Wong TY (2010) Diabetic retinopathy. *Lancet* **376**:124-136.
- Cheung N and Wong TY (2008) Diabetic retinopathy and systemic vascular complications. *Progress in retinal and eye research* **27**:161-176.
- Davis MD, Sheetz MJ, Aiello LP, Milton RC, Danis RP, Zhi X, Girach A, Jimenez MC and Vignati L (2009) Effect of ruboxistaurin on the visual acuity decline associated with long-standing diabetic macular edema. *Investigative ophthalmology & visual science* **50**:1-4.
- Ferrara N (2004) Vascular endothelial growth factor: basic science and clinical progress. *Endocr Rev* **25**:581-611.
- Fong DS, Aiello L, Gardner TW, King GL, Blankenship G, Cavallerano JD, Ferris FL, 3rd and Klein R (2003) Diabetic retinopathy. *Diabetes care* **26**:226-229.
- Geng DF, Deng J, Jin DM, Wu W and Wang JF (2012) Effect of cilostazol on the progression of carotid intima-media thickness: a meta-analysis of randomized controlled trials. *Atherosclerosis* **220**:177-183.

JPET #203067

- Hillegass WB, Brott BC, Dobbs JC, Papapietro SE, Misra VK and Zoghbi GJ (2011) Oral antiplatelet therapy in diabetes mellitus and the role of prasugrel: an overview. *Vasc Health Risk Manag* **7**:445-459.
- Hiller R, Sperduto RD, Podgor MJ, Ferris FL, 3rd and Wilson PW (1988) Diabetic retinopathy and cardiovascular disease in type II diabetics. The Framingham Heart Study and the Framingham Eye Study. *American journal of epidemiology* **128**:402-409.
- Ikeda Y (1999) Antiplatelet therapy using cilostazol, a specific PDE3 inhibitor. *Thrombosis and haemostasis* **82**:435-438.
- Iwama D, Miyamoto K, Miyahara S, Tamura H, Tsujikawa A, Yamashiro K, Kiryu J and Yoshimura N (2007) Neuroprotective effect of cilostazol against retinal ischemic damage via inhibition of leukocyte-endothelial cell interactions. *J Thromb Haemost* **5**:818-825.
- Kashimoto R, Kurimoto T, Miyoshi T, Okamoto N, Tagami Y, Oono S, Ito Y and Mimura O (2008) Cilostazol promotes survival of axotomized retinal ganglion cells in adult rats. *Neuroscience letters* **436**:116-119.
- Katakami N, Kim YS, Kawamori R and Yamasaki Y (2010) The phosphodiesterase inhibitor cilostazol induces regression of carotid atherosclerosis in subjects with type 2 diabetes mellitus: principal results of the Diabetic Atherosclerosis Prevention by Cilostazol (DAPC) study: a randomized trial. *Circulation* **121**:2584-2591.
- Kihara M, Schmelzer JD and Low PA (1995) Effect of cilostazol on experimental diabetic neuropathy in the rat. *Diabetologia* **38**:914-918.
- Kwon SU, Cho YJ, Koo JS, Bae HJ, Lee YS, Hong KS, Lee JH and Kim JS (2005) Cilostazol prevents the progression of the symptomatic intracranial arterial

JPET #203067

stenosis: the multicenter double-blind placebo-controlled trial of cilostazol in symptomatic intracranial arterial stenosis. *Stroke* **36**:782-786.

Lee JH, Park SY, Shin YW, Hong KW, Kim CD, Sung SM, Kim KY and Lee WS (2006) Neuroprotection by cilostazol, a phosphodiesterase type 3 inhibitor, against apoptotic white matter changes in rat after chronic cerebral hypoperfusion. *Brain Res* **1082**:182-191.

Miller JW, Adamis AP and Aiello LP (1997) Vascular endothelial growth factor in ocular neovascularization and proliferative diabetic retinopathy. *Diabetes Metab Rev* **13**:37-50.

Mina A, Favaloro EJ and Koutts J (2007) Hemostatic dysfunction associated with endocrine disorders as a major risk factor and cause of human morbidity and mortality: a comprehensive meta-review. *Semin Thromb Hemost* **33**:798-809.

Natarajan A, Zaman AG and Marshall SM (2008) Platelet hyperactivity in type 2 diabetes: role of antiplatelet agents. *Diab Vasc Dis Res* **5**:138-144.

Nathan DM, Zinman B, Cleary PA, Backlund JY, Genuth S, Miller R and Orchard TJ (2009) Modern-day clinical course of type 1 diabetes mellitus after 30 years' duration: the diabetes control and complications trial/epidemiology of diabetes interventions and complications and Pittsburgh epidemiology of diabetes complications experience (1983-2005). *Archives of internal medicine* **169**:1307-1316.

Nishijima K, Ng YS, Zhong L, Bradley J, Schubert W, Jo N, Akita J, Samuelsson SJ, Robinson GS, Adamis AP and Shima DT (2007) Vascular endothelial growth factor-A is a survival factor for retinal neurons and a critical neuroprotectant during the adaptive response to ischemic injury. *The American journal of pathology* **171**:53-67.

- O'Callaghan JP (1991) Assessment of neurotoxicity: use of glial fibrillary acidic protein as a biomarker. *Biomed Environ Sci* **4**:197-206.
- Osborne NN and Larsen AK (1996) Antigens associated with specific retinal cells are affected by ischaemia caused by raised intraocular pressure: effect of glutamate antagonists. *Neurochemistry international* **29**:263-270.
- Pournaras CJ (1995) Retinal oxygen distribution. Its role in the physiopathology of vasoproliferative microangiopathies. *Retina* **15**:332-347.
- Schafer A and Bauersachs J (2008) Endothelial dysfunction, impaired endogenous platelet inhibition and platelet activation in diabetes and atherosclerosis. *Curr Vasc Pharmacol* **6**:52-60.
- Shindo H, Tawata M and Onaya T (1993) Cyclic adenosine 3',5'-monophosphate enhances sodium, potassium-adenosine triphosphatase activity in the sciatic nerve of streptozotocin-induced diabetic rats. *Endocrinology* **132**:510-516.
- Shiraishi Y, Kanmura Y and Itoh T (1998) Effect of cilostazol, a phosphodiesterase type III inhibitor, on histamine-induced increase in $[Ca^{2+}]_i$ and force in middle cerebral artery of the rabbit. *British journal of pharmacology* **123**:869-878.
- Sima AA, Zhang WX, Cherian PV and Chakrabarti S (1992) Impaired visual evoked potential and primary axonopathy of the optic nerve in the diabetic BB/W-rat. *Diabetologia* **35**:602-607.
- Simo R, Carrasco E, Garcia-Ramirez M and Hernandez C (2006) Angiogenic and antiangiogenic factors in proliferative diabetic retinopathy. *Curr Diabetes Rev* **2**:71-98.
- Stewart MW (2012) The expanding role of vascular endothelial growth factor inhibitors in ophthalmology. *Mayo Clinic proceedings Mayo Clinic* **87**:77-88.
- Suehiro A SY, Masuda H, Kakishita E (1993) A study of the effects of cilostazol on

JPET #203067

platelet function and serum lipids in patients with diabetes mellitus *Curr Ther Res* **54**:553-561.

Thompson PD, Zimet R, Forbes WP and Zhang P (2002) Meta-analysis of results from eight randomized, placebo-controlled trials on the effect of cilostazol on patients with intermittent claudication. *The American journal of cardiology* **90**:1314-1319.

Wang F, Li M, Cheng L, Zhang T, Hu J, Cao M, Zhao J, Guo R, Gao L and Zhang X (2008) Intervention with cilostazol attenuates renal inflammation in streptozotocin-induced diabetic rats. *Life sciences* **83**:828-835.

Wangsa-Wirawan ND and Linsenmeier RA (2003) Retinal oxygen: fundamental and clinical aspects. *Archives of ophthalmology* **121**:547-557.

Wesley MC, McGowan FX, Castro RA, Dissanayake S, Zurakowski D and Dinardo JA (2009) The effect of milrinone on platelet activation as determined by TEG platelet mapping. *Anesthesia and analgesia* **108**:1425-1429.

Zhang X, Bao S, Hambly BD and Gillies MC (2009) Vascular endothelial growth factor-A: a multifunctional molecular player in diabetic retinopathy. *The international journal of biochemistry & cell biology* **41**:2368-2371.

JPET #203067

-Footnotes-

This work was supported by the National Research Foundation of Korea (NRF) grant funded by the Korea government (Ministry of Education, Science and Technology) [No.20120001399]; and Otsuka Pharmaceutical Co. (Tokushima, Japan).

K.I.J. and J.H.K. contributed equally to this work.

-Figure legends-

Figure 1. Blood glucose level (mg/dL) during intraperitoneal glucose tolerance test in OLETF and LETO rats. Blood glucose levels were measured before glucose injection and at 30, 60, 90, and 120 min after glucose loading. At 25 and 40 weeks, glucose tolerance was reduced in OLETF compared with LETO rats ($p < 0.05$). Treatment with cilostazol did not reduce blood glucose levels in OLETF rats.

Figure 2. Effect of cilostazol on GFAP immunoreactivity in the control LETO and OLETF rats. Representative photomicrographs of vertical sections (A-D) and whole mount retinas (E-H) at 40 weeks of age. Whole mount retina photomicrographs are focused on the GCL. In LETO rats (A, C, E, G), GFAP immunoreactivity (red) was limited to astrocytes and the end feet of Müller cells regardless of cilostazol treatment. In OLETF rats, GFAP immunoreactivity was increased in OLETF rats compared with LETO rats and showed a ramified pattern (B, F). Cilostazol treatment in OLETF rats quantitatively reduced GFAP immunostaining and disrupted the ramified pattern (D, H) compared with the results in untreated OLETF rats (B, F).

GCL, ganglion cell layer; IPL, inner plexiform layer; INL, inner nuclear layer; OPL, outer plexiform layer; ONL, outer nuclear layer.

Bar=50 μ m

JPET #203067

Figure 3. Effects of cilostazol on VEGF expression in LETO and OLETF rats.

VEGF immunoreactivity was greater in OLETF rats than LETO rats at 40 weeks of age. In LETO rats, VEGF was located in the retinal ganglion cell layer, and inner plexiform layer with a scattered granular distribution. In OLETF rats, VEGF immunostaining was seen extensively throughout the retina from the ganglion cell layer to the outer plexiform layer. Co-localization with NeuN, an RGC marker, showed that VEGF immunoreactivity in the GCL was located in the cytoplasm of RGCs in LETO and OLETF rats. Cilostazol treatment reduced VEGF immunoreactivity in both LETO and OLETF rats, but the reduction was more remarkable in OLETF rats.

Bar=50 μ m

Figure 4. Effect of cilostazol treatment on GFAP and VEGF protein expression

Western blot analysis showed that the protein expression of both GFAP and VEGF was increased in the retinas of OLETF rats at 40 weeks of age, consistent with the immunofluorescence observations. Treatment with cilostazol decreased the protein expression of GFAP and VEGF in both OLETF and LETO rats, although the changes were more prominent in OLETF rats.

* A significant difference with $p < 0.05$ compared to LETO rats

† A significant difference with $p < 0.05$ compared to untreated OLETF rats

JPET #203067

Figure 5. Effects of cilostazol on apoptotic cell death in retinas of OLETF and

LETO rats. TUNEL and the nuclear marker DAPI staining were performed at 40 weeks of age. (A) In control LETO rats, TUNEL-positive cells (arrows, green) were rarely observed in the retinal layer. (B) In OLETF rats, several retinal cells, especially in the ganglion cell layer, were stained by TUNEL (arrows, green). (C,D) Cilostazol treatment reduced retinal cell apoptosis in OLETF rats.

GCL, ganglion cell layer; IPL, inner plexiform layer; INL, inner nuclear layer; LETO+P, LETO rats with cilostazol treatment; OLETF+P, OLETF rats with cilostazol treatment; OPL, outer plexiform layer; ONL, outer nuclear layer.

* A significant difference with $p < 0.05$ compared to LETO rats

† A significant difference with $p < 0.05$ compared to untreated OLETF rats

Bar=50 μ m

JPET #203067

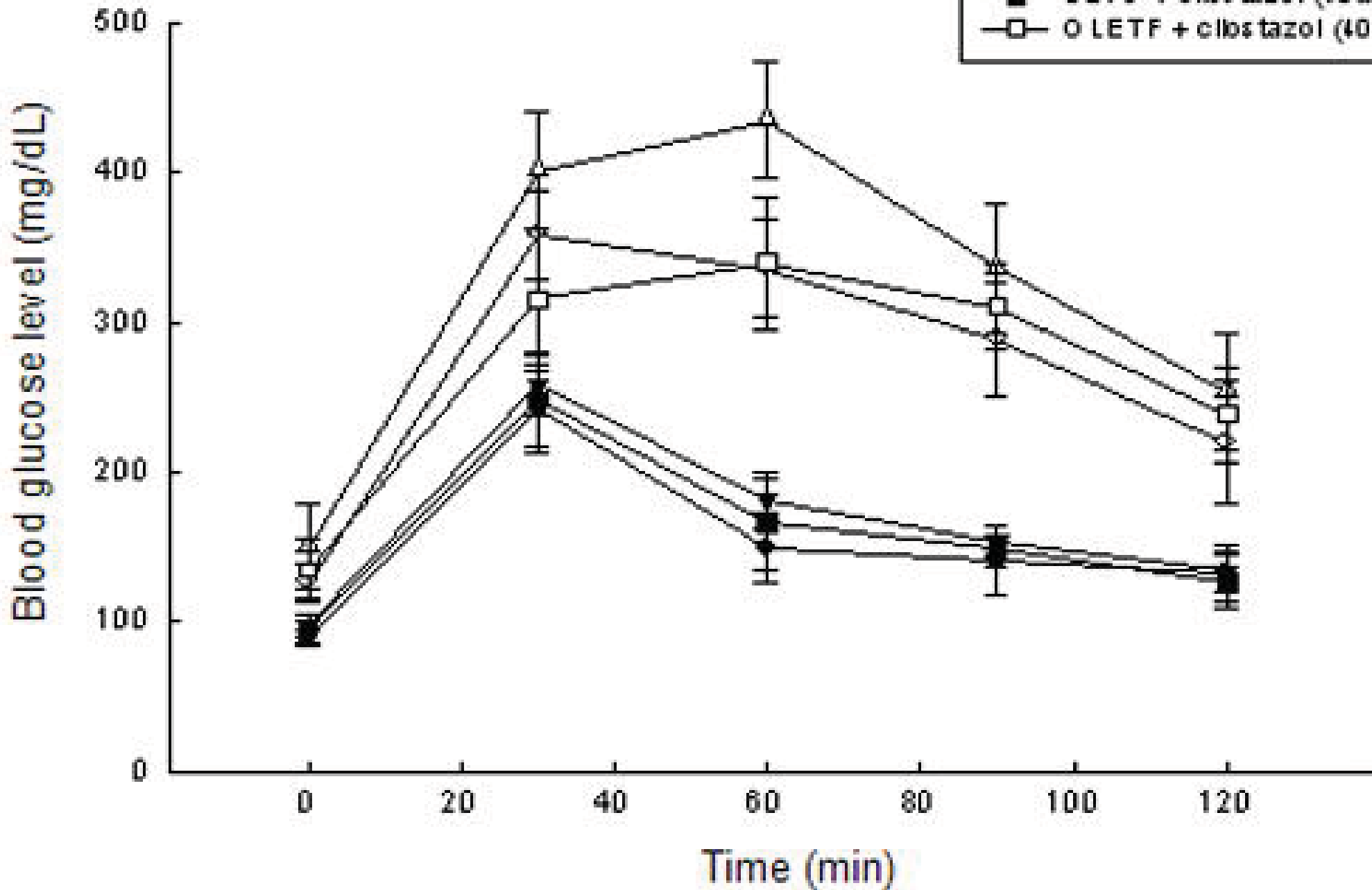
Table 1. Body weight of 20 and 40 week-old LETO and OLETF rats with and without cilostazol

	Treatment	LETO	OLETF
25 weeks old (g)	(-)	476.5±27.6	625.5±40.6*
40 weeks old(g)	(-)	551.7±24.7	658.1±33.7*
	cilostazol	547.7±34.7	612.1±39.5

Values are mean±SEM

* A significant difference with $p < 0.05$ compared with LETO rats of the corresponding age.

Figure 1



LETO

OLETF

Figure 2

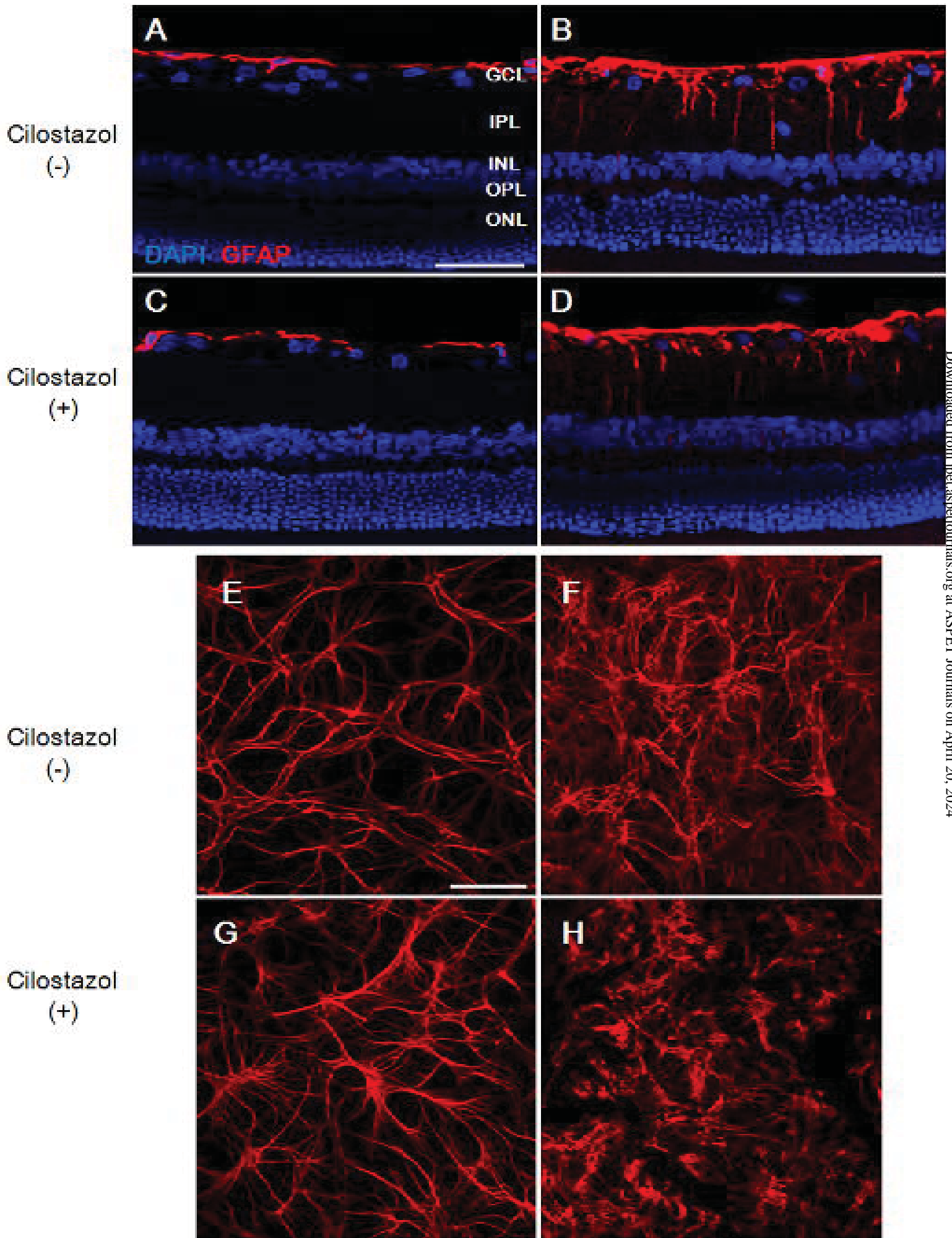


Figure 3

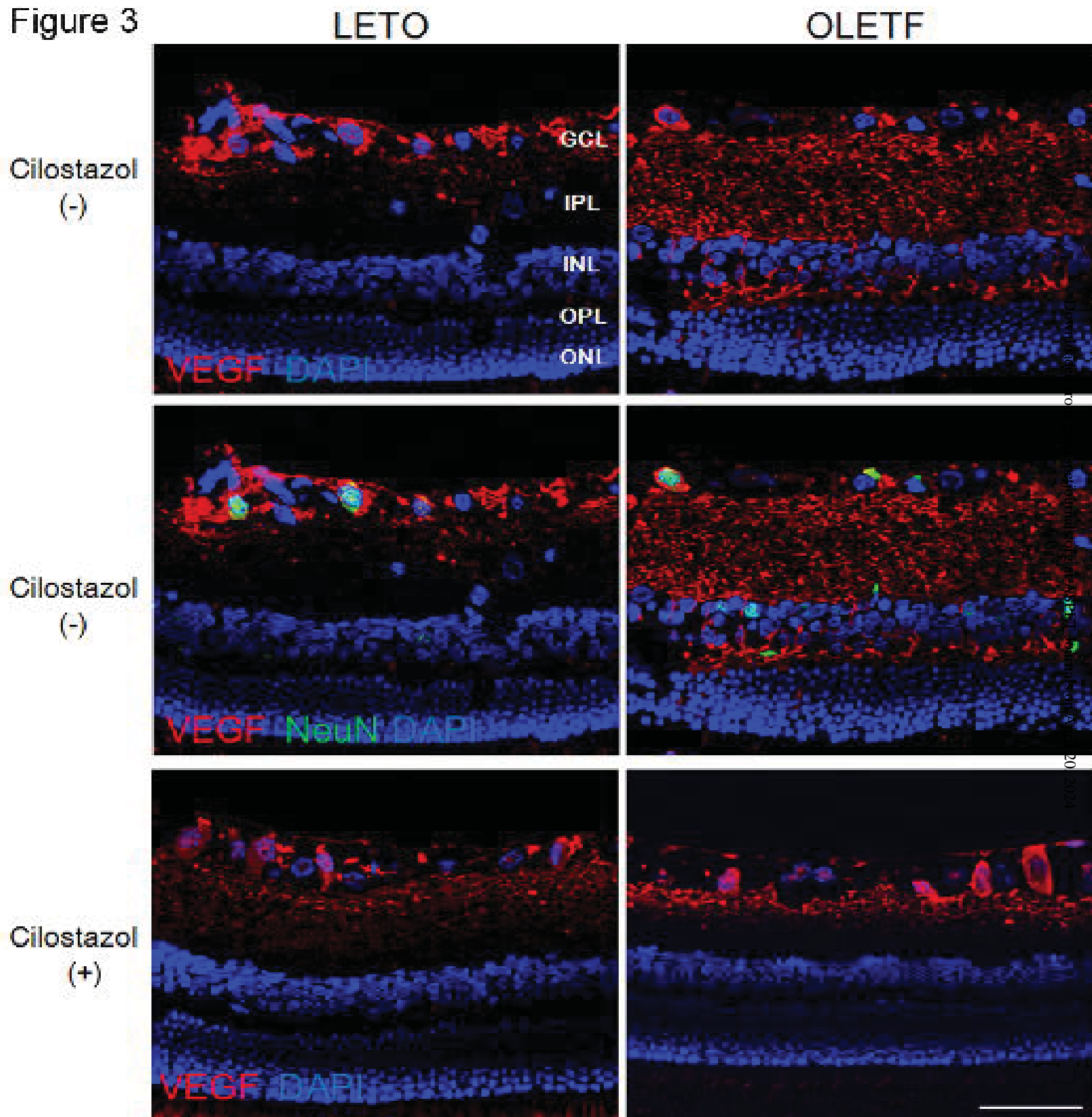


Figure 4

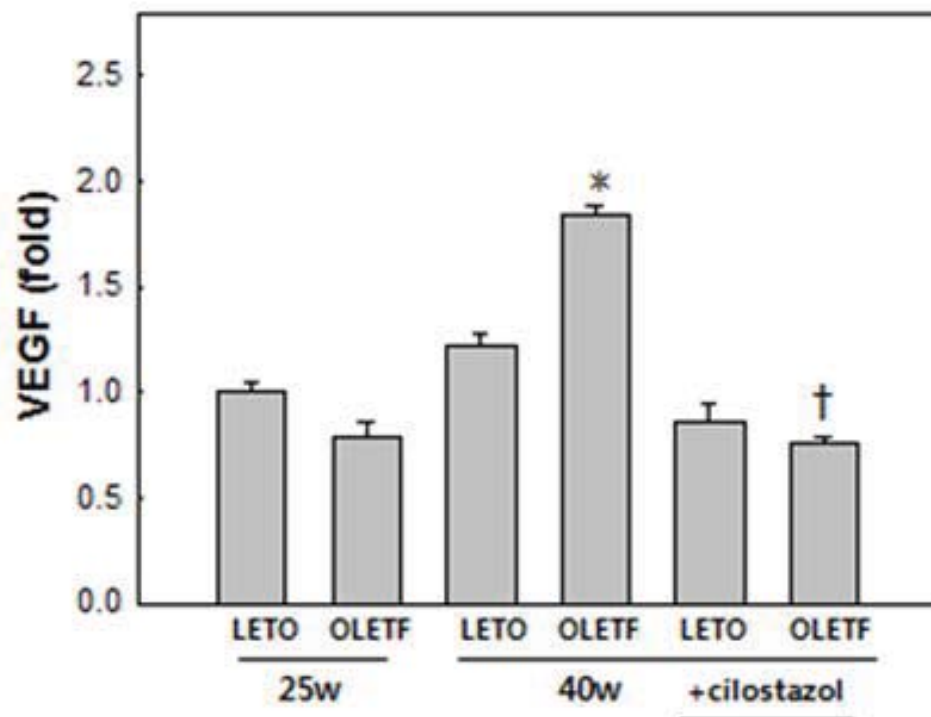
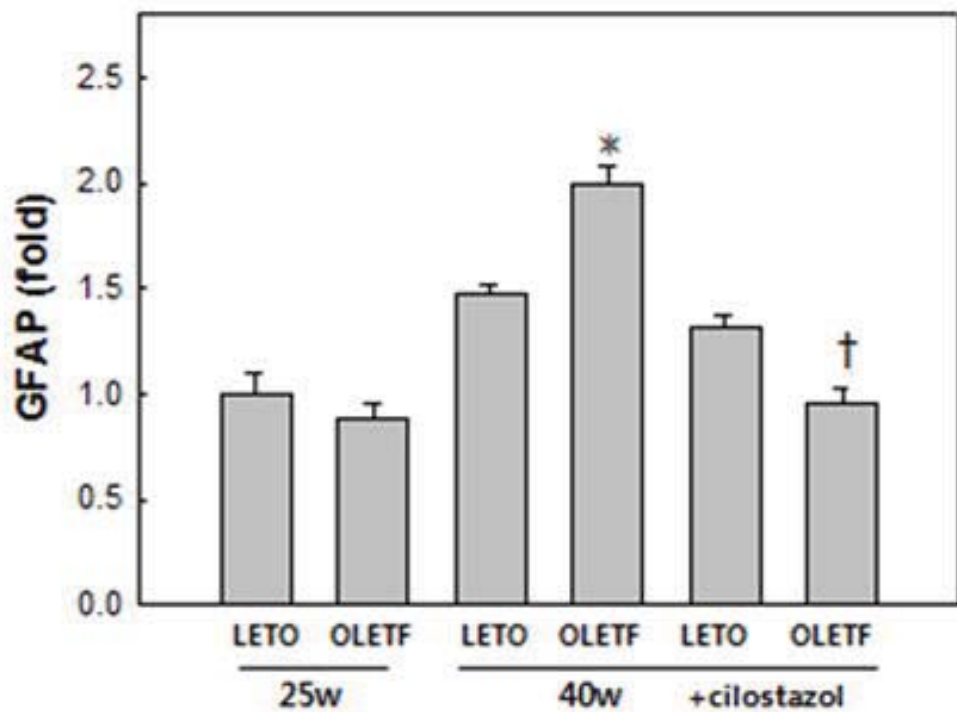
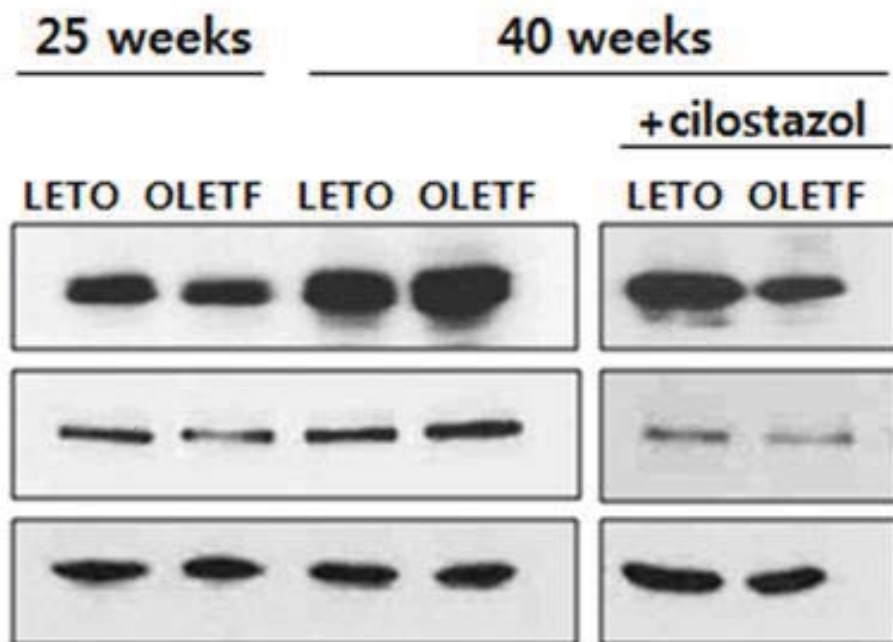
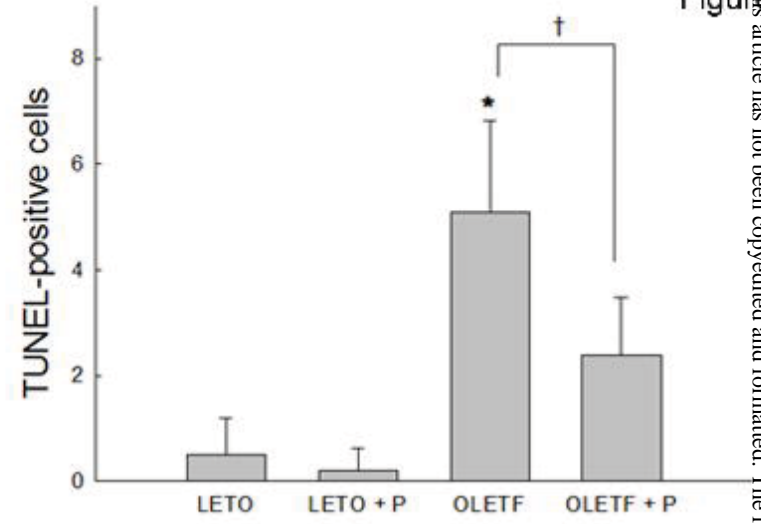


Figure 5



A; 40w LETO
B; 40w OLETF
C; 40w LETO + cilostazol
D; 40w OLETF + cilostazol

