

Title page

NSAID Activated Gene (NAG-1) plays a role in the impairing effects of cyclooxygenase inhibitors on gastric ulcer healing

Rocchina Colucci, Luca Antonioli, Nunzia Bernardini, Chiara Ippolito, Cristina Segnani, Oriana Awwad, Marco Tuccori, Corrado Blandizzi, Carmelo Scarpignato, Matteo Fornai

Interdepartmental Centre for Research in Clinical Pharmacology and Experimental Therapeutics, University of Pisa (R.C., L.A., O.A., M.T., C.B., M.F.); Department of Human Morphology and Applied Biology, University of Pisa (N.B., C.I., C.S.); Laboratory of Clinical Pharmacology, Division of Gastroenterology, Department of Clinical Sciences, University of Parma, Parma, Italy (C.S.)

Running title page

Running title: NSAID-activated gene and gastric ulcer healing

Author for correspondence:

Prof. Corrado Blandizzi, MD

Interdepartmental Centre for Research in Clinical Pharmacology

and Experimental Therapeutics, University of Pisa

Via Roma 55, 56126, Pisa, Italy

Phone: +39-050-2218754

Fax: +39-050-2218758

Email: c.blandizzi@virgilio.it

Number of text pages: 38

Number of tables: 2

Number of figures: 7

Number of references: 35

Number of the words in the Abstract: 249

Number of the words in the Introduction: 684

Number of the words in the Discussion: 1342

Abbreviations: COX, cyclooxygenase; DAB, 3,3'-diaminobenzidine tetrahydrochloride; DFU, (5-dimethyl-3-(3-fluorophenyl)-4-(4-methylsulfonyl) phenyl-2(5H)-furanone; L-745, 337, N-[6-[(2,4-Difluorophenyl)thio]-2,3-dihydro-1-oxo-1H-inden-5-yl]methanesulfonamide; NAG-1, NSAID activated gene-1; NSAIDs, nonsteroidal anti-inflammatory drugs; NS-398, N-[2-(cyclohexyloxy)-4-nitrophenyl]-methanesulfonamide; PCNA, proliferating cell nuclear antigen; PGE₂, prostaglandin E₂; RT-PCR, reverse transcription-polymerase chain reaction; SC-560, (5-(4-chlorophenyl)-1-(4-methoxyphenyl)-3-trifluoromethylpyrazole.

Section assignment: Gastrointestinal, Hepatic, Pulmonary, and Renal

Abstract

Non-steroidal anti-inflammatory drugs (NSAIDs) can impair gastric ulcer healing. This study investigates the involvement of NSAID-activated gene-1 (NAG-1) in ulcer repair impairment by cyclooxygenase (COX) inhibitors. Gastric ulcers were induced in rats by acetic acid. Four days later, animals received daily intragastric indomethacin (non-selective COX-1/COX-2 inhibitor, 1 mg/kg), SC-560 (selective COX-1 inhibitor, 2.5 mg/kg), DFU (selective COX-2 inhibitor, 5 mg/kg), celecoxib (selective COX-2 inhibitor, 1 mg/kg) and valdecoxib (selective COX-2 inhibitor, 1 mg/kg), for 1, 3 or 7 days. Ulcerated tissues were processed to assess: 1) COX-1, COX-2, NAG-1, proliferating cell nuclear antigen (PCNA) and activated caspase-3 expression; 2) ulcer area; 3) prostaglandin E₂. COX-1 expression in ulcerated tissues was decreased, while COX-2 expression was enhanced. Ulcer healing was delayed by indomethacin, DFU and SC-560, but not by celecoxib and valdecoxib. Ulcer PGE₂ levels were decreased by SC-560, DFU, celecoxib, valdecoxib and indomethacin. NAG-1 was over-expressed in ulcerated tissues, and further enhanced by indomethacin, DFU and SC-560, but not by celecoxib or valdecoxib. PCNA expression in ulcerated areas was reduced by indomethacin, but not by other test drugs. The expression of activated caspase-3 in ulcers was increased, and enhanced further by indomethacin, DFU or SC-560, but not by celecoxib or valdecoxib. These findings indicate that: 1) COX inhibitors exert differential impairing effects on gastric ulcer healing, through mechanisms unrelated to the inhibition of COX isoforms and prostaglandin production; 2) NAG-1 induction, followed by activation of proapoptotic pathways, can contribute to the impairing effects of COX inhibitors on ulcer healing.

Introduction

Peptic ulcer is a tissue defect in the gastric or duodenal wall, which results from a necrotizing event and extends through the *muscularis mucosae* into the deeper layers. It is within these layers that the ulcerative process may erode a major blood vessel to elicit important bleeding (Yeomans and Naesdal, 2008). The main cause of peptic ulcer is represented by *H. pylori* infection, even though other factors are involved in its pathophysiology, including nonsteroidal anti-inflammatory drugs (NSAIDs) (Yeomans, 2011). Gastric acid secretion plays a pivotal role in the pathogenesis of peptic ulcer, and therefore ulcer therapy, besides *H. pylori* eradication, focuses also on the inhibition of acid secretion (Yuan et al., 2006).

The clinical use of NSAIDs is associated with the occurrence of adverse effects in the upper digestive tract, such as gastric erosions, ulceration, bleeding and perforation (Lanas et al., 2006; Scarpignato and Hunt, 2010). It is widely recognized that the detrimental effects exerted by NSAIDs on gastroduodenal mucosa depend on the blockade of cyclooxygenase (COX) isoenzymes (COX-1, COX-2) and subsequent decrease in mucosal prostaglandin production (Musumba et al., 2009). However, there is increasing evidence to suggest that COX-independent topical mechanisms, such as the destruction of surface hydrophobic barrier and ion trapping followed by mitochondrial dysfunction, contribute also to the pathogenesis of gastric injury associated with NSAIDs (Lichtenberger, 2001; Scarpignato and Hunt, 2010).

NSAIDs are also able to impair the healing of pre-existing gastric ulcers (Halter et al., 2001; Ma et al., 2002; Schmassmann et al., 2006; Colucci et al., 2009), and here again both COX-dependent and COX-independent mechanisms appear to come into play. Current evidence suggests that NSAIDs exert their impairing effects on ulcer healing through the inhibition of COX isoforms. In particular, the inhibiting actions of NSAIDs on ulcer healing can be mimicked by COX-2 selective inhibitors (Ma et al., 2002; Schmassmann et al., 2006),

thus supporting a significant involvement of COX-2 in ulcer repair. However, COX-1 could also play relevant roles, since the combined administration of selective COX-1 and COX-2 inhibitors was found to impair ulcer healing to a higher extent than selective COX-2 inhibitors alone (Schmassmann et al., 2006). Moreover, data regarding the expression of COX-1 and COX-2 in gastric ulcer are conflicting. Indeed, Jackson et al. (2000) found an increased COX-2 immunostaining in macrophages, endothelial cells, and myofibroblasts, with reduced epithelial expression at the ulcer edge, while COX-1 expression did not vary significantly in comparison with normal mucosa. By contrast, To et al. (2001) observed that, at the ulcer edge, COX-1 expression was increased in cells of the lamina propria, while COX-2 was strongly expressed in the hyperplastic foveolar epithelium, and that, in the granulation tissue of the ulcer base, there was a strong expression of COX-1 and COX-2 in myofibroblasts, macrophages and endothelial cells. There is also evidence that COX-independent mechanisms could contribute to the impairing effects of NSAIDs on ulcer healing. For instance, the impairment of ulcer healing caused by COX-2 inhibitors endowed with N-substituted methansulphonamide structure, such as NS-398 or L-745,337, was no longer observed with selective COX-2 blockers belonging to the 2,6-di-tert-butylphenol class, suggesting a molecule-dependent effect rather than a COX-dependent class effect (Lesch et al., 1998).

Studies on COX/prostaglandin-independent mechanisms activated by NSAIDs or selective COX-2 inhibitors have shown that several NSAIDs are able to modulate the expression of a target gene, designated as NSAID-activated gene-1 (NAG-1). This gene belongs to the family of transforming growth factor- β , and is able to induce apoptotic cell death (Kim et al., 2002). In particular, NAG-1 induction, elicited by COX inhibitors, has been found to interfere with cancer cell growth, either by activation of apoptosis or inhibition of proliferation mechanisms (Bottone et al., 2004).

Based on the above considerations, a relevant question is whether the impairing effects of NSAIDs on ulcer healing could be related with the activation of NAG-1. Accordingly, the present study has been performed to examine the effects of different COX inhibitors, with different patterns of COX-1/COX-2 selectivity, on the healing of experimental gastric ulcers, as well as to evaluate the involvement of NAG-1 in the alterations of ulcer repair associated with test drugs.

Methods

Animals and experimental design

Albino male Sprague-Dawley rats (200-250 g body weight) were used throughout the study. They were housed in temperature-controlled rooms in a 12-h light/dark cycle at 22-24°C and 50 to 60% humidity. Their care and handling were in accordance with the provisions of the European Union Council Directive 86/609, recognized, and adopted by the Italian Government.

Single chronic ulcers were induced by subserosal injection of acetic acid in the corpus of the stomach, as described below. Four days after ulcer induction, the animals were given daily intragastric indomethacin (2-{1-[(4-chlorophenyl)carbonyl]-5-methoxy-2-methyl-1H-indol-3-yl}acetic acid, non-selective COX-1/COX-2 inhibitor, 1 mg/kg/day), SC-560 (5-(4-chlorophenyl)-1-(4-methoxyphenyl)-3-trifluoromethylpyrazole, selective COX-1 inhibitor, 2.5 mg/kg/day), DFU (5-dimethyl-3-(3-fluorophenyl)-4-(4-methylsulfonyl) phenyl-2(5H)-furanone, methylsulfonic, selective COX-2 inhibitor, 5 mg/kg/day), celecoxib (4-[5-(4-methylphenyl)-3-(trifluoromethyl) pyrazol-1-yl]benzenesulfonamide, sulfonamidic, selective COX-2 inhibitor, 1 mg/kg/day), or valdecoxib (4-(5-methyl-3-phenylisoxazol-4-yl) benzenesulfonamide, sulfonamidic selective COX-2 inhibitor, 1 mg/kg/day). Sham ulcerated animals treated with drug vehicle were used as controls. The doses of test drugs were selected by means of preliminary *in vivo* experiments on the rat air pouch model of inflammation (Gierse et al., 2005), as reported below. At day 1, 3 or 7 from starting drug administration (i.e., 5, 7 and 11 days from ulcer induction, respectively), the stomachs were rapidly removed and their ulcerated areas were collected by cutting the tissue along the external edge of ulcer margin. Thus, each specimen consisted of a round whole thickness gastric tissue, which included the ulcer bed, the margin and a small amount of the surrounding macroscopically normal mucosa. Histological assessments revealed that, for each specimen, the amount of

normal tissue surrounding the ulcer margin did not exceed 10% of the whole specimen. The gastric specimens were processed for the assessment of the following parameters: (1) measurement of ulcer area; (2) assay of prostaglandin E₂ (PGE₂) levels; (3) immunohistochemical analysis of COX-1, COX-2, NAG-1 and cleaved (i.e., activated) caspase-3; (4) RT-PCR analysis of NAG-1 mRNA expression; (5) western blot analysis of COX-1, COX-2, NAG-1, cleaved caspase-3 and PCNA. The experimental design is summarized in Fig. 1. The experimental protocol was approved by the ethics committee for animal experimentation of our University.

Rat air pouch model of inflammation

Test drugs were assayed on the *in vivo* rat air pouch model of inflammation, as previously described by Gierse et al. (2005), in order to select appropriate doses endowed with a potent and selective profile of inhibition on COX-1 and/or COX-2. Air pouches were produced by subcutaneous injection of 20-ml sterile air into the intrascapular area of the back of male Sprague-Dawley rats (200-250 g, n=6 for each group). Pouches were allowed to develop for 1 day, during which animals were fasted with free access to water. COX inhibitors or vehicle were administered by intragastric route 2 h prior to injection of 2 ml of a 1% suspension of carrageenan dissolved in saline into the pouch. Three hours after carrageenan injection, the pouch fluid was collected by lavage with 1 ml of cold heparin saline. The fluid was centrifuged at 800 g for 10 min at 4°C, and the supernatants were collected for analysis of PGE₂ by ELISA kit. At the end of the 3-h post-carrageenan injection, stomachs were dissected, immediately frozen in liquid nitrogen, and stored at -80°C for subsequent prostaglandin E₂ assay. The levels of PGE₂ in the gastric mucosa were taken as an index of COX-1 activity, while those in the air pouch were considered as mirroring COX-2

activity (Gierse et al., 2005). The results were expressed as percentage of inhibition of PGE₂ production vs control levels detected in animals treated with drug vehicle.

Induction of gastric ulcer by acetic acid

Gastric ulcers were induced as reported by Shigeta et al. (1998). Rats were anaesthetised with chloral hydrate (300 mg/kg), and laparotomy was performed via a midline incision. After exposing the stomach, 40 µl of 20% acetic acid solution were injected into the subserosal layer of the border between antrum and fundus on the anterior wall of the stomach, and the abdomen was then closed by suturing. Sham ulcerated rats were subjected to laparotomy without acetic acid injection. Four days after the induction of gastric ulcers, treatments with test drugs or their vehicles were started and repeated every 24 h for 1, 3 or 7 days. At these times, the animals were sacrificed, and the stomachs were rapidly removed and processed for subsequent assays.

The measurement of ulcer area in stomachs excised from animals with acetic-acid-induced damage was performed as previously described by Shigeta et al. (1998). Briefly, the stomachs were rapidly removed, opened along the greater curvature and pinned upon a cork plate. Ulcer area (square millimeter) was then measured under a dissecting microscope provided with a millimetric grid by an operator who was unaware of treatments given to animals.

Immunohistochemical analysis of COX-1, COX-2, NAG-1 and cleaved caspase-3

Specimens of gastric tissue, fixed in cold 4% neutral formalin diluted in phosphate-buffered saline (PBS), were dehydrated with ethanol, treated with xylene, and embedded in paraffin at 56°C. Serial sections (5 µm thick) were processed for immunostaining. Slides were treated with 1% hydrogen peroxide in methanol, microwaved in citrate buffer, and blocked

with normal swine serum (1:20; Dakopatts, Glostrup, Denmark). Sections were then incubated overnight at 4°C with the following primary antibodies: mouse anti-COX-1 and rabbit anti-COX-2 (1:150 and 1:100, respectively), rabbit anti-NAG-1 (1:4000), rabbit anti-cleaved caspase-3 (1:75). Immunoglobulins were diluted in PBS with 0.1% bovine serum albumin and 0.1% sodium azide. Sections were washed with PBS and incubated with biotinylated immunoglobulins followed by peroxidase-labeled streptavidin complex and 3,3'-diaminobenzidine tetrahydrochloride (DAB; Dakopatts) (Fornai et al., 2006). Sections were counterstained with hematoxylin. All reactions were carried out at room temperature in a humidified chamber, and PBS was used for washes, unless otherwise specified. Specificity of immunopositive staining was assessed by preadsorbing primary antibodies with the respective blocking peptides at 10 times the antibody concentrations for 24 h at 4°C: COX-1 and COX-2 (code no. CAY 360109; and CAY 360107; Cayman Chemical Company, respectively), cleaved caspase-3 (Asp175) (code no. 1050, Cell Signalling Technologies, Boston, MA, USA). Negative controls were obtained by substitution of the primary antibody with preimmune rabbit serum. Endogenous peroxidases and avidin-binding activity were assayed by incubating slides with DAB alone or with peroxidase-labeled streptavidin complex/DAB, respectively. Staining intensity for NAG-1 and cleaved caspase-3 was evaluated by a semi-quantitative method, according to which the immunoreactivity was graded as +++ when strongly positive, ++ when positive, + when moderately positive, +/- when weakly positive, and 0 when negative. This evaluation was carried out by three independent observers for each selected gastric section.

PGE₂ assay

Enzyme immunoassay of PGE₂ in the gastric mucosa was performed using a commercial kit, as previously described (Colucci et al., 2009). Briefly, specimens of gastric

mucosa were weighed, minced by forceps, and homogenized in 1 ml of cold phosphate buffer (PBS 0.1 M, pH 7.4, containing 1 mM EDTA and 10 μ M indomethacin) per gram of tissue using a polytron homogenizer (QIAGEN, Milan, Italy). The resulting homogenate was added to an equal volume of absolute ethanol, and stirred by vortex. After 5-min incubation at room temperature, the homogenate was centrifuged at 1500 \times g for 10 min at 4°C. The supernatant was added with 1 N HCl until pH 4 was reached. Before performing the assay, samples were subjected to purification using superclean LC-18 SPE columns (Sigma Co., St. Louis, MO, USA). For this purpose, 0.5 ml of sample were added to 2 ml of ethanol and vortexed. After incubation at room temperature for 5 min, the sample was centrifuged at 3000 \times g for 10 min. The supernatant was then removed and applied to LC-18 SPE column, previously activated with 5 ml of methanol followed by 5 ml of ultrapure water. The column was then washed with 5 ml of ultrapure water and 5 ml of hexane. PGE₂ was eluted with 5 ml of ethylacetate containing 1% methanol. The eluted ethylacetate fractions were collected and evaporated to dryness under nitrogen. Aliquots were used for subsequent enzyme immunoassay (Cayman Chemical Company, Ann Arbor, MI, U.S.A.). The results were expressed as pg of PGE₂ per mg of wet tissue. The analysis of PGE₂ in lavage fluid of air pouches was performed directly on the supernatant, obtained as reported above.

Western blot assay of COX-1, COX-2, NAG-1, cleaved caspase-3 and PCNA

Whole-thickness specimens of gastric ulcerated tissues, excised as reported above, were weighed and homogenized in lysis buffer containing: HEPES 10 mmol/L, NaCl 30 mmol/L, EDTA 0.2 mmol/L, phenylmethylsulfonylfluoride 2 mmol/L, leupeptin 10 μ g/mL, aprotinin 10 μ g/mL, sodium fluoride 1 mmol/L, sodium orthovanadate 1 mmol/L, glycerol 2%, MgCl₂ 0.3 mmol/L and Triton-X 100 1%, using a polytron homogenizer (QIAGEN, Milan, Italy). Homogenates were spun by centrifugation at 15,000 \times g for 15 min at 4°C, and

the resulting supernatants were then separated from pellets and stored at -80°C . Protein concentration in each sample was determined by the Bradford method (Protein Assay Kit, Bio-Rad, Hercules, CA, USA). Thirty micrograms of total lysates were denatured by boiling, separated on a SDS-PAGE (12%) and then transferred onto Immobilon-P membrane. Blots were blocked and then probed with primary antibodies raised against rat COX-1, COX-2, NAG-1, uncleaved and cleaved caspase-3, proliferating cell nuclear antigen (PCNA) and β -actin, and detected by means of horseradish peroxidase conjugated secondary antibody. Immunoreactive bands were visualized by incubation with chemiluminescent reagents and exposed to Kodak Image Station 440 for signal detection and densitometric image analysis.

Reverse transcription polymerase chain reaction of NAG-1 mRNA

Expression of mRNA coding for NAG-1 was assessed by RT-PCR. At the time of extraction, samples of ulcerated gastric tissue, excised as reported above, were disrupted with cold glass pestles, and total RNA was isolated by TRIZOL (Life Technologies, Carlsbad, CA) and chloroform. Total RNA (1 μg) served as template for cDNA synthesis in a reaction using 2 μl of random hexamers (0.5 $\mu\text{g}/\mu\text{l}$) with 200 U of Moloney murine leukemia virus-reverse transcriptase in a buffer containing 500 μM deoxynucleoside-5'-triphosphate (dNTP) and 10 mM dithiothreitol. cDNA samples were subjected to PCR in the presence of primers based on cloned rat NAG-1 (sense primer 5'-CCCAGCTGTCCGGATACTC-3'; antisense primer 5'-ATCATAAGTCTGCAGTGACA-3') (Böttner et al., 1999) and β -actin (sense primer 5'-TCATGAAGTGTGACGTTGACATCCGT-3'; antisense primer 5'-CTTAGAAGCATTGCGGTGCACGATG-3') (Fornai et al., 2006). PCR, consisting of 2 μl of RT products, 2.5 U of Taq polymerase, 100 μM dNTP, and 0.5 μM primers, was carried out by a PCR thermocycler DNA Engine (Biorad, Hercules, CA, U.S.A.). After 3 min at 94°C , the cycle conditions were 1 min at 94°C , 1 min at 57°C , and 1 min at 72°C for 35 cycles,

followed by 7 min at 72°C. Aliquots of RNA not subjected to RT were included in PCR reactions to verify the absence of genomic DNA. The efficiency of RNA extraction, RT, and PCR was evaluated by primers for rat β -actin. PCR products (630 bp for NAG-1 and 286 pb for β -actin) were separated by 1.5% agarose gel electrophoresis in a Tris buffer (40 mM) containing 2 mM EDTA, 20 mM acetic acid (pH 8), and stained with ethidium bromide. PCR products were then visualized by UV light and subjected to densitometric analysis by Kodak Image Station program (Eastman Kodak Co., Rochester, NY). The relative expression of target mRNA was normalized to that of β -actin.

Drugs and reagents

The following drugs, antibodies and reagents were used: indomethacin, acetic acid, phenylmethylsulfonyl fluoride, leupeptin, aprotinin, sodium orthovanadate, mouse anti- β -actin antibody (code no. A5441, clone AC-15, 1:5000, Sigma Chemicals, St. Louis, MO, USA); SC-560, valdecoxib (Tocris, Bristol, U.K.); DFU (5-dimethyl-3-(3-fluorophenyl)-4-(4-methylsulfonyl) phenyl-2(5H)-furanone, Merck Research Laboratories, Rahway, NJ); celecoxib (kindly provided by Pfizer, Rome, Italy); mouse anti-COX-1 and rabbit anti-COX-2 (code no. CAY 160110 and code no. CAY 160126, respectively; Cayman Chemical Company, Ann Arbor, MI), rabbit anti-PCNA and HRP secondary antibody (Santa Cruz Biotechnology, Santa Cruz, CA, USA) and rabbit anti-caspase-3 antibody (code no. 9664, Cell Signalling Technologies, Boston, MA, USA); rabbit anti-NAG-1 (code no. 07-217, Millipore, Vimodrone, MI, Italy). Other reagents were of analytical grade. Indomethacin, SC-560, DFU, celecoxib, and valdecoxib were suspended in 1% methocel and administered in a volume of 0.5 mL per rat.

Statistical analysis

The results are presented as mean±standard error of the mean (S.E.M.) of values obtained from 6 to 8 animals. The statistical significance of data was evaluated by one way analysis of variance (ANOVA) followed by post hoc analysis by Student–Newman–Keuls test, and P values lower than 0.05 were considered significant. All statistical procedures were performed using GraphPad Prism 3.0 software (GraphPad, San Diego, CA, USA).

Results

Assessment of COX inhibition in the air pouch model of inflammation

The evaluation of PGE₂ levels in the gastric mucosa and air pouch provided a quantitative assessment of the specificity of COX isoform blockade by test drugs *in vivo* (Gierse et al., 2005). Indomethacin dose-dependently decreased PGE₂ levels both in the gastric tissue and air pouch, with a maximal effect observed at 1 mg/kg. The degree of inhibition was similar for both COX isoforms (Table 1). The dose of 1 mg/kg/day has been previously shown to elicit a significant delay of gastric ulcer healing in rats, without any relevant influence on animal mortality (Schmassmann et al. 1998; Shigeta et al. 1998). Therefore, the dose of 1 mg/kg/day was selected for subsequent experiments with indomethacin in the present study.

With regard to selective COX-1 or COX-2 inhibitors, treatment of animals with SC-560 resulted in a reduction of gastric PGE₂ production, while air pouch levels were scarcely affected. A potent and selective blockade of COX-1 isoform was observed at 2.5 mg/kg (Table 1). Treatment with DFU, celecoxib or valdecoxib evoked a significant reduction of air pouch PGE₂ levels in a dose-dependent fashion, while the PGE₂ production in gastric tissue was only slightly decreased. A potent and selective inhibition of COX-2-derived PGE₂ was observed at 5, 1, and 1 mg/kg, for DFU, celecoxib and valdecoxib, respectively (Table 1). Overall, the doses of test drugs, which produced potent and selective inhibition of COX isoforms, were 2.5 mg/kg for SC-560, 5 mg/kg for DFU, and 1 mg/kg for celecoxib and valdecoxib. The doses of SC-560, DFU and celecoxib were similar to those previously employed for the evaluation of the effects of COX blockade on gastric ulcer healing in rats (Gretzer et al., 2001; Berenguer et al., 2002; Hatazawa et al., 2007), while the dose of valdecoxib has been shown to produce a selective COX-2 inhibition in rat (Gierse et al., 2005;

Ahmad et al., 2009). For these reasons, the above doses were used in our subsequent experimental procedures.

Western blot analysis of COX-1 and COX-2

In gastric samples obtained from sham ulcerated rats, western blot analysis revealed the expression of both COX-1 and COX-2 protein (Figure 2A). This expression pattern was similar to that observed in the stomach of intact rats (not shown). After 1 day from starting drug vehicle administration, the expression of COX-1 in ulcerated tissue decreased, while COX-2 expression was increased (Figure 2A).

Immunohistochemical analysis of COX-1 and COX-2

After 1, 3 or 7 days from the onset of drug vehicle administration (i.e., 5, 7, 11 days from surgery), sham ulcerated rats showed a morphologically normal gastric wall with considerable expression of COX-1 in the mucosal layer, particularly within epithelial cells of the neck and bottom region of fundic glands. The surface mucus-producing epithelium and muscularis propria were negative for COX-1 (Figure 2B, 3A). In control ulcerated rats, treated with drug vehicle for 1 day, the gastric wall showed a clear mucosal/submucosal necrotic damage: polymorphonuclear exudates were evident at the ulcer base, and inflammatory infiltrates occurred within the lamina propria and submucosa of ulcer margins. COX-1 immunostaining was significantly reduced at both the ulcer margin and bed, and such a pattern was maintained throughout the study period, although a partial recovery was detected at the ulcer margin on day 3 and 7. A strong COX-1 expression was appreciable in most of the epithelial glandular cells just around the ulcer margins (Figure 3A). With regard for COX-2 immunoreactivity, low amount of constitutive COX-2 was observed in the gastric mucosal layer of sham ulcerated rats at day 1, 3 or 7 from the onset of drug vehicle

administration. In particular, COX-2 expression was detected in epithelial cells at the gland bottom and in stromal cells surrounding the gland (Figure 2B, 3B). In the gastric wall of control ulcerated rats, treated with drug vehicle for 1 day, the pattern of COX-2 expression was markedly enhanced: the ulcer margin and surrounding mucosa displayed increased COX-2 immunostaining at level of the epithelial glandular and stromal cells (Figure 3B). COX-2 was also strongly expressed in the granulation tissue beneath the ulcer bed, particularly in stromal, spindle-shaped cells displaying the morphological features of fibroblasts/myofibroblasts, as appreciable at higher magnification. At day 3 and 7 from the onset of drug vehicle administration, the pattern of COX-2 expression was progressively reduced along the ulcer margin, although COX-2-immunostained spindle-shaped cells remained evident at the ulcer bed (Figure 3B).

Gastric ulcer healing

The injection of acetic acid in the subserosal layer of gastric wall caused the development of single macroscopic ulcers, which were evident after 5, 7 and 11 days (i.e., 1, 3 and 7 days from the onset of drug treatment). In control animals, the ulcer area, evaluated at day 1, 3 or 7 of drug vehicle administration, accounted for 59.3 ± 4.3 , 57.4 ± 3.8 , and 20.2 ± 2.9 mm², respectively (Figure 4A). At day 1 of drug administration, none of the COX inhibitors was able to significantly affect the ulcer area, as compared with vehicle-treated control animals (Figure 4A). At day 3 of drug treatment, the ulcer area was significantly higher in animals receiving indomethacin (1 mg/kg/day) or DFU (5 mg/kg/day), while celecoxib (1 mg/kg/day), valdecoxib (1 mg/kg/day) or SC-560 (2.5 mg/kg/day) where without effects (Figure 4A). Treatment of ulcerated rats with indomethacin, DFU or SC-560 for 7 days was associated with a significant delay in gastric ulcer healing, while celecoxib and valdecoxib did not produce any significant effect (Figure 4A).

Assay of PGE₂

Gastric tissue PGE₂ levels in sham ulcerated animals amounted to 547±28.7 pg/mg tissue. This value did not differ significantly from that obtained for the stomach of intact animals (524±21.3 pg/mg tissue). In ulcerated gastric tissues from control rats treated with drug vehicle for 1 day, PGE₂ concentration was significantly increased (746±35.8 pg/mg tissue) (Figure 4B). At this time point, the administration of all test drugs was associated with a significant reduction of PGE₂ content in ulcerated tissues, with a more pronounced effect observed after treatment with indomethacin (1 mg/kg/day) (Figure 4B). Similar results were obtained at day 3 or 7 of drug administration (Figure 4B).

RT-PCR analysis of NAG-1 mRNA

In gastric tissues from sham ulcerated rats, RT-PCR analysis revealed the basal expression of NAG-1 mRNA (Figure 5A). This expression pattern did not differ significantly from that observed in intact animals (not shown). In control ulcerated rats receiving drug vehicle for 1 or 7 days, NAG-1 expression was enhanced (Figure 5A). Treatment of ulcerated animals with SC-560 (2.5 mg/kg/day), DFU (5 mg/kg/day) or indomethacin (1 mg/kg/day) for 1 day induced a significant enhancement of NAG-1 expression in the ulcerated tissue, while celecoxib (1 mg/kg/day) or valdecoxib (1 mg/kg/day) did not modify such expression pattern (Figure 5A).

Western blot assay of NAG-1, cleaved caspase-3 and PCNA

The expression of NAG-1 was detected in gastric tissue obtained from sham ulcerated rats (Figure 5B), and this expression pattern was similar in stomachs from intact animals (not shown). In control animals with gastric ulcer treated with drug vehicle for 1 day, the expression of NAG-1 in the ulcerated area was found to be increased (Figure 5B). Treatment

of ulcerated animals with SC-560 (2.5 mg/kg/day), DFU (5 mg/kg/day) or indomethacin (1 mg/kg/day) for 1 day was associated with a significant enhancement of NAG-1 expression in the ulcerated tissue, while celecoxib (1 mg/kg/day) or valdecoxib (1 mg/kg/day) were without effect (Figure 5B). Of note, in preliminary experiments we had previously observed that, when tested at the dose of 3 mg/kg/day, celecoxib or valdecoxib did not affect the expression of NAG-1 protein in gastric ulcerated tissues (not shown).

The activation of caspase-3 was found to be increased in control gastric ulcerated tissues after 1 day of drug vehicle administration, as compared with sham ulcerated rats (Figure 6A). Under these conditions, the administration of SC-560 (2.5 mg/kg/day), DFU (5 mg/kg/day) or indomethacin (1 mg/kg/day) for 1 day elicited a significant increase in NAG-1 expression in the ulcerated tissue, while celecoxib (1 mg/kg/day) or valdecoxib (1 mg/kg/day) did not exert any significant effect (Figure 6B).

The expression of PCNA was not increased in gastric ulcerated tissues after 1 day of treatment with drug vehicle, as compared with sham ulcerated rats (Figure 6C). Under these conditions, SC-560 (2.5 mg/kg/day), DFU (5 mg/kg/day), celecoxib (1 mg/kg/day) or valdecoxib (1 mg/kg/day) did not modify the expression of PCNA, while treatment with indomethacin (1 mg/kg/day) was associated with a significant decrease (Figure 6D).

Immunohistochemical analysis of NAG-1 and cleaved caspase-3

The expression of NAG-1 and cleaved caspase-3 was detected in gastric wall samples from sham ulcerated and control ulcerated rats after 1 day from starting drug vehicle administration (Figure 7). With regard for NAG-1 expression, the gastric mucosa of sham ulcerated rats showed immunostained epithelial cells both at the surface and gland bottom. In control ulcerated rats, NAG-1 expression was full-thickness enhanced both at the ulcer margin and bed. A specific staining was appreciable in most of the mucous-producing and

glandular cells of ulcer margin; specific granular immunoprecipitates were found also in smooth muscle cells of vessels and muscularis propria. Considerable amounts of NAG-1 immunoreactive infiltrating cells, spindle-shaped and smooth muscle cells were evident at the ulcer bed. Cleaved caspase-3 was found to be constitutively expressed in the surface epithelium and mucous neck cells of sham ulcerated rats. This expression pattern was enhanced in control ulcerated rats. In particular, a marked staining was observed in surface epithelial cells at the ulcer margins as well as in infiltrating cells and spindle-shaped mesenchymal cells of the granulation tissue at the ulcer bed (Figure 7). When animals were treated with test drugs for 1 day, SC-560 (2.5 mg/kg/day), DFU (5 mg/kg/day) or indomethacin (1 mg/kg/day) were associated with a significant increment of both NAG-1 and cleaved caspase-3 expression in the ulcerated tissues, while celecoxib (1 mg/kg/day) or valdecoxib (1 mg/kg/day) did not exert any relevant effect (Table 2).

Discussion

The present study examined the effects of different COX inhibitors on healing of experimental ulcers in an attempt of unraveling the possible contribution of mechanisms unrelated to COX inhibition. Our findings are consistent with the idea that: a) COX-independent mechanisms take a prominent part in the delaying action of COX inhibitors on ulcer healing, depending on the chemical structure of individual drugs; b) NAG-1 induction plays a role in the mechanisms through which COX inhibitors delay ulcer healing.

In our experiments, the COX-1/COX-2 inhibitor indomethacin caused a marked delay in ulcer healing, in agreement with previous studies (Konturek et al., 2005; Hatazawa et al., 2007). Likewise, the COX-1 inhibitor SC-560 significantly impaired ulcer healing, as previously reported by Konturek et al. (2005). When considering the effects of celecoxib, we did not observe any effect. In keeping with our findings, Poonam et al. (2005) showed that the healing of chronic gastric ulcers was not affected by 14-day treatment with celecoxib in rats. Notably, in a study on healthy volunteers, celecoxib, at the maximal daily dose of 800 mg/day, did not impair the healing of gastric lesions induced by endoscopic biopsy forceps (Dikman et al., 2009). However, literature data on celecoxib are conflicting. For instance, Tibble et al. (2001) found that celecoxib, administered for 6 days at 9 mg/kg/day, delayed ulcer healing in rats. Similarly, a 15-day treatment with celecoxib at 1.8 mg/kg twice daily impaired ulcer repair in rats (Berenguer et al., 2002). In these reports, the time course of drug administration differed from ours, since in both cases drug treatments were started 24 hours after ulcer induction, while we allowed a full development of ulcer before starting the administration of test drugs. By contrast, Ma et al. (2002) followed the same administration schedule adopted in our study, but celecoxib, given at 10 mg/kg/day, was found to delay ulcer healing. When considering the dose issue, it is important to remark that we took care of selecting appropriate doses of COX inhibitors, by performing preliminary experiments to

identify the doses falling within the range of selectivity for COX isoforms. Such dose-finding experiments represent a point of strength in support of the findings yielded by our subsequent experiments, since, based on this strategy, we could observe that the COX-2 inhibitors celecoxib, valdecoxib and DFU, once tested at doses sparing COX-1, exerted differential effects on ulcer healing, thus suggesting that some of them were likely to act by COX-2-independent mechanisms. In this regard, by comparison with our results, literature data support the view that increased doses and/or prolonged administration of COX-2 inhibitors may lead to ulcer healing delay, and therefore it is conceivable that a loss of COX-2 selectivity, consequent to the administration of celecoxib at high doses for prolonged periods, could explain its inhibitory effects on ulcer repair, as reported in previous studies (see supplemental file).

When evaluating the expression of COX isoforms in gastric ulcers, we observed a progressive reduction of COX-1 immunopositivity at days 1 and 3, followed by a recovery at day 7 of drug vehicle administration. By contrast, COX-2 expression increased at days 1 and 3, while recovering at day 7. We then moved on to assay PGE₂ in ulcer tissue specimens, since prostaglandins have been reported to play a role in ulcer repair (Konturek et al., 2005). In our experiments, ulcer induction was associated with an enhancement of PGE₂ levels, likely as a consequence of the enhanced COX-2 expression. In addition, all test drugs decreased PGE₂ levels, with magnitudes which were fairly consistent with their COX selectivity and the expression patterns of COX isoforms. However, the inhibitory profiles of our test drugs on PGE₂ levels did not correlate with their effects of ulcer healing. Previous studies have shown that the impairing actions of non-selective NSAIDs on ulcer healing can be shared by selective COX-2 inhibitors, suggesting a predominant role of COX-2 in ulcer repair (Shigeta et al., 1998; Halter et al., 2001). Nevertheless, current evidence on the expression of COX isoforms in gastric ulcers is conflicting, and a role in ulcer healing has

been proposed also for COX-1 (Jackson et al., 2000; To et al., 2001; Schmassmann et al., 2006). Overall, our results, taken together with the inconsistency of previous findings, support the view that COX-dependent mechanisms do not seem to play a predominant role in the impairing actions of COX inhibitors on gastric ulcer healing.

The present results show that different COX inhibitors, endowed with different chemical structures, exerted differential effects on ulcer healing, irrespectively of their COX-1 and/or COX-2 selectivity. The ability of non-selective NSAIDs and selective COX-2 inhibitors to exert pharmacological effects unrelated to COX inhibition is widely recognized (Baek and Eling, 2006; Wang et al., 2011). Moreover, the contribution of COX-independent mechanisms to the pathogenesis of gastric injury associated with NSAID therapy is well known (Scarpignato and Hunt, 2010). However, to the best of our knowledge, this is the first study specifically designed to evaluate the contribution of COX-independent mechanisms in the impairment of ulcer healing evoked by COX inhibitors. In particular, we paid attention to the fact that NSAIDs have been found to induce NAG-1 (Baek and Eling, 2006). For instance, in colonic cancer cell lines, NAG-1 expression increased upon exposure to several NSAIDs, along with an enhancement of apoptosis (Baek et al., 2001). In the present study, our test drugs were found to affect differentially NAG-1 expression, since indomethacin, DFU and SC-560 enhanced its expression, while celecoxib and valdecoxib were without effect. These results strongly correlate with the effects of our test drugs on ulcer repair, suggesting an involvement of NAG-1-dependent mechanisms in the ulcer delaying effects of indomethacin, DFU or SC-560. Consistently with this contention, various COX inhibitors, including indomethacin and SC-560, were found to enhance NAG-1 expression in cancer cell lines, while celecoxib was without effect (Baek and Eling, 2006; Yamaguchi et al., 2008).

Taking into account that gastric ulcer healing is a complex process, which involves cell proliferation and apoptosis (Sánchez-Fidalgo et al., 2004), we examined PCNA

expression, a marker of cell proliferation, and caspase-3 activation, taken as an index of apoptotic cell death, in ulcerated tissues. In control ulcers there was an increase in caspase-3 activation, without appreciable variations of PCNA, which has been found to increase at later stages of ulcer healing (Fornai et al., 2009). Our results showed also that, among the test drugs, only indomethacin decreased PCNA expression, and that treatment with SC-560, DFU or indomethacin, but not celecoxib or valdecoxib, was associated with an increase in caspase-3 activation. Of note, pattern of caspase-3 activation by test drugs did not reflect their profiles of COX-1/COX-2 selectivity, but rather their inducing effects on NAG-1, suggesting that the impairing effects of SC-560, DFU and indomethacin on ulcer healing were likely to be mediated by activation of NAG-1-dependent proapoptotic signaling. In addition, immunohistochemical analysis revealed a rather high degree of tissue co-localization between NAG-1 and cleaved caspase-3 expression, thus strengthening further the concept of a correlation between NSAID-induced NAG-1 expression and apoptotic cell death. Differences in chemical structure might account for the ability of some COX inhibitors of inducing NAG-1, triggering proapoptotic signals and delay ulcer healing, irrespectively of their selectivity for COX-1 and/or COX-2. For instance, DFU, a selective COX-2 inhibitor with methansulfonic structure, was found to delay ulcer healing as well as to activate NAG-1 and caspase-3, while, by contrast, celecoxib and valdecoxib, both endowed with sulfonamidic structure, did not delay ulcer healing and did not affect NAG-1 expression or caspase-3 activation. This contention is supported by previous evidence that NS-398 and L-745,337, both endowed with methansulfonic structures, were also found to delay chronic gastric ulcers (Lesch et al., 1998).

In conclusion, the present study provides the first demonstration that COX inhibitors differ significantly in their ability to impair gastric ulcer healing, and that such a property depends on mechanisms unrelated to the inhibition of COX isoforms and prostaglandin production. Based on the present findings, it is suggested that NAG-1 induction, followed by

activation of proapoptotic pathways, contributes to the delaying effects of COX inhibitors on ulcer healing.

Authorship Contributions

Participated in research design: Colucci, Antonioli, Blandizzi, and Fornai

Conducted experiments: Colucci, Antonioli, Fornai, Ippolito, Awwad, and Segnani

Performed data analysis: Tuccori, Blandizzi, and Bernardini

Wrote or contributed to the writing of the manuscript: Colucci, Fornai, Scarpignato,
Bernardini, and Blandizzi

References

- Ahmad M, Zhang Y, Liu H, Rose ME, and Graham SH (2009) Prolonged opportunity for neuroprotection in experimental stroke with selective blockade of cyclooxygenase-2 activity. *Brain Res* **1279**: 168-573.
- Baek SJ and Eling TE (2006) Changes in gene expression contribute to cancer prevention by COX inhibitors. *Prog Lipid Res* **45**: 1-16.
- Baek SJ, Kim KS, Nixon JB, Wilson LC, and Eling TE (2001) Cyclooxygenase inhibitors regulate the expression of a TGF-beta superfamily member that has proapoptotic and antitumorigenic activities. *Mol Pharmacol* **59**: 901-908.
- Berenguer B, Alarcón de la Lastra C, Moreno FJ, and Martín MJ (2002) Chronic gastric ulcer healing in rats subjected to selective and non-selective cyclooxygenase-2 inhibitors. *Eur J Pharmacol* **442**: 125-135.
- Böttner M, Suter-Crazzolaro C, Schober A, and Unsicker K (1999) Expression of a novel member of the TGF-beta superfamily, growth/differentiation factor-15/macrophage-inhibiting cytokine-1 (GDF-15/MIC-1) in adult rat tissues. *Cell Tissue Res* **297**: 103-110.
- Bottone FG Jr, Martinez JM, Alston-Mills B, Eling TE (2004) Gene modulation by Cox-1 and Cox-2 specific inhibitors in human colorectal carcinoma cancer cells. *Carcinogenesis* **25**: 349-357.
- Colucci R, Fornai M, Antonioli L, Ghisu N, Tuccori M, Blandizzi C, and Del Tacca M (2009) Characterization of mechanisms underlying the effects of esomeprazole on the impairment of gastric ulcer healing with addition of NSAID treatment. *Dig Liver Dis* **41**: 395-405.
- Dikman A, Sanyal S, VON Althann C, Whitson M, Desai J, Bodian C, Brooks A, Bamji N, Cohen L, Miller K, and Aisenberg J (2009) A randomized, placebo-controlled study of

the effects of naproxen, aspirin, celecoxib or clopidogrel on gastroduodenal mucosal healing. *Aliment Pharmacol Ther* **29**: 781-791.

Fornai M, Blandizzi C, Antonioli L, Colucci R, Bernardini N, Segnani C, De Ponti F, and Del Tacca M (2006) Differential role of cyclooxygenase 1 and 2 isoforms in the modulation of colonic neuromuscular function in experimental inflammation. *J Pharmacol Exp Ther* **317**: 938-945.

Fornai M, Colucci R, Antonioli L, Ghisu N, Tuccori M, Blandizzi C, Del Tacca M (2009) Effects of pantoprazole on ulcer healing delay associated with NSAID treatment. *Naunyn Schmiedebergs Arch Pharmacol* **379**: 305-313.

Gierse JK, Zhang Y, Hood WF, Walker MC, Trigg JS, Maziasz TJ, Koboldt CM, Muhammad JL, Zweifel BS, Masferrer JL, Isakson PC, and Seibert K (2005) Valdecoxib: assessment of cyclooxygenase-2 potency and selectivity. *J Pharmacol Exp Ther* **312**: 1206-1212.

Gretzer B, Maricic N, Respondek M, Schuligoi R, and Peskar BM (2001) Effects of specific inhibition of cyclo-oxygenase-1 and cyclo-oxygenase-2 in the rat stomach with normal mucosa and after acid challenge. *Br J Pharmacol* **132**: 1565-1573.

Halter F, Tarnawski AS, Schmassmann A, and Peskar BM (2001) Cyclooxygenase 2-implications on maintenance of gastric mucosal integrity and ulcer healing: controversial issues and perspectives. *Gut* **49**: 443-453.

Hatazawa R, Tanaka A, Tanigami M, Amagase K, Kato S, Ashida Y, and Takeuchi K (2007) Cyclooxygenase-2/prostaglandin E2 accelerates the healing of gastric ulcers via EP4 receptors. *Am J Physiol Gastrointest Liver Physiol* **293**: G788-G797.

Jackson LM, Wu KC, Mahida YR, Jenkins D, and Hawkey CJ (2000) Cyclooxygenase (COX) 1 and 2 in normal, inflamed, and ulcerated human gastric mucosa. *Gut* **47**: 762-770.

- Kim KS, Baek SJ, Flake GP, Loftin CD, Calvo BF, and Eling TE (2002) Expression and regulation of nonsteroidal anti-inflammatory drug-activated gene (NAG-1) in human and mouse tissue. *Gastroenterology* **122**: 1388-1398.
- Konturek SJ, Konturek PC, and Brzozowski T (2005) Prostaglandins and ulcer healing. *J Physiol Pharmacol* **56 Suppl 5**: 5-31.
- Lanas A, Garcia-Rodriguez LA, Arroyo MT, Gomollon F, Feu F, Gonzalez-Perez A, Zapata E, Bastida G, Rodrigo L, Santolaria S, Guell M, De Argila CM, Quintero E, Borda F, Piquè JM (2006) Risk of upper gastrointestinal ulcer bleeding associated with selective cyclo-oxygenase-2 inhibitors, traditional non-aspirin non-steroidal anti-inflammatory drugs, aspirin and combinations. *Gut* **55**: 1731-1738.
- Lesch CA, Gilbertsen RB, Song Y, Dyer RD, Schrier D, Kraus ER, Sanchez B, and Guglietta A (1998) Effects of novel anti-inflammatory compounds on healing of acetic acid-induced gastric ulcer in rats. *J Pharmacol Exp Ther* **287**: 301-306.
- Lichtenberger LM (2001) Where is the evidence that cyclooxygenase inhibition is the primary cause of non-steroidal anti-inflammatory drug (NSAID)-induced gastrointestinal injury? Topical injury revisited. *Biochem Pharmacol* **61**: 631-637.
- Ma L, del Soldato P, Wallace JL (2002) Divergent effects of new cyclooxygenase inhibitors on gastric ulcer healing: Shifting the angiogenic balance. *Proc Natl Acad Sci U S A* **99**: 13243-13247.
- Musumba C, Pritchard DM, and Pirmohamed M (2009) Review article: cellular and molecular mechanisms of NSAID-induced peptic ulcers. *Aliment Pharmacol Ther* **30**: 517-531.
- Poonam D, Vinay CS, and Gautam P (2005) Cyclo-oxygenase-2 expression and prostaglandin E2 production in experimental chronic gastric ulcer healing. *Eur J Pharmacol* **519**: 277-284.

- Sánchez-Fidalgo S, Martín-Lacave I, Illanes M, and Motilva V (2004) Angiogenesis, cell proliferation and apoptosis in gastric ulcer healing. Effect of a selective COX-2 inhibitor. *Eur J Pharmacol* **505**: 187-194.
- Scarpignato C and Hunt RH (2010) Nonsteroidal antiinflammatory drug-related injury to the gastrointestinal tract: clinical picture, pathogenesis, and prevention. *Gastroenterol Clin North Am* **39**: 433-464.
- Schmassmann A, Peskar BM, Stettler C, Netzer P, Stroff T, Flogerzi B, and Halter F (1998) Effects of inhibition of prostaglandin endoperoxide synthase-2 in chronic gastrointestinal ulcer models in rats. *Br J Pharmacol* **123**: 795-804.
- Schmassmann A, Zoidl G, Peskar BM, Waser B, Schmassmann-Suhijar D, Gebbers JO, and Reubi JC (2006) Role of the different isoforms of cyclooxygenase and nitric oxide synthase during gastric ulcer healing in cyclooxygenase-1 and -2 knockout mice. *Am J Physiol Gastrointest Liver Physiol* **290**: G747-G756.
- Shigeta J, Takahashi S, and Okabe S (1998) Role of cyclooxygenase-2 in the healing of gastric ulcers in rats. *J Pharmacol Exp Ther* **286**: 1383-1390.
- Tibble J, Sigthorsson G, Caldwell C, Palmer RH, and Bjarnason I (2001) Effects of NSAIDs on cryoprobe-induced gastric ulcer healing in rats. *Aliment Pharmacol Ther* **15**: 2001-2008.
- To KF, Chan FK, Cheng AS, Lee TL, Ng YP, and Sung JJ (2001) Up-regulation of cyclooxygenase-1 and -2 in human gastric ulcer. *Aliment Pharmacol Ther* **15**: 25-34.
- Wang JS, Ho FM, Kang HC, Lin WW, and Huang KC (2011) Celecoxib induces heme oxygenase-1 expression in macrophages and vascular smooth muscle cells via ROS-dependent signaling pathway. *Naunyn Schmiedebergs Arch Pharmacol* **383**: 159-168.

- Yamaguchi K, Whitlock NC, Liggett JL, Legendre AM, Fry MM, and Baek SJ (2008) Molecular characterisation of canine nonsteroidal anti-inflammatory drug-activated gene (NAG-1). *Vet J* **175**: 89-95.
- Yeomans ND and Naesdal J (2008) Systematic review: ulcer definition in NSAID ulcer prevention trials. *Aliment Pharmacol Ther* **27**: 465-472.
- Yeomans ND (2011) The ulcer sleuths: The search for the cause of peptic ulcers. *J Gastroenterol Hepatol* **26 Suppl 1**: 35-41.
- Yuan Y, Padol IT, Hunt RH (2006) Peptic ulcer disease today. *Nat Clin Pract Gastroenterol Hepatol* **3**: 80-89.

Legends for figures

Figure 1. Diagram displaying the design of the study and the time-course of experimental procedures. SC, SC-560; CEL, celecoxib; VAL, valdecoxib; IND, indomethacin.

Figure 2. (A) Western blot analysis of COX-1 and COX-2 in gastric mucosa from sham ulcerated (SU) rats, or in ulcerated tissue from rats with acetic acid-induced gastric ulcer treated with drug vehicle for 1 day (control ulcer, CU). Animals were subjected to ulcer induction 4 days before the onset of vehicle administration. Each column represents the mean \pm SEM (vertical lines) of values obtained from five to six animals. *P<0.05, significant difference vs sham ulcerated (SU). (B) Immunohistochemical detection of COX-1 and COX-2 in gastric mucosa from sham ulcerated rats after 1 day from the onset of drug vehicle administration. The bottom of fundic glands show a strong COX-1 immunostaining, localized mainly within chief cells, and only few amount of COX-2 is found in different cell types. Bar 100 μ m.

Figure 3. Immunohistochemical detection of COX-1 (A) and COX-2 (B) in sham ulcerated rats or ulcerated tissue from rats with acetic acid-induced gastric ulcer after 1, 3 or 7 days from the onset of drug vehicle administration (i.e., 5, 7, 11 days from surgery). (A) Considerable amount of COX-1 is present in the normal gastric mucosa of sham ulcerated rats, particularly in the neck and base of fundic glands. COX-1 expression was switched off in the ulcerated mucosa at 1 day, with the exception for the mucosa just around the ulcer margin (arrows) and the ulcer bed. COX-1 expression partly recovered recovered at ulcer margins on subsequent days. (B) Little COX-2 amount is constitutively present in gastric mucosa from sham ulcerated rats, mainly in gland bottom epithelial cells. At 1 day, the ulcerated gastric wall displays a marked enhancement of COX-2 expression in the mucosa of ulcer margin and

bed, where many spindle-shaped mesenchymal cells (arrowheads) are present. This expression pattern is progressively attenuated on subsequent days, with the exception for COX-2 immunostained stromal cells at the ulcer bed. Bar 100 μm .

Figure 4. (A) Ulcer areas in animals with acetic acid-induced gastric ulcer treated with vehicle (control ulcer, CU), SC-560 (SC, 2.5 mg/kg/day), DFU (5 mg/kg/day), celecoxib (CEL, 1 mg/kg/day), valdecoxib (VAL, 1 mg/kg/day) or indomethacin (IND, 1 mg/kg/day) for 1, 3 or 7 days. (B) Prostaglandin E₂ (PGE₂) levels in the gastric mucosa from ulcerated rats treated with vehicle (control ulcer, CU), SC-560 (SC, 2.5 mg/kg/day), DFU (5 mg/kg/day), celecoxib (CEL, 1 mg/kg/day), valdecoxib (VAL, 1 mg/kg/day) or indomethacin (IND, 1 mg/kg/day) for 1, 3 or 7 days. Animals were subjected to ulcer induction 4 days before the onset of drug administrations. Test drugs or their vehicle were administered intragastrically. The stomachs were examined 24 h after the last administration. Each column represents the mean \pm SEM (vertical lines) of values obtained from nine to ten animals. *P<0.05, significant difference vs vehicle (CU); ^aP<0,05, significant difference vs SC, DFU, CEL, VAL.

Figure 5. (A) Reverse transcription-polymerase chain reaction (RT-PCR) analysis of NAG-1 in gastric mucosa from sham ulcerated rats (SU), or in ulcerated tissue from rats with acetic acid-induced gastric ulcer treated with drug vehicle for 1 or 7 days (CU), as well as SC-560 (SC, 2.5 mg/kg/day), DFU (5 mg/kg/day), celecoxib (CEL, 1 mg/kg/day), valdecoxib (VAL, 1 mg/kg/day) or indomethacin (IND, 1 mg/kg/day) for 1 day. (B) Western blot analysis of NAG-1 in gastric mucosa from sham ulcerated (SU) rats, or ulcerated tissue from rats with acetic acid-induced gastric ulcer treated with drug vehicle (control ulcer, CU), SC-560 (SC, 2.5 mg/kg/day), DFU (5 mg/kg/day), celecoxib (CEL, 1 mg/kg/day), valdecoxib (VAL, 1

mg/kg/day) or indomethacin (IND, 1 mg/kg/day) for 1 day. Animals were subjected to ulcer induction 4 days before the onset of drug or vehicle administrations. Test drugs or their vehicle were administered intragastrically. The stomachs were examined 24 h after the last administration. Each column represents the mean \pm SEM (vertical lines) of values obtained from nine to ten animals. *P<0.05, significant difference vs vehicle (CU). In both analyses, animals were subjected to ulcer induction 4 days before the onset of vehicle administration.

Figure 6. Western blot analysis of cleaved caspase-3 and PCNA in gastric mucosa from sham ulcerated (SU) rats, or in ulcerated tissue from rats with acetic acid-induced gastric ulcer treated with drug vehicle (control ulcer, CU), SC-560 (SC, 2.5 mg/kg/day), DFU (5 mg/kg/day), celecoxib (CEL, 1 mg/kg/day), valdecoxib (VAL, 1 mg/kg/day) or indomethacin (IND, 1 mg/kg/day) for 1 day. **(A)** Analysis of uncleaved and cleaved caspase-3 in SU or CU rats. **(B)** Analysis of cleaved caspase-3 in CU, or in animals treated with SC, DFU, CEL, VAL or IND. **(C)** Analysis of PCNA in SU or CU rats. **(D)** Analysis of PCNA in CU, or in animals treated with SC, DFU, CEL, VAL or IND. Animals were subjected to ulcer induction 4 days before the onset of drug treatments. Test drugs or their vehicle were administered by intragastric gavage. Specimens of ulcerated gastric tissue were collected 24 h after the last administration. Each column represents the mean \pm SEM (vertical lines) of values obtained from five to six animals. *P<0.05, significant difference vs vehicle (CU).

Figure 7. Immunohistochemical detection of NAG-1 and cleaved caspase-3 in gastric wall of sham ulcerated rats and rats with acetic acid-induced gastric ulcer after 1 day from the onset of drug vehicle administration. NAG-1 immunostaining is present in scattered superficial cells and gland bottom cells of mucosa layer from sham ulcerated rats (arrows); NAG-1 expression is enhanced in ulcerated stomach at level of the ulcer margins (surface epithelium, smooth

muscle cells) and bed tissues (inflammatory infiltrates, spindle-shaped and smooth muscle cells). Low amount of cleaved caspase-3 is present in the superficial mucous-producing and neck cells of normal gastric mucosa (arrows); the expression increases at both the ulcer margins (superficial epithelium) and bed (inflammatory infiltrates, spindle-shaped cells, arrows). CM: circular muscle layer. Bars 100 μ m.

Tables

Table 1. Potency and selectivity of test drugs for COX isoforms in the air pouch model

Drug (mg/kg)	% of inhibition vs control	
Indomethacin	COX-1 ^a	COX-2 ^b
0.3	64	59
1	92	89
3	98	96
SC-560		
1	82	8
2.5	95	11
5	98	24
DFU		
1.5	2	55
5	6	94
15	11	99
Celecoxib		
0.3	3	58
1	14	91
3	17	99
Valdecoxib		
0.3	3	70
1	8	95
3	16	94

^a inhibition of gastric PGE₂

^b inhibition of air pouch PGE₂

Table 2. Summary of NAG-1 and activated caspase-3 expression^a detected by immunohistochemistry in gastric tissues from sham ulcerated and control ulcerated rats after 1 day from starting vehicle or test drugs administration

Treatment	Gastric tissues	NAG-1	Caspase-3
Sham ulcer	mucosa	+/-	+/-
CU + drug vehicle	UB	++	++
	UM	++	+
CU + SC-560	UB	++	++
	UM	+++	+++
CU + DFU	UB	++	++
	UM	+++	+++
CU + celecoxib	UB	+	++
	UM	++	+
CU + valdecoxib	UB	+	+
	UM	++	++
CU + indomethacin	UB	+	+
	UM	+++	++

^a Intensity of expression is reported as negative (-), weakly positive (+/-), moderately positive (+), positive (++), strongly positive (+++). CU, control ulcer; UB, ulcer bed; UM, ulcer margins

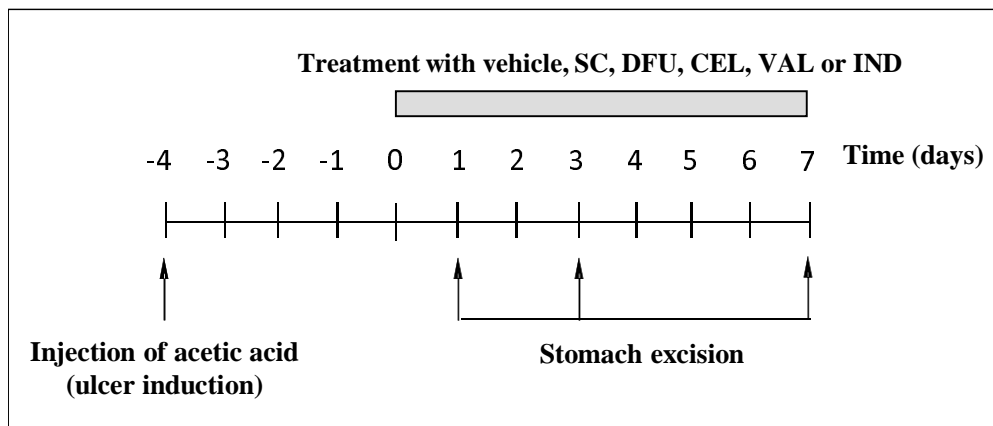


Figure 1

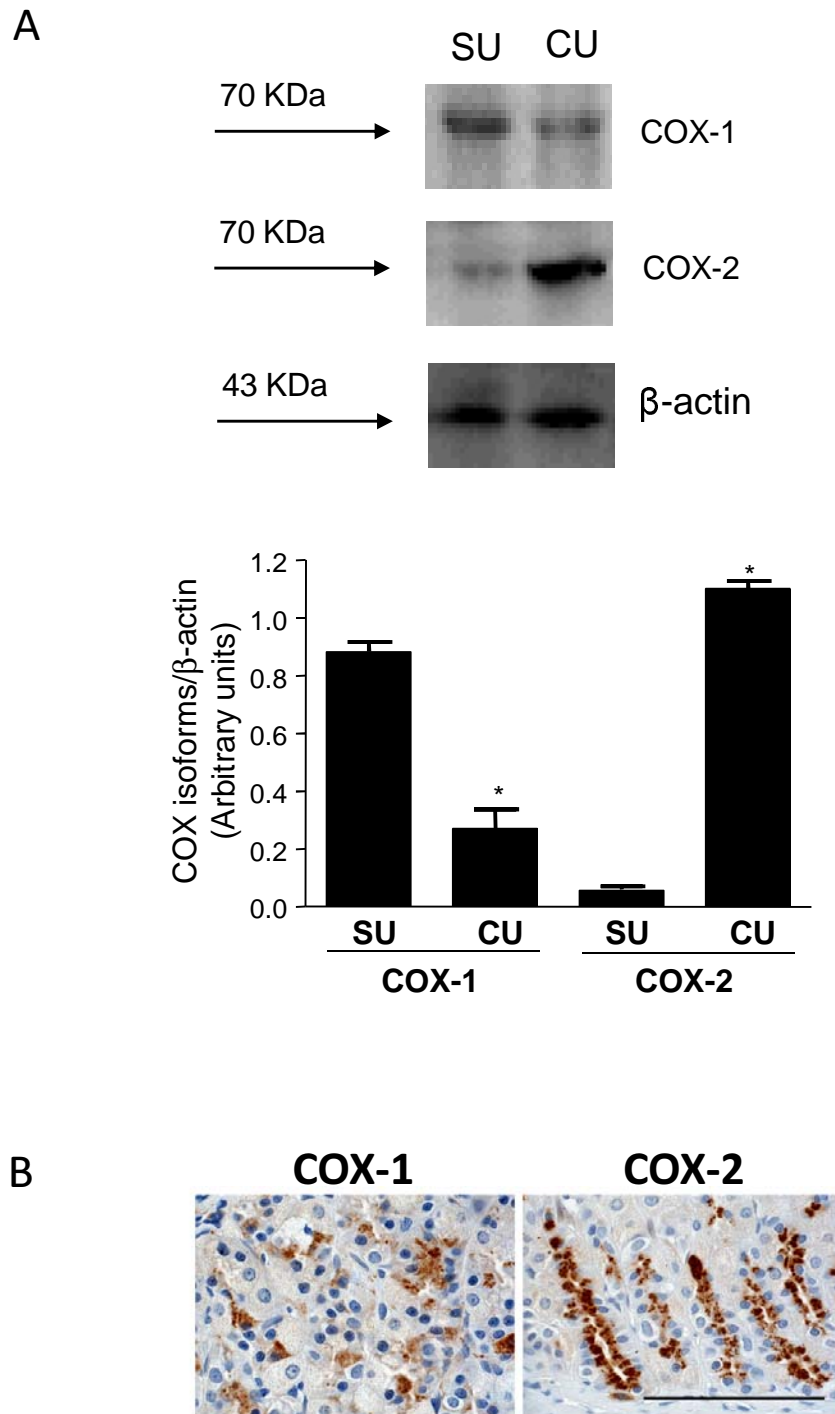


Figure 2

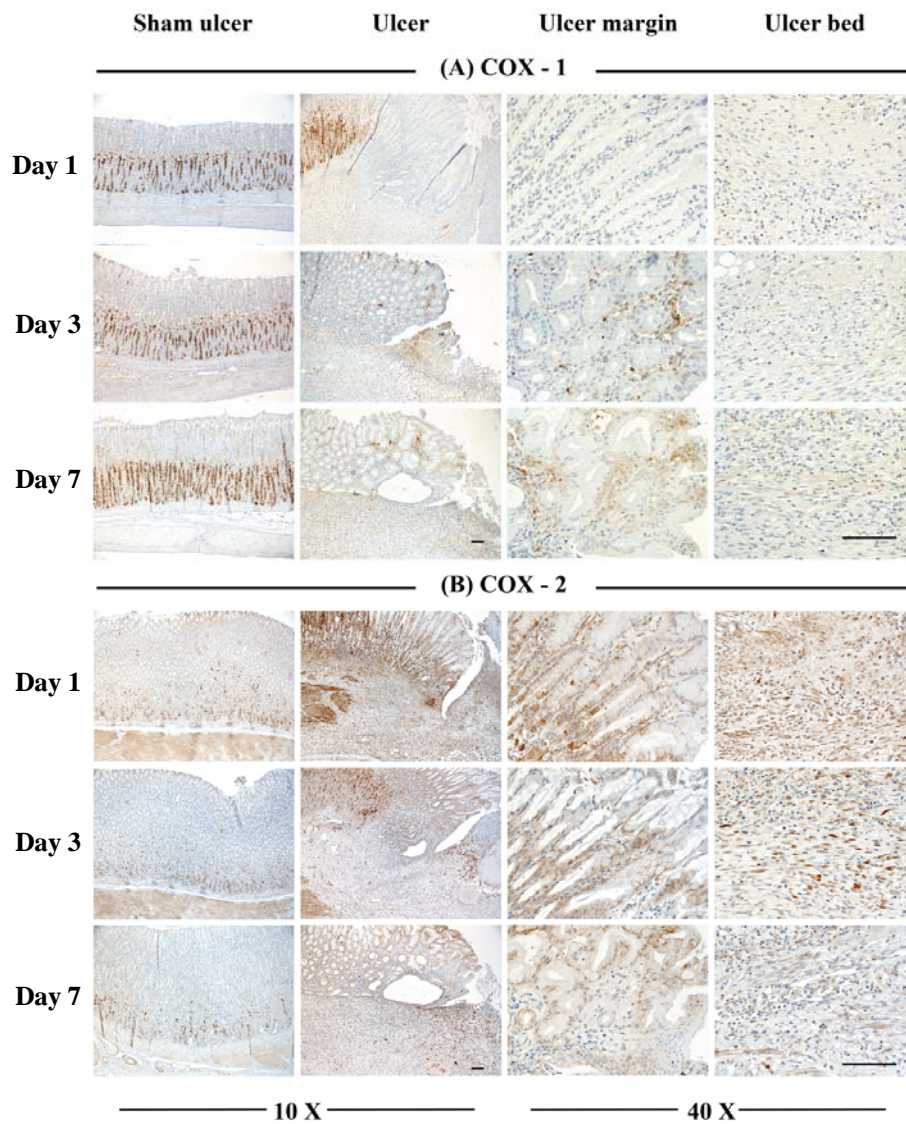


Figure 3

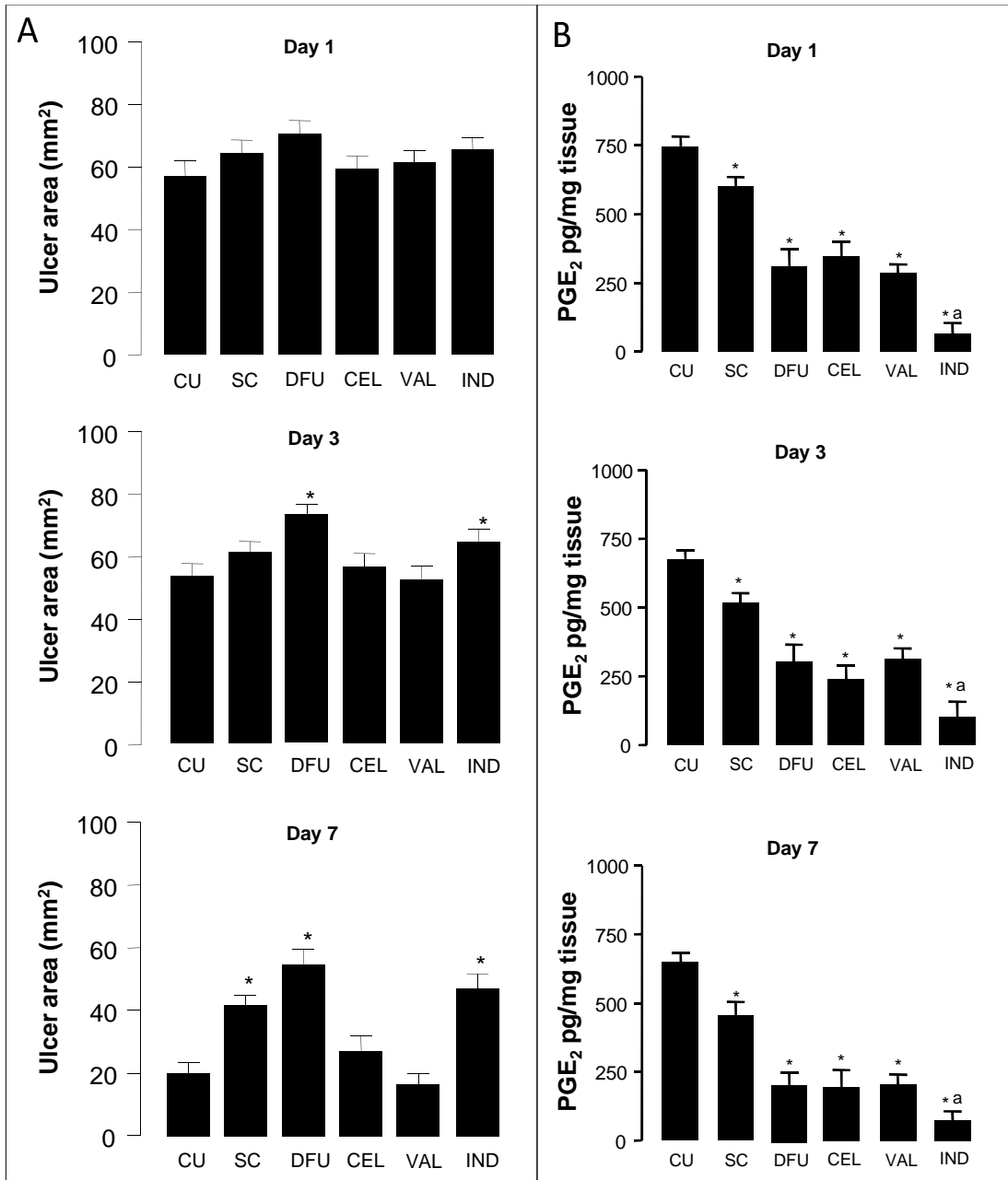
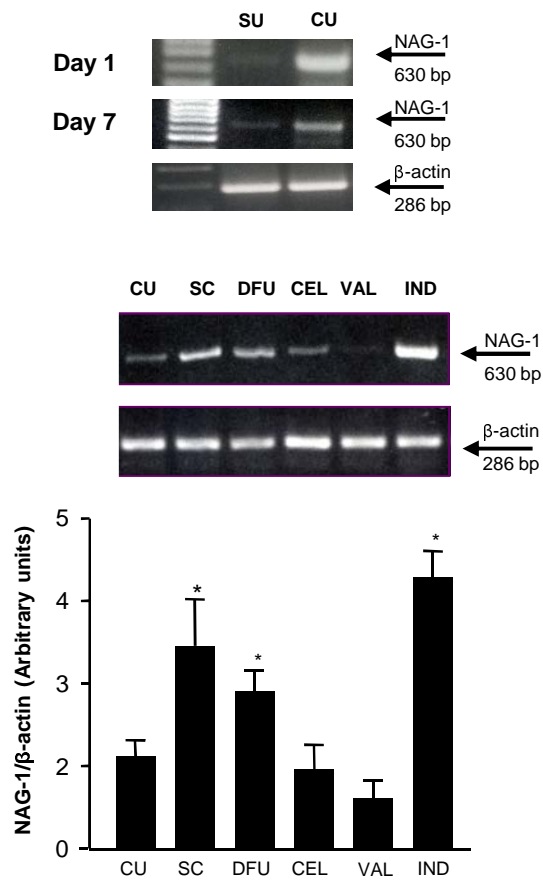


Figure 4

A



B

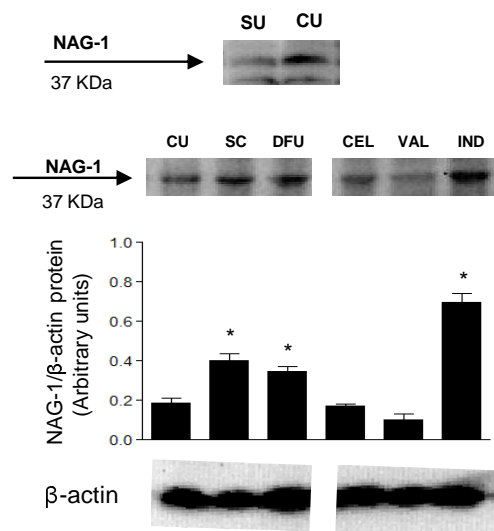


Figure 5

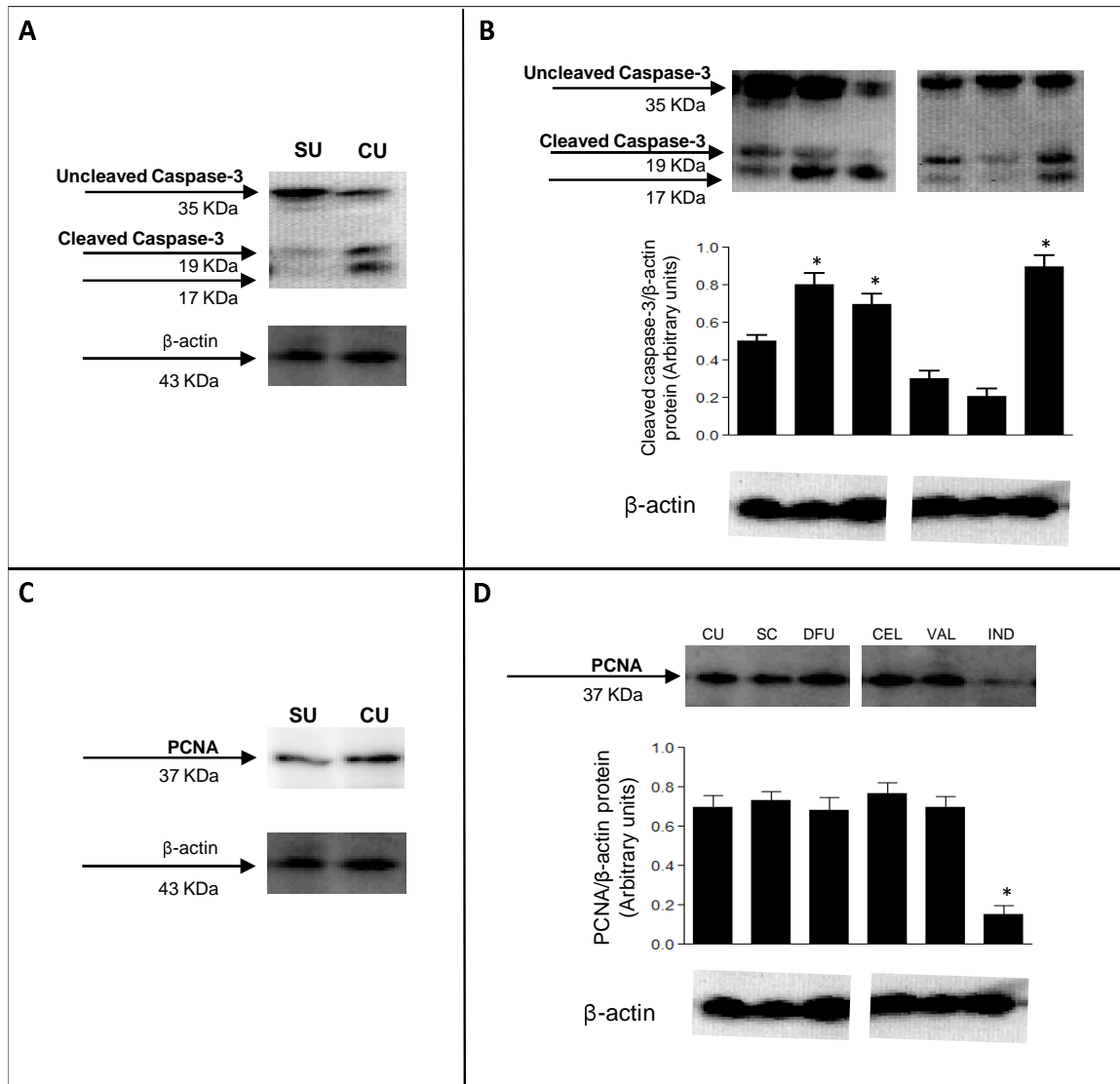


Figure 6

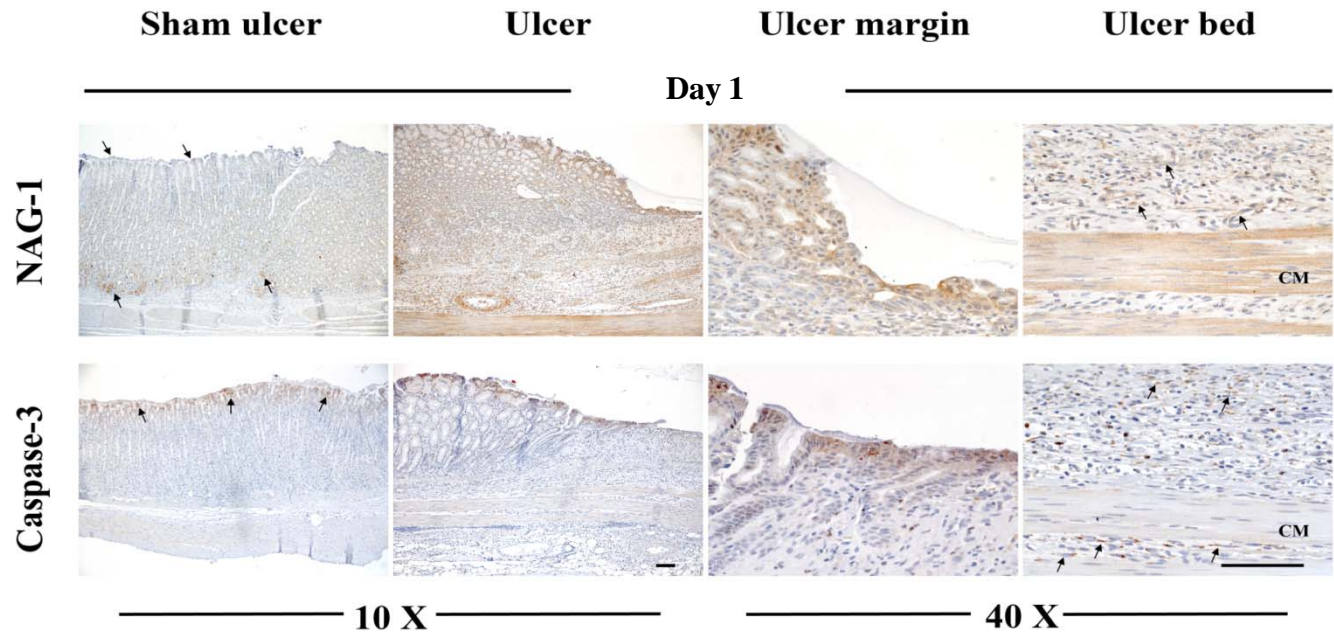


Figure 7

Rocchina Colucci, Luca Antonioli, Nunzia Bernardini, Chiara Ippolito, Cristina Segnani, Oriana Awwad, Marco Tuccori, Corrado Blandizzi, Carmelo Scarpignato, Matteo Fornai

NSAID Activated Gene (NAG-1) plays a role in the impairing effects of cyclooxygenase inhibitors on gastric ulcer healing. *Journal of Pharmacology and Experimental Therapeutics*

Summary of the currently available evidence about the effects of the selective COX-2 inhibitors celecoxib and rofecoxib on healing of experimental gastric ulcers

Species	Experimental model	Drug	Dose	Effects	Reference
Rat	Cryoprobe	Celecoxib	9 mg/kg/day for 3 or 6 days	No effects at day 3; delay in ulcer healing at day 6	1
Rat	Subserosal injection of 5% acetic acid (50 µl)	Celecoxib	1.8 mg/kg twice daily for 8 or 15 days	No effects at day 8; delay in ulcer healing at day 15	2
Rat	Serosal 80% acetic acid for 60 s	Celecoxib	10 mg/kg/day for 7 days	Delay in ulcer healing	3
Rat	Serosal 40% acetic acid for 90 s	Celecoxib	10 mg/kg/day for 5, 10 or 14 days	No effects	4
Rat	Serosal acetic acid (100% ?) for 25 s	Rofecoxib	10 mg/kg/day for 7, 10 or 14 days	Delay in ulcer healing	5
Rat	Subserosal injection of 20% acetic acid (50 µl)	Rofecoxib	2.5 mg/kg/day for 14 days	Delay in ulcer healing	6
Rat	Subserosal injection of 20% acetic acid (50 µl)	Rofecoxib	2.5 mg/kg/day for 7 or 14 days	No effects at day 7; delay in ulcer healing at day 14	7

- 1 Tibble J, Sigthorsson G, Caldwell C, Palmer RH, and Bjarnason I (2001) Effects of NSAIDs on cryoprobe-induced gastric ulcer healing in rats. *Aliment Pharmacol Ther* **15**: 2001-2008.
- 2 Berenguer B, Alarcón de la Lastra C, Moreno FJ, and Martín MJ (2002) Chronic gastric ulcer healing in rats subjected to selective and non-selective cyclooxygenase-2 inhibitors. *Eur J Pharmacol* **442**: 125-135.
- 3 Ma L, del Soldato P, Wallace JL (2002) Divergent effects of new cyclooxygenase inhibitors on gastric ulcer healing: Shifting the angiogenic balance. *Proc Natl Acad Sci U S A* **99**: 13243-13247.
- 4 Poonam D, Vinay CS, and Gautam P (2005) Cyclo-oxygenase-2 expression and prostaglandin E2 production in experimental chronic gastric ulcer healing. *Eur J Pharmacol* **519**: 277-284.
- 5 Brzozowski T, Konturek PC, Konturek SJ, Sliwowski Z, Pajdo R, Drozdowicz D, Ptak A, Hahn EG (2001) Classic NSAID and selective cyclooxygenase (COX)-1 and COX-2 inhibitors in healing of chronic gastric ulcers. *Microsc Res Tech* **53**: 343-353.
- 6 Sánchez-Fidalgo S, Martín-Lacave I, Illanes M, and Motilva V (2004) Angiogenesis, cell proliferation and apoptosis in gastric ulcer healing. Effect of a selective COX-2 inhibitor. *Eur J Pharmacol* **505**: 187-194.
- 7 Motilva V, Alarcón de la Lastra C, Bruseghini L, Manuel Herrerias J, Sánchez-Fidalgo S (2005) COX expression and PGE₂ and PGD₂ production in experimental acute and chronic gastric lesions. *Int Immunopharmacol* **5**: 369-379.