

Rapamycin inhibits formation of urethral stricture in rabbits

Tie Chong, De-lai Fu, He-cheng Li, Hui-bo Zhang, Peng Zhang, Wei-min Gan and
Zi-ming Wang

Department of Urology, the Second Affiliated Hospital, School of Medicine, Xi'an
Jiaotong University, Xi'an 710004, Shaanxi, P R China; Department of Urology, the
Affiliated Hospital of Shaanxi Traditional Chinese Medical College, Xianyang
710004, Shaanxi, P R China.

Running Title: Rapamycin inhibits urethral stricture formation in rabbit

Correspondence to : Ziming Wang

Department of Urology, the Second Affiliated Hospital, School of Medicine, Xi'an

Jiaotong University, Xi'an 710004, Shaanxi, P R China.

Telephone: +86-029-87679442

E-mail: Ziming-W@263.net

number of text pages: 21

number of tables: 1

number of figures: 4

number of references: 26

number of words in the Abstract: 208

number of words in the Introduction: 391

number of words in the Discussion: 992

A recommended section assignment to guide the listing in the table of contents:

Chemotherapy, antibiotics and gene therapy

Abstract

Rapamycin has been reported to inhibit hepatic fibrosis, lung fibrosis, renal fibrosis and subglottic stenosis. Fibrosis is also involved in urethral stricture. Therefore we investigated the effect of rapamycin on the inhibition of urethral stricture formation in a rabbit model. Firstly, models of urethral stricture were successfully established by electrocoagulation of the bulbar urethra with adult New Zealand male rabbits. Forty-six model rabbits were randomly assigned to four groups: high dose rapamycin (R_H , 1.0 mg/day), low dose rapamycin (R_L , 0.1 mg/day), DMSO alone (DMSO, solvent control) and normal saline (NS). Urethral stricture was assessed by a retrograde urethrogram and video-urethroscopy. Urethra pathology was evaluated by H&E staining and Sirius Red staining. After 28 days treatment, lumen reduction in the R_H , R_L , DMSO, and NS groups were 36.0%, 56.5%, 69.1%, and 82.9%, respectively. Comparison of the rapamycin groups (R_H and R_L) and control groups (DMSO and NS) indicated significantly less restriction in the rapamycin groups. Histopathology confirmed the presence of fibroblasts and an increase in collagen at the stricture site in the two control groups, but not in the R_H or R_L groups. These results indicate that rapamycin inhibits experimentally induced urethral stricture formation in rabbits. This may be due to its inhibition of fibroblast proliferation and collagen expression.

Introduction

Urethral stricture is a frequent source of lower urinary tract disorders in men. In this condition, there is a narrowing of the urethra by a noncompliant section of urethral scar tissue that is caused by repair of an insult. The most common causes of urethral stricture are idiopathic, transurethral resection, urethral catheterization, pelvic fracture, and surgery for hypospadias (Lumen et al., 2009). Urethral dilation and visual internal urethrotomy are the most common treatments for urethral stricture. These procedures can transiently improve urinary flow, but repeated instrumentation may exacerbate scar formation and complicate subsequent reconstruction (Waxman and Morey, 2006). Repeat dilation or urethrotomy is considered to be neither clinically effective nor cost-effective (Greenwell et al., 2004). Urethroplasty has a better cure rate (Langston et al., 2009), but is not a routine procedure because it requires certain expertise.

Fibrosis, caused by excessive collagen synthesis and changes in the composition of the extracellular matrix, is a key event in the pathogenesis of urethral stricture. Varying degrees of spongiofibrosis leads to poorly compliant tissue and decreased urethral lumen caliber (Brandes et al., 2008). Elongated myofibroblasts, involved in continuous collagen synthesis, occur in the early stages of stricture formation.

Based on treatments for organ fibrosis, previous studies have examined the effect of antifibrotic drugs in limiting urethral stricture formation, such as halofuginone (Nagler et al., 2000; Krane et al, 2011), mitomycin C (Mazdak et al., 2007), bitoxin A

(Khera et al., 2004), somatostatin analogue (Andersen et al., 2003), and glucocorticoid (Sciarra et al., 2005). However, there are no systematic studies of the effect of drugs on urethral stricture, and further studies are needed to evaluate the effectiveness and safety of drugs before clinical testing. Therefore, there is an urgent need to identify new agents that can be used to treat the formation of urethral strictures.

Rapamycin, an immunosuppressive agent, inhibits proliferation of diverse cell types, including smooth muscle cells, endothelial cells, and fibroblasts, which are crucial to the development of fibrosis. Previous studies have reported that rapamycin significantly inhibited hepatic fibrosis (Biecker et al., 2005), lung fibrosis (Korfhagen et al., 2009; Mehrad et al., 2009), renal fibrosis (Damião et al., 2007), and subglottic stenosis (Branch et al., 2004). Fibrosis is also involved in urethral stricture. In the present study we investigated the effect of rapamycin on the inhibition of urethral stricture formation in a rabbit model.

Materials and Methods

Experimental animals

All experiments were performed according to the guidelines of the committee of animal research at Xi'an Jiaotong University and "Principles of Laboratory Animal Care" (NIH publication No. 86-23, revised 1985). All animals were adult male New Zealand rabbits, 4 months old, with a weight of 2.00 ± 0.19 kg. Rabbits were kept in special cages in a specific pathogen-free environment, and were allowed free movement and free access to food and drink.

Surgical induction of urethral stricture

All rabbits were anaesthetized with i.v. diazepam (25 mg/kg) and Ketamine (2.5 mg/kg). A 13FR pediatric resectoscope (Hangzhou Hawk Optical Electronic Instruments Co., Ltd, Hangzhou, China) was used for endoscopic procedures. For surgery, rabbits were placed in a supine position and a standard 10 mm long circumferential electrocoagulation of the bulbar urethra was induced under sterile conditions. This procedure was performed distal to the verumontanum and away from the external sphincter with a hook-shaped electrode at a power of 40 W (Jaidane et al., 2003). Electrocoagulation was continued until blanching and ulceration of the mucosa occurred (Meria et al., 1999; Jaidane et al., 2003), typically about 1 minute. All electrocoagulation procedures were performed by the same urologist (He-cheng LI) who aimed to use the same length and depth for all animals. Urine was not diverted deliberately and no antibiotics were given.

Drug administration

After electrocoagulation, animals were randomly allocated into four groups: *(i)* DMSO (50 g/L DMSO, 10 mL/day, n = 8); *(ii)* high dose rapamycin in DMSO, R_H (1.0 mg in 10 mL solvent/day, n = 15); *(iii)* low dose rapamycin in DMSO, R_L (0.1 mg in 10 mL solvent/day, n = 15); or *(iv)* normal saline, NS (9 g/L NaCl, 10 mL/day, n = 8). Drugs were given once per day for 28 days by retrograde urethral injection for 1-2 mins3-5 seconds, beginning on the first day after electrocoagulation.

Evaluation of urethral stricture

During the radiological, urethroscopic, and histopathological evaluations, the evaluator was blinded to treatment group. Twenty-eight days after electrocoagulation, urethral gross morphology was evaluated by retrograde urethrogram and urethroscopy. Contrast medium (760 g/L meglumine amine 20 mL diluted by 9g/L sodium chloride 20mL) was injected slowly and directly into the urethra by the same experimenter, with X-ray direction used to visualize the configuration of the lumen. The urethral caliber was measured as described by Jaidane et al. (2003). For estimation of the percent of urethral restriction, urethrograms and video-urethroscopy were used to measure the diameter of the stricture at its narrowest part and of the distal urethra. Strictures were considered significant if the urethral lumen decreased more than 50% (Jaidane et al., 2003).

Histological examination

All urethras were processed for histological examination as described by

Anderson (Andersen et al., 2003). Formaldehyde was injected into the urethra under a pressure of 1.8 kPa for 30 min. Then, the urethra was removed, fixed in formaldehyde for 24 h, and embedded in paraffin. Sections were cut corresponding to the two distension sites, longitudinal to the posterior wall and perpendicular to the posterior wall, and stained with Sirius red and H&E. All slides were reviewed by the same uropathologist (Kang-min WANG). The severity of scar formation was classified as light, medium or heavy.

Statistical methods

Means and standard deviations (SDs) were calculated and presented for each group. Comparisons were performed using ANOVA with post-hoc comparison adjusted by the Bonferroni method. Data were analyzed using SAS 9.0 (SAS Institute Inc., Cary, NC). A *p* value less than 0.05 was considered statistically significant.

Results

One rabbit in the R_H group and one rabbit in the NS group died during anaesthesia. Urethral bleeding occurred in almost all rabbits after electrocoagulation, but was not severe and stopped after 3 days in all cases. Two rabbits in the R_H group, three rabbits in the R_L group, and two rabbits in the DMSO group developed diarrhea and were sacrificed during the first week. Thus, we evaluated treatment effects for 12 rabbits in the R_H group, 12 rabbits in the R_L group, 6 rabbits in the DMSO group, and 7 rabbits in the NS group. There were no obvious abnormal reactions during the 28-day treatment period.

Retrograde urethrography and urethroscopy

All rabbits in the control groups had significant urethral strictures. The lumen diameter decreased $82.9 \pm 17.2\%$ in the NS group and $69.1 \pm 8.81\%$ in the DMSO group. Two of the 12 rabbits in the R_H group (17%) and 8 of 12 rabbits in the R_L group (67%) developed significant strictures. The mean lumen diameter decreased $36.5 \pm 21.5\%$ (range: 12.9-79.3%) in the R_H group and $56.6 \pm 17.4\%$ (range: 13.8-77.3%) in the R_L group. Urethral stricture was significantly greater in the NS group than in the R_H group ($p < 0.05$) and the R_L group ($p < 0.05$). The DMSO group had significantly more stricture than the R_H group ($p < 0.05$), but not the R_L group ($p > 0.05$) (Fig. 1, Table 1). In five rabbits of the R_H group, contrast medium leaked out of the urethral tract.

Based on urethroscopy, the urethral epithelium covered the traumatized surface, except in five rabbits in the R_H group, in which leaking contrast medium was observed in the urethrogram. The unhealed mucosa had a rugose surface with slight edema and hyperemia (Fig. 2).

Histology

We observed varying degree of fibrosis beneath the epithelium in rabbits given different treatments (Fig. 3). The two rapamycin-treated groups had fibrosis that was mainly localized in the submucosal layer (Figs. 3A and B). However, the two control groups had fibrosis distributed over the submucosal and muscular layers (Figs. 3C and D). In all cases, there were abundant cells present in the fibrotic tissues.

Finally, we performed Sirius Red staining to identify the presence and amount of collagen in the urethral tissues (Fig. 4). The two rapamycin-treated groups had light red staining of the urethral stricture site, indicating relatively low collagen concentration (Figs. 4A and B). However, the two control groups had a darker crimson staining, indicating the presence of abundant collagen (Figs. 4C and D).

Discussion

In this pilot study, we used an animal model of urethral stricture to test the efficacy of intraurethral injection of rapamycin on the amelioration of urethral stricture. We found that rapamycin significantly reduced urethral stricture, an effect mediated by its inhibition of urethral fibroblast formation and/or reduction of collagen accumulation.

Previous studies adopted rabbit models to investigate urethral stricture. Meria et al. (1999) developed a urethral stricture model in rabbits by use of endoscopic electrocoagulation. This is a particularly suitable model for study of urethral stricture because the rabbit urethra is similar to that of humans, rabbits are inexpensive experimental animals, and rabbits have relatively large diameter urethras. Meria et al. performed 3-5 mm circumferential electrocoagulation to the bulbar urethra of New Zealand male rabbits, and reported that 50% of the rabbits developed significant bulbar strictures at day-15. Jaidane et al. (2003) used the same model to study the amelioration of urethral stricture by halofuginone, an inhibitor of collagen expression. They performed 15 mm almost circumferential electrocoagulation of the bulbar urethra, leaving two free areas at the 11 o'clock and 1 o'clock positions. All rabbits had significant and severe urethral strictures, with a mean lumen decrease of 87.5%.

In this animal model of urethral stricture, it is important to induce a trauma that is neither too mild (which would have negligible physiological effects), nor too severe (which can lead to severe urine retention and death). Therefore, in our study, we

performed a 10 mm long circumferential electrocoagulation on all animals. We did not administer antibiotics during the perioperative period, because inflammation may play an important role in the formation of urethral strictures. Our procedure resulted in a mean $82.9 \pm 17.1\%$ reduction in lumen in the NS group with no evidence of urine retention. This suggests that our procedure is appropriate for study of the formation of urethral strictures.

We used urethrograms to demonstrate that the urethral lumen was significantly reduced in the DMSO and NS control groups, and that animals given low-dose or high-dose rapamycin had significantly less stricture. These results were confirmed by urethroscopy. Although our DMSO group had slightly less urethral stricture than the NS group, this difference was not statistically significant. In addition, our results suggest that there may be a dose-dependent effect of rapamycin, based on the slightly larger lumen size of the R_H group (although this difference was not statistically significant). While there are limitations of this pilot study, this study is the first to demonstrate that rapamycin inhibits urethral stricture formation in an animal model. Previous studies have shown that rapamycin inhibits fibrotic diseases, including coronary artery restenosis after stent implantation (Moses et al., 2003), hepatic fibrosis (Biecker et al., 2005), lung fibrosis (Korfhagen et al., 2009; Mehrad et al., 2009), myocardial fibrosis (Gao et al., 2006), and renal fibrosis (Wu et al., 2006; Damião et al., 2007). These physiological effects may be due to the rapamycin-mediated reduction in the number of fibrocytes (Mehrad et al., 2009)

and/or prevention of collagen expression (Korfhagen et al., 2009; Mehrad et al., 2009). The inhibitory effects of rapamycin on cell growth have been demonstrated. A study by Faivre et al. (2006) showed that rapamycin induced cancer cell death either by inducing apoptosis or autophagy; in that study, rapamycin induced a decrease in cyclin D expression, which led to an increase in p27 and eventually to late G1/S cell-cycle blockage. As a “master-switch” between catabolic and anabolic metabolism, the mammalian target of rapamycin (mTOR), a kinase, is part of the P13K/AKT/mTOR pathway of cancer cell metabolism and rapamycin is an established mTOR inhibitor; as such, rapamycin-mediated metabolic effects and blockage of cell-cycle progression have been shown to slow down the proliferation of several human cancer cell lines in a dose-dependent manner (Faivre et al., 2006).

Previous study also supports the role of collagen alterations induced by antifibrotic agents. Halofuginone-coated urethral catheters prevented periurethral spongiosclerosis, which formed via an altered ratio of collagen type I relative to type III, in a rat model of urethral injury (Krane et al., 2011). Fibrotic diseases are characterized by abnormal accumulation of extracellular matrix proteins and the resulting fibrotic lesions disrupt normal tissue architecture, contributing to organ failure; the multifunctional protein that is the mammalian target of rapamycin (mTOR) regulates cell growth, proliferation and differentiation and was shown to positively regulate collagen type I production via a phosphatidylinositol 3-kinase-independent pathway (Shegogue & Trojanowski, 2004). Rapamycin also inhibited platelet-derived

growth factor-induced collagen synthesis in rat mesangial cells, both inhibiting cell proliferation and collagen synthesis (Kim et al., 2004). Results of these studies strongly suggest that if rapamycin can be a critical mediator of cell production and collagen overproduction, it can be a viable target for drug or gene therapies.

In the present study, our H&E staining and Sirius red staining results confirmed that there was less fibrosis and lower collagen content of the two groups treated with rapamycin and fewer fibroblasts in the two rapamycin groups. Thus, our histopathological findings are consistent with the hypothesis that rapamycin inhibits the proliferation of fibroblasts and reduces collagen expression, as proposed by Korfhagen et al. (2009) and Mehrad et al. (2009).

The purpose of this pilot study was to investigate the efficacy of rapamycin in reducing urethral stricture. We compared two dose rates (1 mg/day vs. 0.1 mg/day) based on the dose rates of rapamycin used for immunosuppression during human renal transplantation and the fact that rabbits are about 10-fold more tolerant of rapamycin than humans. We observed no adverse effects on the general state of the rabbits. However, we did note unhealed urethral mucosa in 5 rabbits of the R_H group. This indicates that 1 mg/day of rapamycin in our rabbit model may have adversely affected the post-traumatic healing process of the urethral epithelium, possibly due to the powerful inhibitory effect of rapamycin on fibroblast proliferation (Kahn et al., 2005). We suggest that future studies further examine the dose-dependence of rapamycin on the amelioration of urethral stricture.

Conclusions

In conclusion, our results indicate that rapamycin significantly reduced urethral stricture and that this physiological effect may be mediated by its inhibition of the proliferation of urethral fibroblasts and/or its reduction of collagen accumulation. We suggest that future studies of the effect of rapamycin on urethral stricture include more animals, provide more detailed examination of the dose-dependence of rapamycin, and employ longer follow-up periods.

Acknowledgments

We appreciate the help of Kang-min WANG from Department of Pathology of the Second Affiliated Hospital of Xi'an Jiaotong University in the pathological analysis and Nan ZHANG from Peiking University in the statistical analysis.

Authors' Contributions

Participated in research design: Chong, Fu and Li.

Conducted experiments: Chong and Fu.

Contributed new reagents or analytic tools: Li.

Performed data analysis: H. Zhang, P. Zhang and Gan.

Wrote or contributed to the writing of the manuscript: Chong, Fu and Li.

Other: Wang and Li acquired funding for the research.

References

- Andersen HL, Duch BU, Gregersen H, Nielsen JB, Ørskov H (2003) The effect of the somatostatin analogue lanreotide on the prevention of urethral strictures in a rabbit model. *Urol Res* **31**: 25-31.
- Andersen HL, Duch BU, Nielsen JB, Joergensen B, Ledet T (2003) An experimental model for stricture studies in the anterior urethra of the male rabbit. *Urol Res* **31**: 363-367.
- Biecker E, De Gottardi A, Neef M, Unternährer M, Schneider V, Ledermann M, Sägesser H, Shaw S, Reichen J (2005) Long-term treatment of bile duct-ligated rats with rapamycin (Sirolimus) significantly attenuates liver fibrosis: analysis of the underlying mechanisms. *J Pharmacol Exp Ther* **313**: 952-961.
- Branch MP, Hebda PA, Dohar JE (2004) Topical sirolimus for prevention of subglottic stenosis in a rabbit model. *Otolaryngology: Head & Neck Surgery* **131**: 270.
- Brandes SB (2008) Epidemiology, Etiology, Histology, Classification, and Economic Impact of Urethral Stricture Disease, in *Urethral Reconstructive Surgery* (Brandes SB ed) pp 53-81, Humana Press, Totowa.
- Damião MJ, Bertocchi AP, Monteiro RM, Gonçalves GM, Cenedeze MA, Feitoza CQ, Marques GD, Giannocco G, Mazzali M, Teixeira VP, Dos Reis MA, Pacheco-Silva A, Câmara NO (2007) The effects of rapamycin in the progression of renal fibrosis. *Transplant Proc* **39**: 457-459.
- Faivre S, Kroemer G, Raymond E (2006) Current development of mTOR inhibitors

- as anticancer agents. *Nature Reviews* **5**: 671-688.
- Gao XM, Wong G, Wang B, Kiriazis H, Moore XL, Su YD, Dart A, Du XJ (2006)
Inhibition of mTOR reduces chronic pressure-overload cardiac hypertrophy and fibrosis. *J Hypertens* **24**: 1663-1670.
- Greenwell TJ, Castle C, Andrich DE, MacDonald JT, Nicol DL, Mundy AR (2004)
Repeat urethrotomy and dilation for the treatment of urethral stricture are neither clinically effective nor cost-effective. *J Urol* **172**: 275-277.
- Jaidane M, Ali-El-Dein B, Ounaies A, Hafez AT, Mohsen T, Bazeed M (2003) The use of halofuginone in limiting urethral stricture formation and recurrence: an experimental study in rabbits. *J Urol* **170**: 2049-2052.
- Kahn D, Spearman CW, Mall A, Shepherd E, Engelbrecht G, Lotz Z, Tyler M (2005)
Effect of rapamycin on the healing of the bile duct. *Transplant Proc* **37**: 832-833.
- Khera M, Boone TB, Smith CP (2004) Botulinum toxin type A: a novel approach to the treatment of recurrent urethral strictures. *J Urol* **172**: 574-575.
- Kim MS, Park J, Ha H, Kim Ys, Kang SW, Jeong HJ, Kang DH, Yang CW (2004)
Rapamycin inhibits platelet-derived growth factor-induced collagen, but not fibronectin, synthesis in rat mesangial cells. *Yonsei Medical Journal* **45**: 1121-1126.
- Korfhagen TR, Le Cras TD, Davidson CR, Schmidt SM, Ikegami M, Whitsett JA, Hardie WD (2009) Rapamycin prevents transforming growth factor-alpha induced pulmonary fibrosis. *Am J of Respir Cell Mol Biol* **41**: 562-572.
- Krane LS, Gorbachinsky I, Sirintrapun J, Yoo JJ, Atala A, Hodges SJ (2011)

- Halofuginone-coated urethral catheters prevent periurethral spongiofibrosis in a rat model of urethral injury. *J Endourol* **25**: 107-112.
- Langston JP, Robson CH, Rice KR, Evans LA, Morey AF (2009) Synchronous urethral stricture reconstruction via 1-stage ascending approach: rationale and results. *J Urol* **181**: 2161-2165.
- Lumen N, Hoebeke P, De Troyer B, Oosterlinck W (2009) Aetiology of urethral stricture disease: an analysis of 268 patients. *Eur Urol Suppl* **8**: 158.
- Mazdak H, Meshki I, Ghassami F (2007) Effect of mitomycin C on anterior urethral stricture recurrence after internal urethrotomy. *Eur Urol* **51**: 1089-1092.
- Mehrad B, Burdick MD, Strieter RM (2009) Fibrocyte CXCR4 regulation as a therapeutic target in pulmonary fibrosis. *Int J Biochem Cell Biol* **41**: 1708-1718.
- Meria P, Anidjar M, Brouland JP, Teillac P, Le Duc A, Berthon P, Cussenot O (1999) An experimental model of bulbar urethral stricture in rabbits using endoscopic radiofrequency coagulation. *Urology* **53**: 1054-1057.
- Moses JW, Leon MB, Popma JJ, Fitzgerald PJ, Holmes DR, O'Shaughnessy C, Caputo RP, Kereiakes DJ, Williams DO, Teirstein PS, Jaeger JL, Kuntz RE; SIRIUS Investigators (2003) Sirolimus-eluting stents versus standard stents in patients with stenosis in a native coronary artery. *N Engl J Med* **349**: 1315-1323.
- Nagler A, Gofrit O, Ohana M, Pode D, Genina O, Pines M (2000) The effect of halofuginone, an inhibitor of collagen type I synthesis, on urethral stricture formation: in vivo and in vitro study in a rat model. *J Urol* **164**: 1776-1780.

- Sciarra A, Salciccia S, Albanesi L, Cardi A, D'Eramo G, Di Silverio F (2005) Use of cyclooxygenase-2 inhibitor for prevention of urethral strictures secondary to transurethral resection of the prostate. *Urology* **66**: 1218-1222.
- Shegogue D, Trojanowska M (2004) Mammalian target of rapamycin positively regulates collagen type I production via a phosphatidylinositol 3-kinase-independent pathway. *J Biol Chem* **279**: 23166-23175.
- Waxman SW, Morey AF (2006) Management of urethral strictures. *Lancet* **367**: 1397-1380.
- Wu MJ, Wen MC, Chiu YT, Chiou YY, Shu KH, Tang MJ (2006) Rapamycin attenuates unilateral ureteral obstruction-induced renal fibrosis. *Kidney Int* **69**: 2029-2036.

Figure legends

Fig. 1 Representative retrograde urethrograms of rabbits in the R_H (A), R_L (B), DMSO (C), and NL (D) groups. Note the significant stricture formation in C and D, but less stricture in A and B (red arrows).

Fig.2 Representative urethroscopies of rabbits in the R_H (A), R_L (B), DMSO (C), and NL (D) groups. Note the lack of stricture in A and B, the unhealed urethral mucosa in A, and the significant stricture formation in C and D, which blocked passage of the F13 urethroscope (red arrows).

Fig.3 Representative H&E staining of the stricture sites of rabbits in the R_H (A), R_L (B), DMSO (C), and NL (D) groups (× 400). Note the presence of fibrosis under the urethral epithelium, few affected muscle cells, and few cells in the fibrous tissue in A and B, and wide fibrous tissue formation under the urethral epithelium with abundant cells in C and D (red arrows).

Fig.4 Representative microphotographs of urethral sections at the stricture sites stained by Sirius red for rabbits in the R_H (A), R_L (B), DMSO (C), and NL (D) groups (×40). Note the light red staining in A and B (indicating low amounts of collagen) and the crimson-red staining in C and D (indicating abundant collagen).

Table 1. Urethral lumen restriction of rabbits treated with high dose rapamycin (R_H), low dose rapamycin (R_L), DMSO, or normal saline (NS).

Group	n	Lumen reduction (%)	Range (%)
R_H	12	36.5 ± 21.5	12.9-79.3%
R_L	12	56.6 ± 17.4	13.8-77.3%
DMSO	6	$69.1 \pm 8.81^*$	55.6-81.6%
NS	7	$82.9 \pm 17.2^{*\dagger}$	55.6-96.5%

* $p < 0.05$ compared to the R_H group after Bonferroni adjustment, $\dagger p < 0.05$ comparing to R_L group after Bonferroni adjustment.

Figure 1A

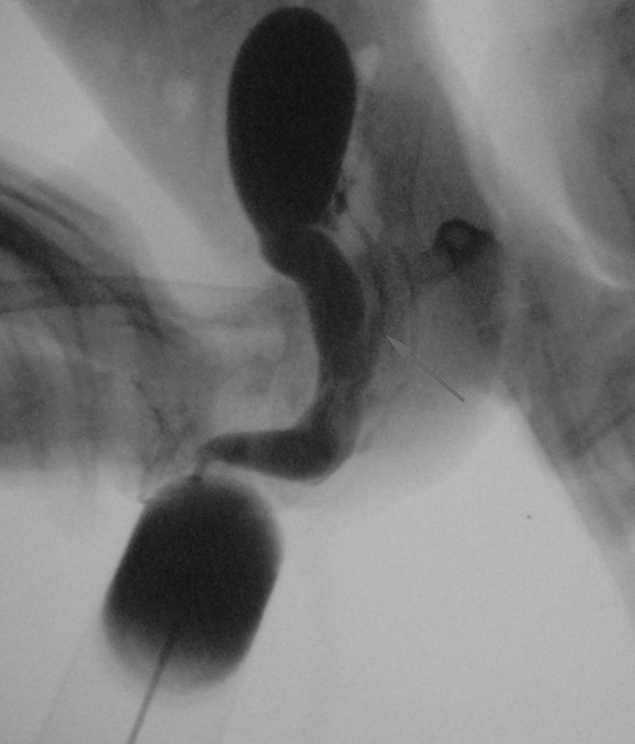


Figure 1B

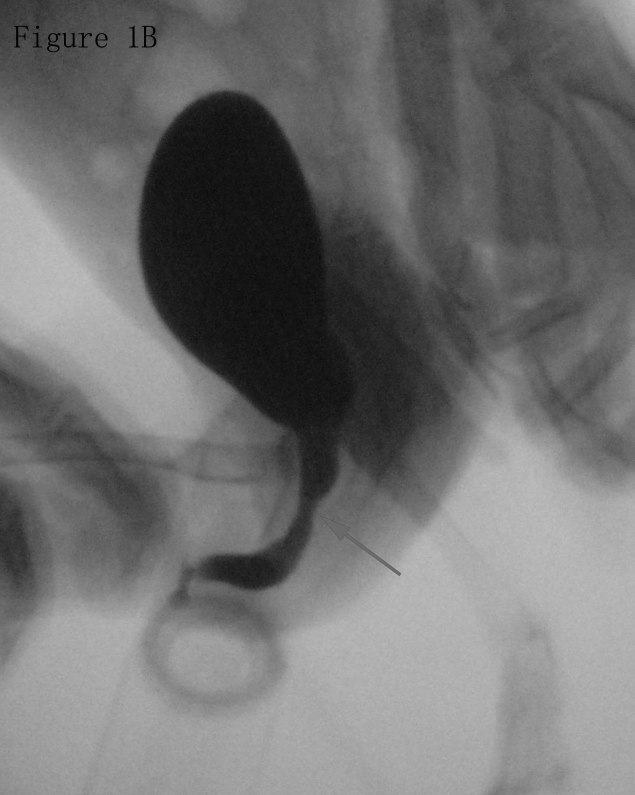


Figure 1C

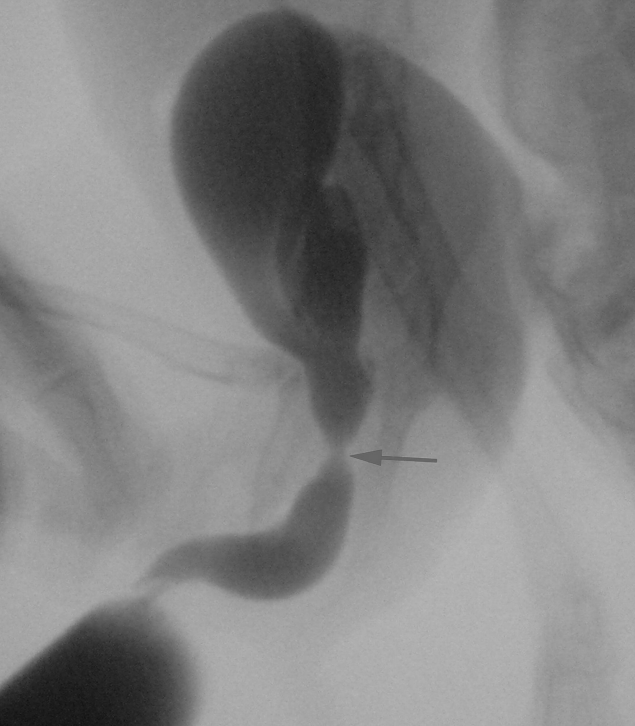

Figure 1D

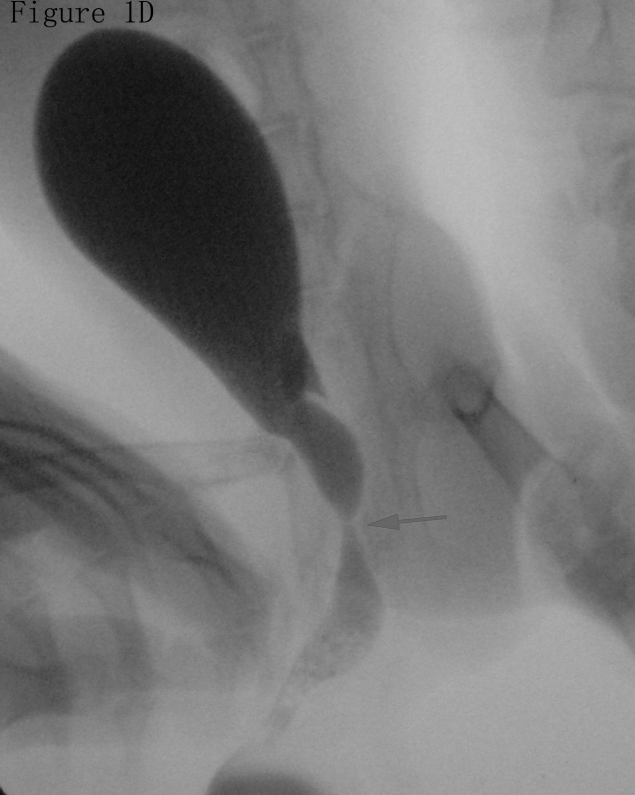

Figure 2A

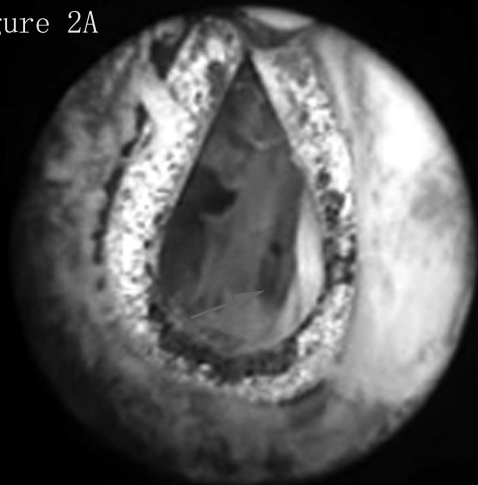


Figure 2B

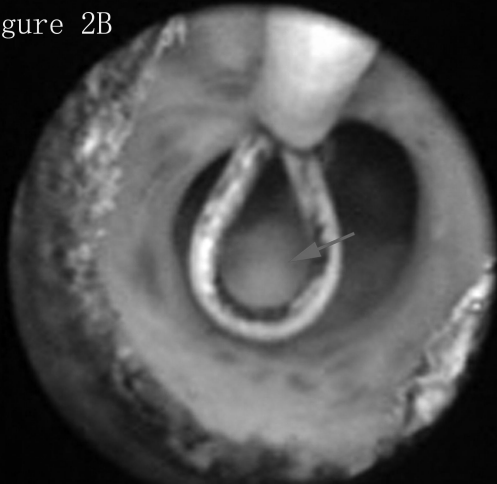

Figure 2C

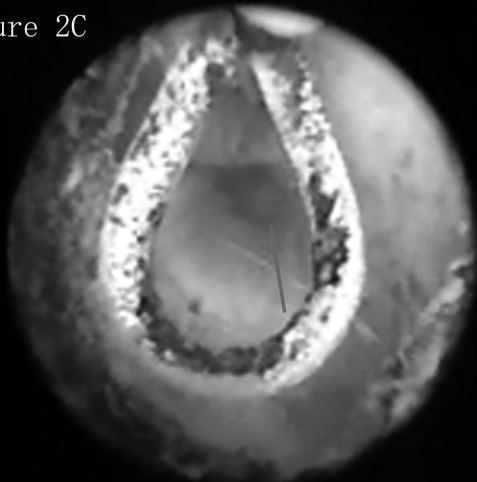


Figure 2D

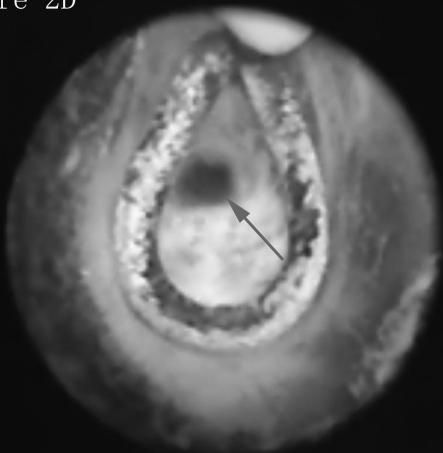


Figure 3A

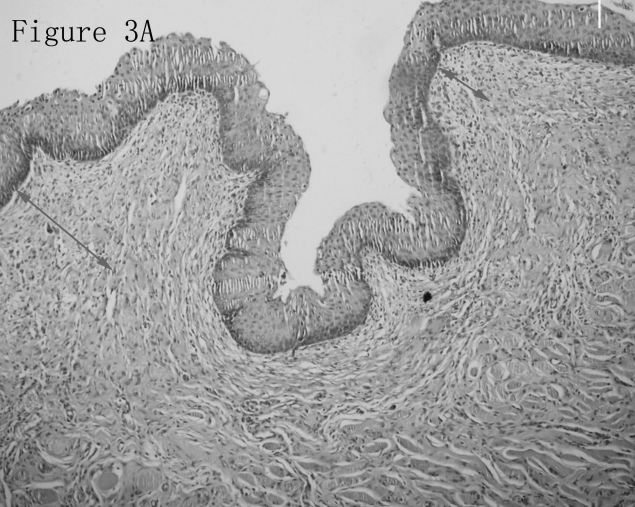


Figure 3B

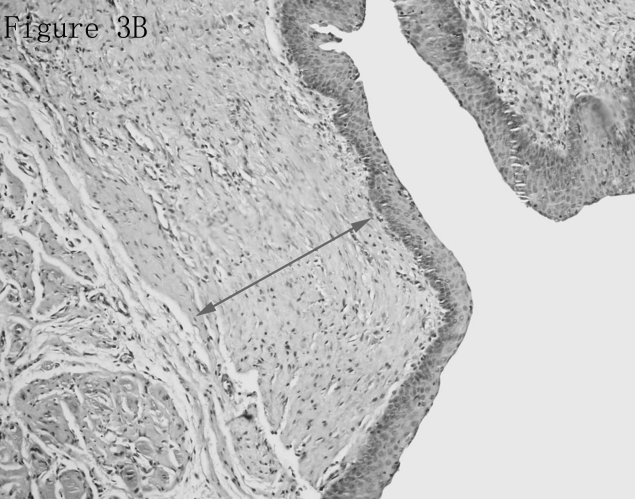


Figure 3C

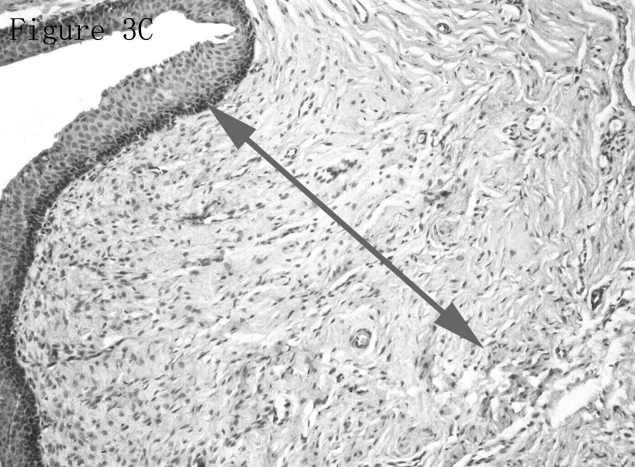

Figure 3D

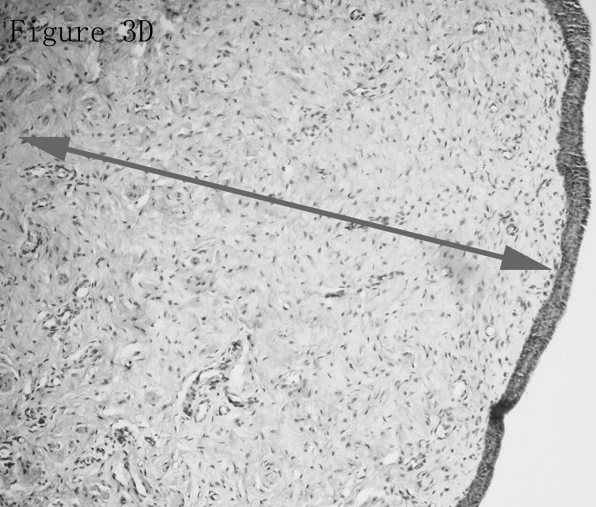


Figure 4A

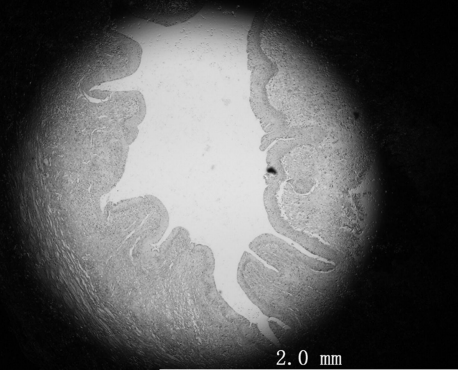
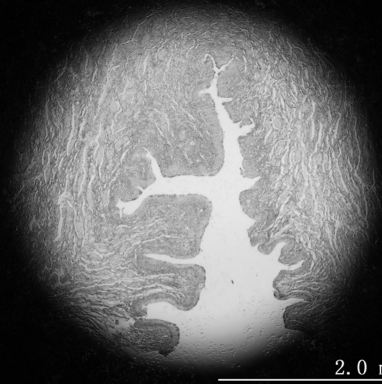


Figure 4B



2.0 mm

Figure 4C

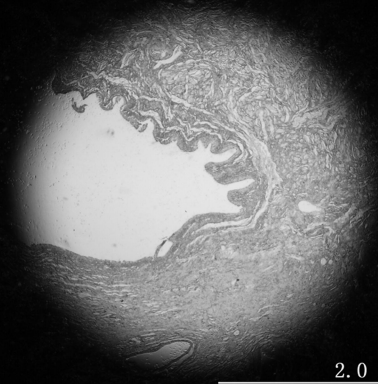


Figure 4D

