

Roles of Endogenous Prostaglandins and Cyclooxygenase Isozymes in Healing of Indomethacin-Induced Small Intestinal Lesions in Rats

Ryo Hatazawa, Ryoko Ohno, Mayu Tanigami, Akiko Tanaka
and Koji Takeuchi

Department of Pharmacology and Experimental Therapeutics
Kyoto Pharmaceutical University
Misasagi, Yamashina, Kyoto, 607-8414, Japan

Running title: Prostaglandins and Intestinal Ulcer Healing

Address correspondence to: Dr. Koji Takeuchi, PhD.

Department of Pharmacology and Experimental Therapeutics

Kyoto Pharmaceutical University

Misasagi, Yamashina, Kyoto 607-8414, Japan

Tel: +81-075-595-4679; Fax: +81-075-595-4774

E-mail: takeuchi@mb.kyoto-phu.ac.jp

Document statistics: text ----- pages (page 3-page 23)
 figures ----- 12 figures
 tables ----- 0 tables
 references ----- 42 references (page 24-page 29)
Number of words: abstract ----- 250
 introduction ---- ----- 406
 discussion ----- 2039

Recommended section: Gastrointestinal, Hepatic, Pulmonary, & Renal

Abbreviations:

Nonsteroidal antiinflammatory drugs ----- NSAIDs
prostaglandins ----- PGs
cyclooxygenase ----- COX
prostaglandin E₂ ----- PGE₂
prostacyclin E receptor ----- EP receptor
reversed transcriptional polymerase reaction ----- RT-PCR

Abstract

The role of prostaglandins (PGs)/cyclooxygenase (COX) in the healing of indomethacin-induced small intestinal ulcers was examined in rats. Animals were given indomethacin (10 mg/kg, s.c.) and killed 1, 2, 3, 5, and 7 days later. Indomethacin (2 mg/kg), SC-560 (COX-1 inhibitor: 3 mg/kg) and rofecoxib (COX-2 inhibitor: 3 mg/kg) were given p.o. once daily for 6 days, during the first 3 days or last 3 days of the experimental period. All COX inhibitors given for 6 days significantly impaired the healing of these ulcers. Healing was also impaired by rofecoxib given for the first 3 days or by SC-560 given for the last 3 days. The expression of COX-2 mRNA in the intestine was up-regulated after ulceration, persisting for 3 days and dissipating thereafter. Mucosal PGE₂ contents decreased within 3 hr after ulceration, recovered 24 hr later, and increased above normal 1~3 days later. The PGE₂ content at 4 days after ulceration was decreased by rofecoxib but not SC-560 while that at 7 days was suppressed by SC-560 but not rofecoxib. Vascular content in the ulcerated mucosa decreased when the healing was impaired by COX inhibitors. The deleterious effect of indomethacin on healing was mimicked by an EP4 antagonist and reversed by co-administration of PGE₂ as well as an EP4 agonist. In conclusion, endogenous PGs play a role in the healing of intestinal ulcers through EP4 receptors, yet the COX isozyme involved differs depending on the stage of healing, COX-2 in the early stage and COX-1 in the late stage.

Introduction

Nonsteroidal antiinflammatory drugs (NSAIDs), the most frequently prescribed drugs world wide, have been used in patients as analgesic and anti-nociception as well as anti-inflammation, but the major limitation to their use is gastrointestinal side effects. These drugs not only damage the gastrointestinal mucosa but impair the healing of pre-existing ulcers as well [Wang et al., 1989; Levi et al., 1990; Schmassmann et al, 1995; Wallace et al., 2000; Tanaka et al., 2002a]. These effects of NSAIDs are considered to be brought about by a deficiency of prostaglandins (PGs) due to inhibition of cyclooxygenase (COX). COX exists in two isoforms, COX-1 expressed constitutively in various tissues, including the stomach and intestine, and COX-2 expressed in few tissues but rapidly induced in response to growth factors and cytokines [Feng et al., 1993; Kargman et al., 1993; O'Neill et al., 1993; Singer et al., 1998].

It is known that the deleterious effect of NSAIDs on healing is shared by selective COX-2 inhibitors [Mizuno et al., 1997; Ukawa et al., 1998; Shigeta et al., 1998; Halter et al., 2001; Araki et al., 2003], suggesting an important role for COX-2/PGs in the healing of pre-existing ulcers. Mizuno et al. [1997] first demonstrated that both COX-2 mRNA and protein were strongly expressed in stomachs in which ulcers had been induced. More recently, Jones et al. [1999] reported that both COX-1 and COX-2 are important for the regulation of angiogenesis, and that selective COX-2 inhibitors and nonselective NSAIDs inhibit angiogenesis through direct effects on endothelial cells. However, since the repair of epithelial damage after irradiation was retarded in COX-1 knockout mice [Blikslager et al.,2002], it is possible that the mechanism of ulcer healing is regulated by endogenous PGs produced not only by COX-2 but also by COX-1 as well. Unfortunately, most of the above findings were obtained in the stomach but not the

small intestine. Thus, the relative role of COX-1 and COX-2 in the healing of the intestinal lesions remains unknown.

In the present study, we examined the roles of COX/PGs in the healing of indomethacin-induced intestinal lesions in rats, using selective COX-1 and COX-2 inhibitors. Since it has been recently shown that PGE₂ enhanced the healing of gastric ulcers through the activation of EP4 receptors [Tanaka et al., 2005], we also examined the effect of various EP agonists and antagonist on the healing of intestinal lesions and investigated which EP receptor subtype is involved in the healing process.

Materials and Methods

Animals

Male Sprague Dawley rats (220~260 g, Nippon Charles River, Shizuoka, Japan) were used. Studies were carried out using 4~9 animals without fasting in a conscious state, unless otherwise specified. All experimental procedures described here were approved by the Experimental Animal Research Committee of the Kyoto Pharmaceutical University.

Induction of Small Intestinal Ulceration

The animals were administered indomethacin (10 mg/kg, s.c.) and killed 1, 2, 3, 5, and 7 days later. Various COX inhibitors, such as indomethacin (a nonselective COX inhibitor: 2 mg/kg), SC-560 (a selective COX-1 inhibitor: 3 mg/kg), and rofecoxib (a selective COX-2 inhibitor: 3 mg/kg), were given p.o. once daily for the first 3 days, for the late 3 days or for 6 days, starting 1 day after the treatment with indomethacin (10 mg/kg). In some cases, both SC-560 and rofecoxib were given together. Control animals were given the vehicle (hydroxy propyl cellulose solution) p.o. once daily for 6 days, starting 1 day after the treatment with indomethacin (10 mg/kg). In addition, the animals treated with various COX inhibitors for the first 3 days or the last 3 days were given the vehicle p.o. once daily for the rest of the experimental period. In another experiment, the effect of the EP4 antagonist AE3-208 [Amano et al., 2003] on the healing of indomethacin-induced intestinal lesions was examined. AE3-208 (3 mg/kg) was given i.p. twice daily for 6 days after ulceration caused by the administration of indomethacin (10 mg/kg). The effects of various EP agonists on the healing of the intestinal lesions were also examined in the presence of indomethacin (2 mg/kg/day). PGE₂ (1 mg/kg), 17-phenyl PGE₂ (EP1 agonist: 1 mg/kg), butaprost (EP2 agonist: 3

mg/kg), NT-012 (EP3 agonist: 3 mg/kg) or AE1-329 (EP4 agonist: 0.1 mg/kg) was given i.p. twice daily for 6 days, starting 1 day after induction of the intestinal lesions, while indomethacin (2 mg/kg) was given p.o. once daily for 6 days. The doses of the EP agonists were selected according to our previous studies [Takeuchi et al., 1997; Araki et al., 2000; Aoi et al., 2004]. Control animals were given saline i.p. twice daily for 6 days of the experimental period. To reveal the damage in each case, 1 ml of Evans blue (w/w) was injected i.v. 30 min before sacrifice. Animals were killed under deep ether anesthesia, and the small intestines were excised and treated with 2% formalin for fixation of the tissue walls. Then, they were opened along the anti-mesenteric attachment and examined for damage under a dissecting microscope with square grids (x10). The area (mm²) of macroscopically visible lesions was measured, summed per small intestine, and used as an ulcer score. The person measuring the lesions did not know the treatments given to the animals.

In some cases, the intestinal mucosa was examined histologically on various days (1, 3, 5 and 7) after the induction of intestinal ulcers, with or without the repeated administration of indomethacin (2 mg/kg), SC-560 (3 mg/kg) or rofecoxib (3 mg/kg). The animals were killed under deep ether anesthesia, and the small intestines were excised. The tissue samples were then immersed in 10% neutralized formalin, embedded in paraffin, sectioned at 5 μ m, and stained with hematoxylin and eosin (H&E) or Azan. Both macro- and micro-scopical observations were compared between normal rats giving saline in place of indomethacin (10 mg/kg), control rats given indomethacin (10 mg/kg) to produce intestinal ulcers, and the animals treated with various COX inhibitors after ulceration.

Determination of Mucosal PGE₂ Content

Levels of PGE₂ in the small intestinal mucosa were measured on various days

after the p.o. administration of indomethacin (10 mg/kg). The animals were killed under deep ether anesthesia at various time points (3 hr or 1, 3, 5 or 7 days) after the administration of indomethacin, and small intestinal tissue was isolated, weighed, and placed in a tube containing 100% ethanol plus 0.1 M indomethacin [Tanaka et al., 2002a]. Then, the tissue was homogenized with a polytron homogenizer (IKA, Tokyo, Japan) and centrifuged at 10,000 rpm for 10 min at 4°C. After the supernatant of each sample had been evaporated with N₂ gas, the residue was resolved in assay buffer and used to determine the concentration of PGE₂. The concentration of PGE₂ was measured using a PGE₂ enzyme immunoassay (EIA) kit (Amersham Pharmacia Biotech, UK). In separate experiments, the effect of indomethacin (2 mg/kg), SC-560 (3 mg/kg) or rofecoxib (3 mg/kg) on the concentration of PGE₂ on day 3 or 6 after ulceration was examined. Each drug was given p.o. once daily for the first or last 3 days, starting 1 day or 4 day after ulceration, respectively.

Analyses of COX-2 mRNA Expression by RT-PCR

The animals were killed under deep ether anesthesia on days 1, 2, 3, 5 and 7 after the administration of indomethacin (10 mg/kg, s.c.), and the small intestines were removed, frozen in liquid nitrogen, and stored at -80°C prior to use. Tissue samples were pooled from 2~3 rats for extraction of total RNA, which was prepared by a single-step acid phenol-chloroform extraction procedure using TRIZOLE (GIBCO BRL, Gaithersburg, MD). Total RNA primed by a random hexadeoxy ribonucleotide was reverse-transcribed with the SUPERScript preamplification system (GIBCO BRL). The sequences of sense and antisense primers for rat COX-2 were 5'-TGATGACTGCCAACTCCCATG-3' and 5'-AATGTTGAAGGTGTCCGGCAGC-3', respectively, giving rise to a 702-bp PCR product [Tso et al., 1985; Feng et al., 1993]. For rat glyceraldehyde-3-phosphate dehydrogenase (G3PDH), a constitutively expressed gene,

the sequence was 5'-GAACGGGAAGCTCACTGGCATGGC-3' for the sense primer and 5'-TGAGGTCC ACCACCCTGTTGCTG-3' for the antisense primer, giving rise to a 310-bp PCR product [Feng et al., 1993]. An aliquot of the RT reaction product served as a template in 35 cycles of PCR with 1 min of denaturation at 94°C, 0.5 min of annealing at 58°C and 1 min of extension at 72°C on a thermal cycler. A portion of the PCR mixture was electrophoresed in 1.8% agarose gel in TAE buffer (Tris buffer 40 mM, EDTA 2 mM and acetic acid 20 mM; pH 8.1), and the gel was stained with ethidium bromide and photographed. The sequence of the PCR product was analyzed using the BLAST program (NCBI).

Determination of Vascular Content based on Carmine Incorporation

Vascular content was assessed based on the formation of vascular casts incorporating carmine, using a modification of the method of Kimura et al. [1986]. The animals were given indomethacin (10 mg/kg, s.c.) for the induction of intestinal lesions, and killed 4 or 7 days later. Various COX inhibitors were given once daily for the first 3 days or the last 3 days. Under ether anesthesia, a cast was formed by the i.v. injection of 5% carmine red in 10% gelatin at 37°C in a volume of 1 ml/100 g body weight. The carcasses were chilled for 3 hr at 4°C, and the damaged mucosa was dissected. After a thorough rinsing with phosphate buffer (pH 7.4), the tissue was weighed, minced with scissors, and dissolved in 3.5 N NaOH (5 ml/1 g tissue) at 37°C. The dye solution was then neutralized by adding 3 N HCl, centrifuged at 3000 r.p.m. for 10 min at 4°C, and filtrated using a miliporefilter (0.45 µm). The dye content of 200 µl samples was assayed spectrophotometrically using a 96-well plate reader (Hitachi, Mito, Japan) at 529 nm. The results were expressed as mg dye content per g tissue.

Preparation of Drugs

The drugs used were indomethacin (Sigma Chemicals, St. Louis, MO), SC-560

(Cayman Chemical, Ann Arbor, MI), rofecoxib (synthesized in our laboratory), PGE₂ and 16,16-dimethyl PGE₂ (Funakoshi, Tokyo, Japan), 17-phenyl PGE₂ (Nacalai tesque, Kyoto, Japan), butaprost, NT-012, AE1-329 and AE3-208 (Ono Pharmaceutical Co. Ltd, Osaka, Japan) and carmine red (Wako, Osaka, Japan). All COX inhibitors were suspended in a hydroxy propyl cellulose (HPC) solution (Wako). PGE₂ and other EP receptor ligands were dissolved in absolute ethanol and then diluted with saline to the desired concentration. All drugs were prepared immediately before use and administered p.o., s.c. or i.p. in a volume of 0.5 ml/100 g body weight or i.v. in a volume of 0.1 ml/100 g body weight.

Statistics

Data are presented as the mean±SE of 4 to 9 rats per group. Statistical analyses were performed using the two-tailed Dunnett's multiple comparison test, and values of P<0.05 were considered significant.

Results

Development and Healing of Indomethacin-Induced Intestinal Ulcers

Subcutaneous administration of indomethacin (10 mg/kg) in normally fed rats produced multiple hemorrhagic lesions in the small intestine, mainly in the jejunum and ileum, the ulcer score at 24 hr being $226.3 \pm 18.2 \text{ mm}^2$. The ulcers healed quite rapidly within 7 days, and the ulcer score on days 3 and 7 was reduced to about 41.6% and 27.8%, respectively, of the initial score observed 24 hr after indomethacin treatment (**Figure 1**). Histological observation showed that the damage on day 1 was deep in the mucosa, where the epithelial cells were totally denuded and severe edema was observed in the submucosa (**Figure 2B**). Consistent with the macroscopical observation, the area of damage became smaller with time (**Figures 2C~2F**), and the damaged portion on day 7 was surrounded by granulation tissue and covered with a newly formed thin epithelium (**Figure 2F**).

Gene expression of COX Isozymes and PGE₂ Content in Intestinal Mucosa After Administration of Indomethacin

Indomethacin (10 mg/kg, p.o.) markedly decreased the mucosal PGE₂ content of the small intestine from $7.8 \pm 1.3 \text{ ng/g}$ tissue to less than 1.3 ng/g tissue within 3 hr. However, the level of PGE₂ was restored 24 hr after the administration of indomethacin, and even increased significantly above normal on day 2-4, before gradually returning to normal on day 7 (**Figure 3**). The peak value was $35.8 \pm 8.1 \text{ ng/g}$ tissue, about 4 times greater than normal levels.

Consistent with our previous paper [Tanaka et al., 2002a], indomethacin at an ulcerogenic dose (10 mg/kg) up-regulated the expression of COX-2 mRNA in the

intestinal mucosa when examined 24 hr after the administration, although the expression was not detectable in the normal rat intestine (**Figure 4**). The expression of COX-2 was observed in the mucosa during the first 3 days, with a peak response on day 2, and gradually faded away thereafter. By contrast, both G3PDH and COX-1 mRNAs were observed in the intestinal mucosa before and after the administration of indomethacin.

Effects of Various COX Inhibitors on Healing of Intestinal Lesions and Mucosal PGE₂ Content

As shown in **Figure 1**, the intestinal ulcers produced by indomethacin (10 mg/kg, p.o.) healed with time, and the area of lesions was 23.4 ± 5.2 mm² on day 7 after the administration. The healing was significantly impaired by indomethacin at a low dose (2 mg/kg, p.o.), given once daily for 6 days starting 1 day after ulceration, and the area of ulcers was 7 times greater than that in the control, the value being 146.1 ± 42.3 mm² (**Figure 5**). The healing was also impaired when the animals were given SC-560 (3 mg/kg, p.o.) or rofecoxib (3 mg/kg, p.o.) once daily for 6 days. In addition, the combined administration of SC-560 and rofecoxib also markedly delayed the healing of intestinal ulcers, the area of lesions on day 7 being equivalent to that observed in the animals given indomethacin (2 mg/kg). Neither indomethacin (2 mg/kg), SC-560 (3 mg/kg) nor rofecoxib (3 mg/kg) given p.o. once daily for 6 days caused by itself any damage in the gastrointestinal mucosa (data not shown).

Since the mucosal PGE₂ content showed a biphasic change, an increase for the first 3 days followed by a return to the normal level (see Figure 3), and since COX-2 expression was markedly up-regulated for the first 3 days of ulceration (see Figure 4), it is possible that the COX isozyme responsible for the production of PGE₂ differs

depending on the stage of healing. Then, we examined the effect of COX inhibitors on the healing of the intestinal lesions at two different phases, the first 3 days (early phase) and the last 3 days (late phase).

The early phase: The area of intestinal lesions was reduced within 4 days to about half of that observed 24 hr after the administration of indomethacin (10 mg/kg, p.o.), the value being $82.6 \pm 15.8 \text{ mm}^2$. When the animals were given indomethacin (2 mg/kg, p.o.) once daily for the first 3 days after ulceration, the healing was impaired significantly, the value being $243.2 \pm 27.1 \text{ mm}^2$ (**Figure 6**). Daily administration of rofecoxib but not SC-560 (3 mg/kg, p.o.) for the first 3 days also significantly impaired the healing, the effect being almost the same as that of indomethacin. The healing was also significantly impaired by the combined administration of SC-560 and rofecoxib. The impaired healing caused by indomethacin was antagonized by dmPGE_2 (20 $\mu\text{g}/\text{kg}$, p.o.) given twice daily for 3 days, together with indomethacin. Consistent with the macroscopical observation, the lesions healed with newly formed epithelial cells on day 7 after ulceration (**Figure 7**). In contrast, the damage in the animals given indomethacin for the first 3 days was still deep in the mucosa, without granulation tissue in the surrounding area. DMPGE_2 given together with indomethacin, however, restored the healing of these ulcers as revealed by histological examination, and the denuded area was covered with newly epithelial cells. On the other hand, the level of mucosal PGE_2 on day 4 was significantly greater than normal (**Figure 8**). Indomethacin given for the first 3 days markedly reduced PGE_2 content to less than 5% of the control level. Likewise, a significant reduction in PGE_2 content was observed when rofecoxib but not SC-560 was given for the first 3 days. Certainly, the combined administration of SC-560 and rofecoxib markedly decreased the level of PGE_2 as effectively as did indomethacin.

The late phase: On day 7 after ulceration, the area of lesions became much smaller, the value being $25.3 \pm 11.6 \text{ mm}^2$, about 10% of that observed 24 hr after the administration of indomethacin (10 mg/kg) (**Figure 9**). When the animals were given various COX inhibitors once daily for the last 3 days, the healing of lesions was not affected by rofecoxib (3 mg/kg) alone but significantly impaired by either indomethacin (2 mg/kg), SC-560 (3 mg/kg) or SC-560 plus rofecoxib. The area of lesions in the latter three groups was roughly 150–200 mm^2 , about 10 times greater than that of the control, while in the rofecoxib-treated animals it was $28.4 \pm 3.8 \text{ mm}^2$, almost equivalent to that of control animals. Levels of mucosal PGE_2 on day 7 remained slightly higher than normal (**Figure 10**). Indomethacin (2 mg/kg) given for the last 3 days significantly decreased PGE_2 content to about 1/3 of that in the control. SC-560 (3 mg/kg) or SC-560 plus rofecoxib (3 mg/kg) also significantly reduced PGE_2 content, similar to indomethacin, while rofecoxib alone had no effect.

Effects of Various COX Inhibitors on Vascular Content

Effects of various COX inhibitors on vascular content were evaluated by measuring the amount of carmine incorporated in the vascular casts. The amount of carmine in the control group was $560.2 \pm 21.3 \text{ } \mu\text{g/g}$ tissue when determined 4 days after ulceration (**Figure 11A**). Both indomethacin (2 mg/kg) and rofecoxib (3 mg/kg), given for the first 3 days, significantly decreased the vascular content while SC-560 (3 mg/kg) had no effect. The inhibitory effect of indomethacin was significantly reversed by co-administration of dmPGE_2 (20 $\mu\text{g/kg}$) twice daily for 3 days, and the amount of carmine was totally restored to the control level. On histological examination by Azan staining, the tissue samples taken from control animals showed angiogenesis on day 4 after ulceration (data not shown). Indomethacin apparently suppressed angiogenesis

in the ulcerated mucosa while dmPGE₂ given together with indomethacin restored the angiogenic response. On the other hand, the amount of carmine on day 7 was less than that observed on day 4, the value being 135.7±14.2 µg/g tissue (**Figure 11B**). Indomethacin (2 mg/kg), given for the last 3 days, significantly decreased the content to 79.1±12.8 µg/g tissue, about half the control value. Likewise, the amount of carmine on day 7 was also significantly decreased by SC-560 (3 mg/kg) but not rofecoxib (3 mg/kg) given for the last 3 days.

Effects of Various EP Agonists and Antagonists on the Healing of Intestinal Lesions

The healing of intestinal lesions was found to be markedly impaired when the production of PGE₂ was suppressed by COX inhibitors. To further investigate which EP receptor is involved in the healing of these lesions, we examined the effect of various EP agonists on the impaired healing caused by indomethacin. As shown in **Figure 12A**, the healing was markedly impaired by indomethacin (2 mg/kg) given for 6 days, the area of lesions being 243.1±29.4 mm². This effect was significantly antagonized by either PGE₂ (1 mg/kg) or the EP4 agonist AE1-329 (0.1 mg/kg) given twice daily for 6 days, and the area of lesions in both cases decreased to the control value. Other prostanoids, such as 17-phenyl PGE₂ (EP1 agonist), butaprost (EP2 agonist) and NT-012 (EP3 agonist), did not affect the deleterious influence of indomethacin on healing.

To confirm the involvement of EP4 receptors in the healing of intestinal ulcers, we also examined the effect of AE3-208, the EP4 antagonist, on the healing in comparison with that of indomethacin. Daily administration of indomethacin (2 mg/kg, p.o.) for 6 days markedly impaired the healing of intestinal ulcers, the area of lesions on day 7 being 118.4±8.7 mm², about 5 times greater than that in the control

(Figure 12B). Likewise, AE3-208 (3 mg/kg, i.p.) given for 6 days also impaired the healing of ulcers, as effectively as indomethacin, and the area of lesions ($117.9 \pm 23.5 \text{ mm}^2$) was equivalent to that of the indomethacin-treated animals.

Discussion

It has been recognized for many years that NSAIDs hamper the spontaneous healing of peptic ulcers in experimental animals and humans while exogenously administered PGE₂ accelerates the healing process [Wang et al., 1989; Levi et al., 1990; Schmassmann et al., 1995; Ukawa et al., 1998]. Recent studies demonstrated an up-regulation of COX-2 expression, concomitant with an increase in the production of endogenous PGs, in the stomach after ulceration and suggested that COX-2/PGs play an important role in promoting the healing of gastric ulcers [Mizuno et al., 1997; Ukawa et al., 1998]. However, it remains unknown whether the same is true for healing of intestinal ulcers. The present study showed for the first time that PGs are actively involved in the healing of indomethacin-induced intestinal ulcers, but the COX isozyme responsible for the production of PGs differs depending on the stage of healing; COX-2 in the early stage and COX-1 in the late stage. In addition, it was suggested that the healing promoting action of PGs occurs through stimulation of the angiogenic response, probably mediated by the activation of EP4 receptors [Tanaka et al., 2005].

First, we confirmed that indomethacin at a dose of 10 mg/kg decreased mucosal PGE₂ content within 3 hr and caused severe hemorrhagic lesions in the small intestine, mainly in the jejunum and ileum, within 24 hr. Consistent with a previous study dealing with the healing of gastric lesions induced by necrotizing agents [Takeuchi et al., 1994], these lesions healed rapidly and were partially re-epithelialized within 7 days with granulation in the damaged portion. Indomethacin at the ulcerogenic dose up-regulated COX-2 expression in the intestinal mucosa, with a peak reached 2 days after the administration, and the PGE₂ content showed a 4-5 fold increase over the control level, followed by a gradual return to normal. These results suggested an

important role for COX-2/PGE₂ in healing of intestinal ulcers, similar to that of gastric ulcers. Indeed, Mizuno et al. [1997] reported that induction of ulcers in the stomach was followed by potent expression of both COX-2 mRNA and protein, and the inhibition of PG production by the selective COX-2 inhibitor delayed the healing of gastric ulcers. The up-regulation of COX-2 expression was observed even in stomachs acutely damaged with 0.2 N HCl or ischemia-reperfusion [Sawaoka et al., 1997; Kishimoto et al., 1997]. We also found in this study that the healing of intestinal ulcers was markedly impaired by indomethacin as well as rofecoxib given for 6 days after ulceration was induced, confirming the involvement of COX-2/PGs in the healing process. Interestingly, healing was similarly impaired when the animals were given SC-560, a selective COX-1 inhibitor. These results suggest that COX-1/PGs are also involved in the healing of intestinal ulcers, in addition to COX-2/PGs. Brzozowski et al. (2001) showed that the selective COX-1 inhibitor resveratrol significantly delayed the healing of acetic acid-induced gastric ulcers in rats. Blikslager et al. (2002) also reported that the repair of intestinal epithelial damage after irradiation was significantly retarded in COX-1 knockout mice.

As shown in the present study, the up-regulation of COX-2 expression was observed during the early stage of the healing process, up to 3 days after ulceration was induced. Then, we examined the effect of selective COX inhibitors on the healing of intestinal ulcers by administering these drugs for the first 3 days or the last 3 days. As expected, the healing was impaired by both indomethacin and rofecoxib but not SC-560 given for the initial 3 days while it was delayed by both indomethacin and SC-560 but not rofecoxib given for the final 3 days. Certainly, the combined administration of SC-560 plus rofecoxib impaired the healing, similar to indomethacin, irrespective of whether they were given for the first or last 3 days. These results clearly indicate that

endogenous PGs are actively involved in the healing of intestinal ulcers, yet the COX isozyme responsible for the production of PGs differs depending on the stage of the healing process; COX-2 in the early stage and COX-1 in the late stage. This idea was supported by the findings that the increased production of PGE₂ on day 3 after ulceration was significantly inhibited by rofecoxib but not SC-560 whereas the PGE₂ content on day 7 was decreased by SC-560 but not rofecoxib. Although the expression of COX-1 remained unchanged throughout the experimental period, it was observed that SC-560, a selective COX-1 inhibitor, delayed healing in the late phase but not the early phase. In the early phase of healing PGE₂ production is mainly governed by COX-2 activity because of the up-regulation of COX-2, while in the late phase PGE₂ production is mainly due to COX-1 activity because COX-2 expression was subsided. That is why SC-560, even if inhibited COX-1 activity, did not reduce PGE₂ content sufficiently for impairing the healing of intestinal lesions.

It should be noted that in the present study, following the administration of indomethacin or SC-560 for the last 3 days the ulcer score on day 7 was greater than that in the control on day 4. Similar results were obtained in the animals given indomethacin or rofecoxib for the first 3 days after ulceration was induced. These results suggest that such treatments not only impaired the healing but also exacerbated the ulcers. A deficiency of PGs due to inhibition of COX-1 causes a decrease in the secretion of mucus and an increase in intestinal motility, resulting in the facilitation of enterobacterial invasion and inflammatory responses [Tanaka et al., 2002b]. Similarly, PGs produced by COX-2 have been shown to reduce inflammatory responses through inhibition of iNOS activity as well as neutrophil activation [Tanaka et al., 2002b]. Thus, it is possible that inhibition of COX-1 for the last 3 days or COX-2 for the first 3 days causes an exacerbation of the intestinal damage, in addition to an interruption of the healing

process. The present study demonstrated the importance of both COX-1 and COX-2 in the healing process of intestinal lesions and further showed that COX-2 is mainly involved in the early stage of healing while COX-1 is involved in the late stage. Thus, healing of intestinal lesions was impaired when either COX-1 or COX-2 activity was inhibited by SC-560 or rofecoxib, respectively. This is in contrast to the pathogenesis of NSAID-induced intestinal lesions. It is known that the intestinal ulcerogenic properties of NSAID are not accounted for solely by inhibition of COX-1 and requires inhibition of COX-2 as well [Tanaka et al., 2002a]. Inhibition of COX-1, despite causing intestinal hypermotility, bacterial invasion and iNOS expression, up-regulates the expression of COX-2, and the PGE₂ produced by COX-2 counteracts deleterious events, and maintains the mucosal integrity [Tanaka et al., 2002b; Takeuchi et al., 2002].

The healing of tissues involves multiple steps, including the formation of granulation tissue, contraction of the ulcerated tissue and re-epithelialization, and these processes are regulated by growth factors, such as vascular endothelial growth factor (VEGF), basic fibroblast growth factor (bFGF) and other cytokines produced locally by regenerating cells [Matthews & Garner, 1991; Tarnawski et al., 2001]. Indomethacin inhibited bFGF-stimulated endothelial cell proliferation essential for angiogenesis [Pai et al., 2000] and also inhibited EGF-stimulated epithelial cell migration [Szabo et al., 2002]. Selective COX-2 inhibitors also suppressed granulation, re-vascularization, and the proliferation/migration of epithelial cells, which resulted in a delay in the healing of ulcers [Schmassmann et al., 1998; Dong et al., 2000]. Majima et al. [2000] reported that PGE₂ derived from COX-2 stimulated granulation in the air pouch model through the up-regulation of VEGF production. In the present study, we assessed vascular content by measuring the amount of carmine incorporated in the vascular formation and found that it increased in parallel with the healing of intestinal ulcers, with a peak on day 4.

The angiogenic response on day 4 was inhibited by rofecoxib and indomethacin given for the first 3 days while that on day 7 was suppressed by SC-560 and indomethacin, the results being consistent with the effects of COX inhibitors on the healing as determined from the area of lesions. These results were supported by the present data on the time-course of change in COX-2 expression and PGE₂ content in the small intestine after ulceration. Jones et al. [1999] reported that both selective and nonselective NSAIDs inhibit angiogenesis by acting directly on endothelial cells, suggesting that both COX-1 and COX-2 are important for the regulation of angiogenesis. Blisklager et al. [2002] also reported that in the porcine ileum, although COX-2 is expressed in the villus cells after ischemic damage, the expression of COX-1 is still observed in uninjured crypt cells, and suggested that recovery of resistance was triggered by PGE₂ produced by both COX-1 and COX-2. Thus, these results support the idea that the spontaneous healing of intestinal ulcers is regulated by endogenous PGs produced not only by COX-2 but also by COX-1 as well, and the healing promoting effect of PGs occurs through stimulation of the angiogenic response. Tessner et al. [2003] reported that bFGF up-regulated COX-2 expression in I407 cells through p38 MAP kinase. It is, thus, possible that several growth factors such as VEGF and bFGF are involved in the healing of intestinal ulcers through interaction with COX-2/PGs.

The receptors activated by PGE₂ are pharmacologically subdivided into four subtypes, EP1~EP4 [Coleman et al., 1994]. The distribution of these receptors is considered to explain the multiple effects of PGE₂ in various tissues including the gastrointestinal tract. We previously reported that the protective effect of PGE₂ on indomethacin-induced intestinal lesions was mediated by both EP3 and EP4 receptors [Kunikata et al., 2001]. Activation of EP4 receptors increased the secretion of mucus and enteropooling while it inhibited intestinal motility in response to indomethacin

[Kunikata et al., 2001]. It is possible that PGE₂ enhanced the healing of intestinal ulcers by blocking aggressive factors in the mucosa. Sonoshita *et al.* [2001] and Hoper *et al.* [1997] showed that the up-regulation by PGE₂ of VEGF expression occurs in association with increased formation of adenosine 3', 5'-cyclic monophosphate through the activation of EP4 receptors. Recently, we found that an EP4 antagonist impaired the healing of gastric ulcers, similar to rofecoxib while an EP4 agonist antagonized the deleterious influence of indomethacin on the healing [Tanaka et al., 2005]. We also observed that the expression of VEGF in the ulcerated mucosa was suppressed by the EP4 antagonist as well as rofecoxib, suggesting that PGE₂ increases VEGF expression via EP4 receptors [Tanaka et al., 2005]. In the present study, we observed that the EP4 antagonist AE3-208 impaired the healing of intestinal ulcers, similar to indomethacin or rofecoxib, and that the EP4 agonist AE1-329 significantly antagonized the deleterious effect of indomethacin on the healing process. These results suggest that PGE₂ produced by both COX-1 and COX-2 promoted the healing of intestinal ulcers through the stimulation of angiogenesis mediated by EP4 receptors. However, Amano et al. [2003] showed that angiogenesis in a sponge implantation model was markedly suppressed in mice lacking EP3 receptors with reduced expression of VEGF, suggesting the significance of PGE₂/EP3 receptor signaling in angiogenesis. Courtney et al., [2003] reported that PGE₂ protected the intestinal mucosa against radiation-induced damage mediated by EP2 receptors through the suppression of apoptosis. At present, these discrepancies remain unexplained, yet they may be due to different experimental conditions. Further study is certainly required to verify the EP receptor subtype involved in the healing of intestinal ulcers.

Given the present findings, it is concluded that endogenous PGs produced by both COX-1 and COX-2 are involved in the healing of intestinal ulcers, but the COX

isozyme responsible for the production of PGs differs depending on the phase of the healing process, COX-2 at the early phase and COX-1 at the late phase. In addition, PGE₂ produced by COX-1 and COX-2 contributes to the healing of intestinal ulcers through stimulation of the angiogenic response, probably mediated by the activation of EP4 receptors. The precise mechanism by which PGE₂ stimulates angiogenesis should be clarified. Finally, because the doses of various COX inhibitors given in this study are translated to those that are relevant to humans, the use of COX-1/COX-2 inhibitors needs to be re-discussed in patients with ulcers depending on the stage of healing process.

References

- Amano H, Hayashi I, Endo H, Kitasato H, Yamashina S, Maruyama T, Kobayashi M, Satoh K, Narita M, Sugimoto Y, Murata T, Yoshimura H, Narumiya S, Majima M (2003) Host prostaglandin E(2)-EP3 signaling regulates tumor-associated angiogenesis and tumor growth. *J Exp Med* 197: 221-232.
- Aoi M, Aihara E, Nakashima M, Takeuchi K (2004) Participation of prostaglandin receptor EP4 subtype in duodenal bicarbonate secretion in rats. *Am J Physiol* 287: G96-G103.
- Araki H, Ukawa H, Sugawa Y, Yagi K, Suzuki K, Takeuchi K (2000) Roles of prostaglandin E receptor subtypes in cytoprotective action of prostaglandin E₂ in rat stomachs. *Aliment Pharmacol Ther* 14 (Suppl 1): 116-124.
- Araki H, Komoike Y, Matsumoto M, Tanaka A, Takeuchi K (2002) Healing of duodenal ulcers is not impaired by indomethacin or rofecoxib, the selective COX-2 inhibitor, in rats. *Digestion* 66: 145-153.
- Blikslager AT, Zimmel DN, Young KM, Campbell NB, Little D, Argenzio RA (2002) Recovery of ischemic injured porcine ileum: evidence for a contributory role of COX-1 and COX-2. *Gut* 50: 615-623.
- Brzozowski T, Konturek PC, Konturek SJ, Sliwowski Z, Pajdo R, Drozdowicz D, Ptak A, Hahn EG (2001) Classic NSAID and selective cyclooxygenase (COX)-1 and COX-2 inhibitors in healing of chronic gastric ulcers. *Microsc Res Tech* 53: 343-353.
- Coleman RA, Smith WL, Narumiya S (1994) Classification of prostanoid receptors: properties, distribution, and structure of the receptors and their subtypes. *Pharmacol Rev* 46, 205-229.
- Houchen CW, Sturmoski MA, Anant S, Breyer RM, Stenson WF (2003) Prosurvival and

- antiapoptotic effects of PGE₂ in radiation injury are mediated by EP2 receptor in intestine. *Am J Physiol* 284, G490-G498.
- Han DS, Li F, Holt L, Connolly K, Hubert M, Miceli R, Okoye Z, Santiago G, Windle K, Wong E, Sartor RB (2000) Keratinocyte growth factor (FGF-10) promotes healing of experimental small intestinal ulceration in rats. *Am J Physiol* 279: G1011-G1022.
- Feng L, Sun W, Xia Y, Tang WW, Chanmugam P, Soyoola E, Wilson CB, Hwang D. (1993) Cloning two isoforms of rat cyclooxygenase: Differential regulation of
- Halter F, Tarnawski AS, Schmassmann A, Peskar BM (2001) Cyclooxygenase 2-implications on maintenance of gastric mucosal integrity and ulcer healing: controversial issues and perspectives. *Gut* 49: 443-453.
- Hoper MM, Voelkel NF, Bates TO, Allard JD, Horan M, Shepherd D, Tudor RM. (1997) Prostaglandins induce vascular endothelial growth factor in a human monocytic cell line and rat lungs via camp. *Am. J. Respir. Cell Mol. Biol* 7, 748-756.
- Jones MK, Wang H, Peskar BM, Levin E, Itani RM, Sarfeh IJ, Tarnawski AS (1999) Inhibition of angiogenesis by nonsteroidal anti-inflammatory drugs: insight into mechanisms and implications for cancer growth and ulcer healing. *Nature Medecine* 5: 1418-1423.
- Kargman S, Charlesion S, Cartwright M, Frank J, Riendeaw D, Mancini J, Evans JG (1993) Characterization of prostaglandin G/H synthase 1 and 2 in rat, dog, monkey, and human gastrointestinal tracts. *Gastroenterology* 111: 445-454.
- Kimura M, Amemiya K, Yamada T, Suzuki J (1986) Quantitative method for measuring adjuvant-induced angiogenesis in insulin-treated diabetic mice. *J Pharmacobiodyn* 9: 442-446.
- Kishimoto Y, Wada K, Nakamoto K, Ashida K, Kamisaki Y, Kawasaki H, Itoh T (1997) Quantitative analysis of cyclooxygenase-2 gene expression on acute gastric injury

- induced by ischemia-reperfusion in rats. *Life Sci* 60: 127-133.
- Kunikata T, Tanaka A, Miyazawa T, Kato S, Takeuchi K (2000) 16,16-dimethyl prostaglandin E₂ inhibits indomethacin-induced small intestinal lesions through EP3 and EP4 receptors. *Dig Dis Sci* 47: 894-904.
- Levi S, Goodlad RA, Lee CY, Stamp G, Walport MJ, Wright NA, Hodgson HJF (1990) Inhibitory effect of non-steroidal anti-inflammatory drugs on mucosal cell proliferation associated with gastric ulcer healing. *Lancet* 336: 840-843.
- Majima M, Hayashi I, Muramatsu M, Katada J, Yamashina S, Katori M (2000) Cyclooxygenase-2 enhances basic fibroblast growth factor-induced angiogenesis through the induction of vascular endothelial growth factor in rat sponge implants. *Br J Pharmacol* 130: 641-649.
- Matthews JB, Garner A (1991) Review article: stomach wars: a mucosal defence initiative. *Aliment Pharmacol Ther* 5: 105-114.
- Mizuno H, Sakamoto C, Matsuda K, Wada K, Uchida T, Noguchi H, Akamatsu T, Kasuga M (1997) Induction of cyclooxygenase-2 in gastric mucosal lesions and its inhibition by the specific antagonist delays healing in mice. *Gastroenterology* 112: 387-397.
- O'Neill GP, Ford-Hutchinson AW (1993) Expression of mRNA for cyclooxygenase-1 and cyclooxygenase-2 in human tissues. *FEBS* 330: 156-160.
- Pai R, Szabo IL, Kawanaka H, Soreghan BA, Jones MK, Tarnawski AS (2000) Indomethacin inhibits endothelial cell proliferation by suppressing cell cycle proteins and PRB phosphorylation: a key to its antiangiogenic action? *Mol Cell Biol Res Commun* 4: 111-116.
- Sawaoka H, Tsuji S, Tsujii M, Gunawan ES, Nakama A, Takei Y, Nagano K, Matsui H, Kawano S, Hori M (1997) Expression of the cyclooxygenase 2 gene in gastric

- epithelium. *J Clin Gastroenterol* 25 (Suppl 1): S105-S110.
- Schmassmann A, Tarnawski AS, Peskar BM, Varga L, Flogerzi B, Halter F (1995) Influence of acid and angiogenesis on kinetics of gastric ulcer healing in rat: interaction with indomethacin. *Am J Physiol* 268: G276-G285.
- Shigeta J, Takahashi S, Okabe S. (1998) Role of cyclooxygenase-2 in the healing of gastric ulcers in rats. *J Pharmacol Exp Ther* 286: 1383-1390.
- Singer II, Kawka DW, Schloemann S, Tessner T, Riehl T, Stenson WF (1998) Cyclooxygenase 2 is induced in colonic epithelial cells in inflammatory bowel disease. *Gastroenterology* 115: 297-306.
- Sonoshita M, Takaku K, Sasaki N, Sugimoto Y, Ushikubi F, Narumiya S, Oshima M, Taketo MM (2001) Acceleration of intestinal polyposis through prostaglandin receptor EP2 in *Apc* (Delta 716) knockout mice. *Nat Med* 7: 1048-1051.
- Szabo IL, Pai R, Jones MK, Ehring GR, Kawanaka H, Tarnawski AS (2002) Indomethacin delays gastric restitution: association with the inhibition of focal adhesion kinase and tensin phosphorylation and reduced actin stress fibers. *Exp Biol Med* 227: 412-424.
- Takeuchi K, Ueshima K, Ohuchi T, Okabe S (1994) Role of capsaicin-sensitive sensory neurons in healing of HCl-induced gastric mucosal lesions in rats. *Gastroenterology* 106: 1524-1532.
- Takeuchi K, Yagi K, Kato S, Kitamura M (1997) Role of prostaglandin E receptor subtypes in gastric and duodenal bicarbonate secretion in rats. *Gastroenterology* 13: 1553-1559.
- Tanaka A., Hase S, Miyazawa T. Takeuchi K (2002) Up-regulation of COX-2 by inhibition of COX-1: A key to NSAID-Induced intestinal damage. *J Pharmacol Exp Ther* 300: 754-761.

- Tanaka A, Hase S, Ohno R, Takeuchi K (2002) Roles of COX-1 and COX-2 inhibition in NSAID-induced intestinal damage in rats. *J Pharmacol Exp Ther* 303: 1248-1254.
- Tanaka A, Takahira Y, Ashida Y, Takeuchi K (2005) Involvement of cyclooxygenase-2/prostaglandins and EP4 receptor subtype in the healing mechanism of gastric ulcers in mice. *Gastroenterology* 128 (abstract): 839.
- Tarnawski A, Szabo IL, Husain SS, Soreghan B (2001) Regeneration of gastric mucosa during ulcer healing is triggered by growth factors and signal transduction pathways. *J Physiol Paris* 95: 337-344.
- Tessner TG, Muhale RF, Schloemann S, Cohn SM, Morrison A, Stenson WF (2003) Basic fibroblast growth factor upregulates cyclooxygenase-2 in I407 cells through p38 MAP kinase. *Am J Physiol* 284: G269-G279.
- Tso JY, Sun X-H, Kao T-H, Reece KS, Wu R (1985) Isolation and characterization of rat and human glyceraldehyde-3-phosphate dehydrogenase cDNAs: Genomic complexity and molecular evolution of the gene. *Nucleic Acids Res* 13: 2485-2502.
- Ukawa H, Yamakuni H, Kato S, Takeuchi K (1998) Effects of cyclooxygenase-2 selective and nitric oxide-releasing nonsteroidal anti-inflammatory drugs on gastric ulcerogenic and healing responses in experimental animals. *Dig Dis Sci* 43: 2003-2011
- Wallace JL, McKnight W, Reuter BK, Vergnolle N (2000) NSAID-induced gastric damage in rats: Requirement for inhibition of both cyclooxygenase 1 and 2. *Gastroenterology* 119: 706-714.
- Wang JY, Yamasaki S, Takeuchi K, Okabe S (1989) Delayed healing of acetic acid-induced gastric ulcers in rats by indomethacin. *Gastroenterology* 96: 393-402.

Footnotes

This research was supported in part by the Kyoto Pharmaceutical University's "21st Century COE" program and the "Open Research" Program from the Ministry of Education, Science and Culture of Japan. We thank Ono Pharmaceutical Co. Ltd. for generously supplying various EP agonists and antagonist.

Figure Legends

Figure 1. Healing of indomethacin-induced small intestinal lesions in rats. Animals were given indomethacin (10 mg/kg, s.c.) and killed various days (1, 2, 3, 5, and 7 days) after ulceration. Data are presented as the mean±SE for 6 rats. * Significant difference from the values on day 1, at $P<0.05$.

Figure 2. Microscopical observation of indomethacin-induced small intestinal lesions during healing in rats H&E (x 40). The animals were given indomethacin (10 mg/kg, s.c.) and killed on various days (1, 2, 3, 5, and 7 days) after the administration.

Figure 3. Time course of changes in mucosal PGE₂ content in rat small intestines. The animals were given indomethacin (10 mg/kg, s.c.) and killed at various time points (3 hr, and 1, 2, 3, 5, and 7 days) after ulceration. The mucosal PGE₂ content was measured by EIA. Data are presented as the mean±SE for 6 rats. * Significant difference from normal, at $P<0.05$. N: normal rats (without indomethacin treatment)

Figure 4. Mucosal expression of COX-1 and COX-2 mRNAs after the induction of intestinal lesions in rats. The animals were given indomethacin (10 mg/kg, s.c.) and killed various days (1, 2, 3, 5, and 7 days) after the administration. The expression of COX-1 and COX-2 mRNAs was analyzed by RT-PCR. Note that the expression of COX-2 mRNA was up-regulated in the intestinal mucosa after ulceration, the intensity being greatest during the first 3 days and gradually fading thereafter. N: Normal rat (without indomethacin treatment)

Figure 5. Effect of COX inhibitors on healing of indomethacin-induced small intestinal lesions in rats. The animals were given indomethacin (10 mg/kg, s.c.) and killed 7 days later. Indomethacin (2 mg/kg), SC-560 (3 mg/kg), rofecoxib (3 mg/kg; ROF) or SC-560 plus rofecoxib was given p.o. once daily for 6 days, starting from 1 day after ulceration. Data are presented as the mean±SE for 8 rats. * Significant difference from control, at $P<0.05$.

Figure 6. Effect of COX inhibitors on the early-stage healing of indomethacin-induced small intestinal lesions in rats. The animals were given indomethacin (10 mg/kg, s.c.) and killed 7 days later. Indomethacin (2 mg/kg), SC-560 (3 mg/kg), rofecoxib (3 mg/kg; ROF) or SC-560 plus rofecoxib was given p.o. once daily for 3 days, starting from 1 day after the induction of lesions. DMPGE₂ (20 µg/kg, p.o.) was given twice daily for 3 days 30 min before and 6 hr after indomethacin (2 mg/kg). Data are presented as the mean±SE for 7-9 rats. Significant difference at $P<0.05$; * from control; # from vehicle.

Figure 7. Microscopical observation of indomethacin-induced small intestinal lesions in rats treated with various COX inhibitors (H&E, x40). The animals were given indomethacin (10 mg/kg, s.c.) and killed 7 days later. Indomethacin (2 mg/kg) was given p.o. once daily for the first 3 days. DMPGE₂ (20 µg/kg) was administered p.o. twice daily for 3 days 30 min before and 6 hr after indomethacin.

Figure 8. Effects of COX inhibitors on mucosal PGE₂ content early in the healing of indomethacin-induced intestinal lesions in rats. The animals were given indomethacin (10 mg/kg, s.c.) to induce ulceration in the small intestine. Indomethacin (2 mg/kg),

SC-560 (3 mg/kg), rofecoxib (3 mg/kg; ROF) or SC-560 plus rofecoxib was given p.o. once daily for 3 days, starting from 1 day after ulceration, and the animals were killed 3 hr after the last administration. Data are presented as the mean±SE for 6-9 rats. Significant difference at $P<0.05$; # from normal; * from control.

Figure 9. Effect of COX Inhibitors on the late-stage healing of indomethacin-induced small intestinal lesions in rats. The animals were given indomethacin (10 mg/kg, s.c.) and killed 7 days later. Indomethacin (2 mg/kg), SC-560 (3 mg/kg), rofecoxib (3 mg/kg; ROF) or SC-560 plus rofecoxib was administered p.o. once daily for 3 days, starting from 4 days after the ulceration. Data are presented as the mean±SE for 7-9 rats. *Significant difference from control, at $P<0.05$.

Figure 10. Effects of COX inhibitors on mucosal PGE₂ content late in the healing of indomethacin-induced intestinal lesions in rats. The animals were given indomethacin (10 mg/kg, s.c.) to induce ulceration in the small intestine. Indomethacin (2 mg/kg), SC-560 (3 mg/kg), rofecoxib (3 mg/kg; ROF) or SC-560 plus rofecoxib was given p.o. once daily for 3 days, starting from 1 day after the ulceration, and the animals were killed 3 hr after the last administration. Data are presented as the mean±SE for 6-9 rats. *Significant difference from control, at $P<0.05$.

Figure 11. Effect of COX inhibitors on carmine content early (A) and late (B) in the healing of indomethacin-induced intestinal lesions in rats. The animals were given indomethacin (10 mg/kg, s.c.) and killed 4 and 7 days later, respectively. Indomethacin (2 mg/kg), SC-560 (3 mg/kg) or rofecoxib (3 mg/kg) was given p.o. once daily for the first 3 or the last 3 days, starting from 1 or 4 days after ulceration, respectively.

DMPGE₂ (20 µg/kg) was administered p.o. twice daily for 3 days 30 min before and 6 hr after indomethacin. Data are presented as the mean±SE for 4-6 rats. *Significant difference from control, at $P<0.05$.

Figure 12. (A) Effect of various EP agonists on the healing of indomethacin-induced small intestinal lesions in rats under PG-deficient conditions. The animals were given indomethacin (10 mg/kg, s.c.) and killed 7 days later. Indomethacin (2 mg/kg) was administered p.o. once daily for 6 days, starting from 1 day after ulceration. Various EP agonists were given i.p. twice daily for 6 days, 30 min before and 6 hr after indomethacin. Data are presented as the mean±SE for 5-7 rats. Significant difference at $P<0.05$; * from control; # from vehicle. **(B)** Effect of indomethacin and an EP4 antagonist (AE3-208) on the healing of intestinal lesions in rats. The animals were given indomethacin (10 mg/kg) s.c., and killed 7 days later. Indomethacin (2 mg/kg) or AE3-208 (3 mg/kg) was given p.o. once or i.p. twice daily, respectively, for 6 days. Data are presented as the mean±SE for 5-7 rats. * Significant difference from control, at $P<0.05$.

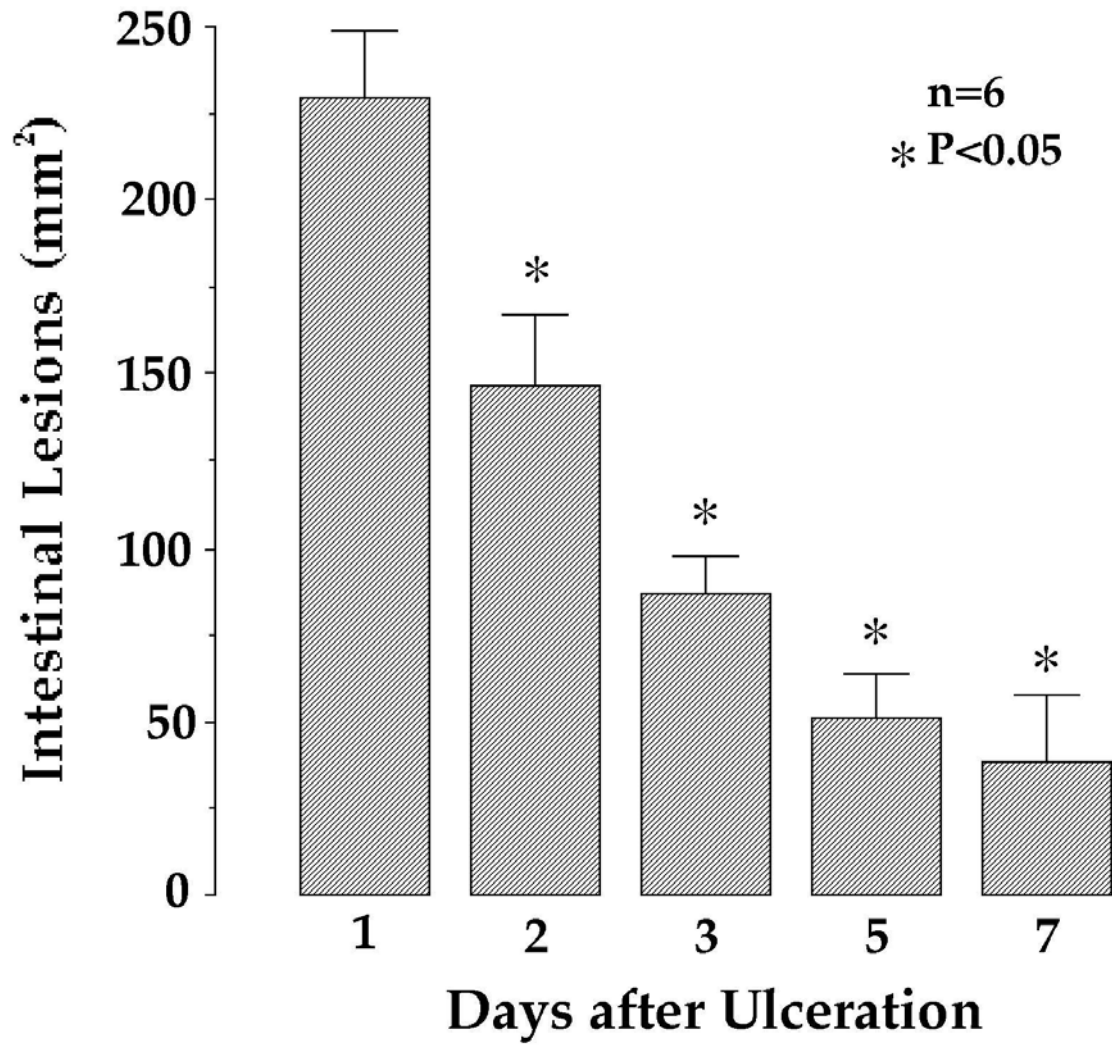


Figure 1

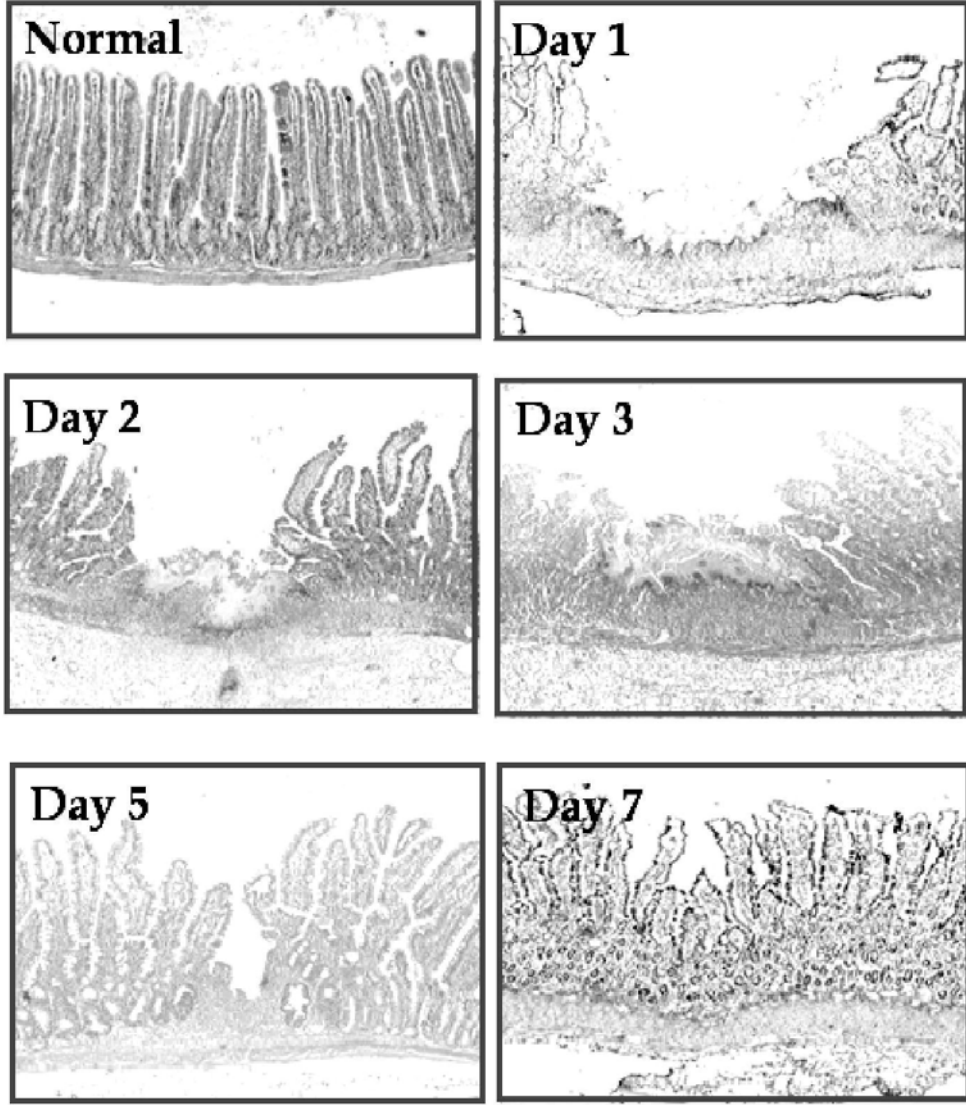


Figure 2

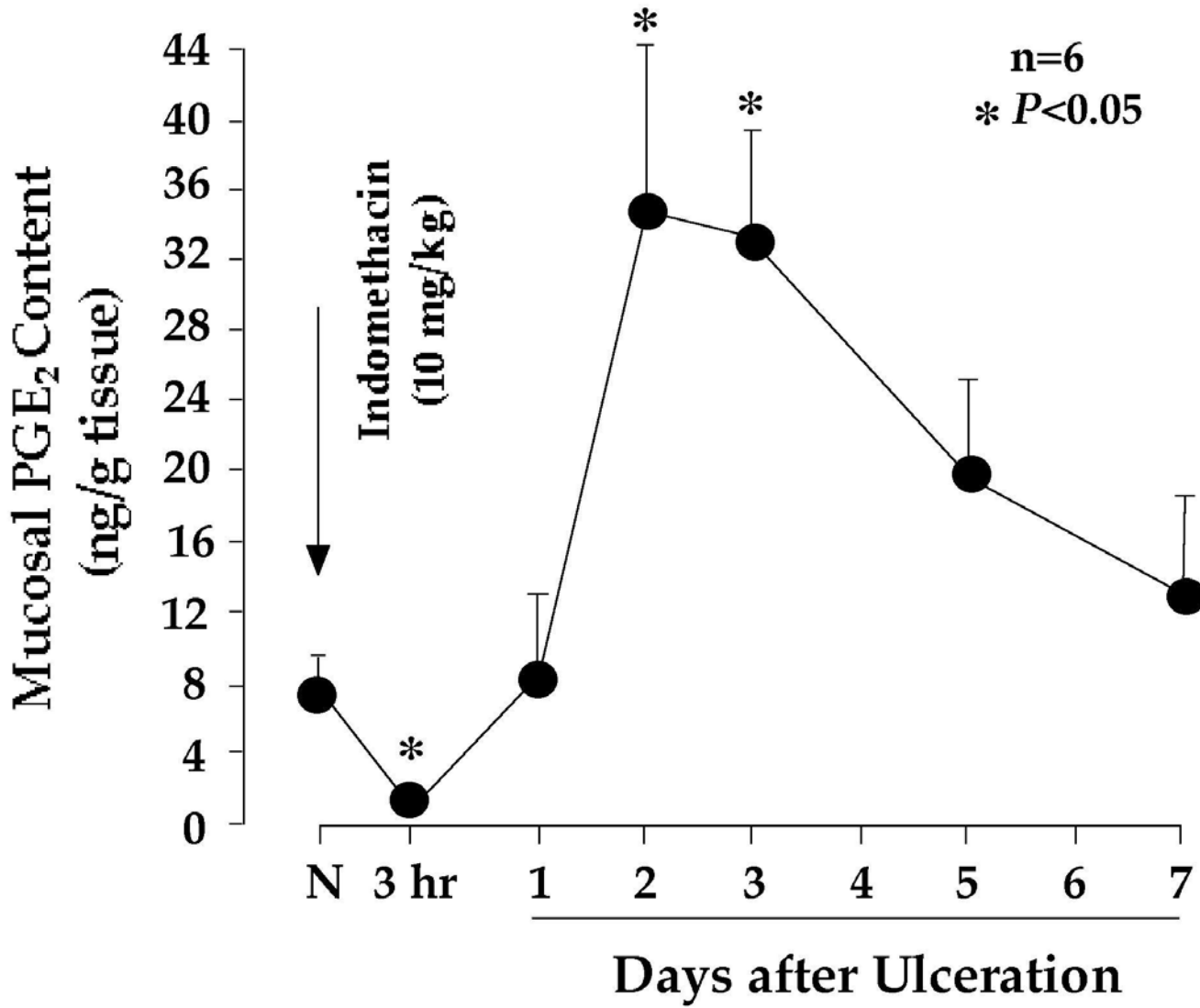


Figure 3

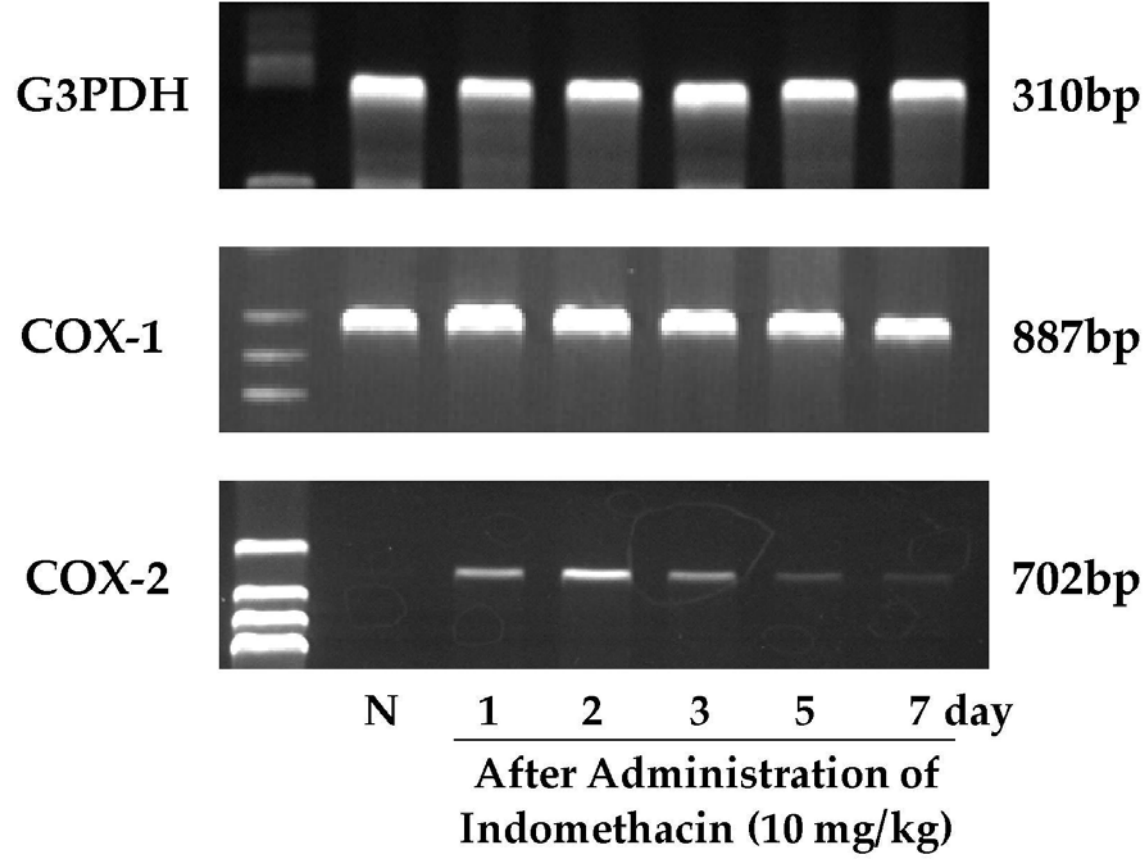


Figure 4

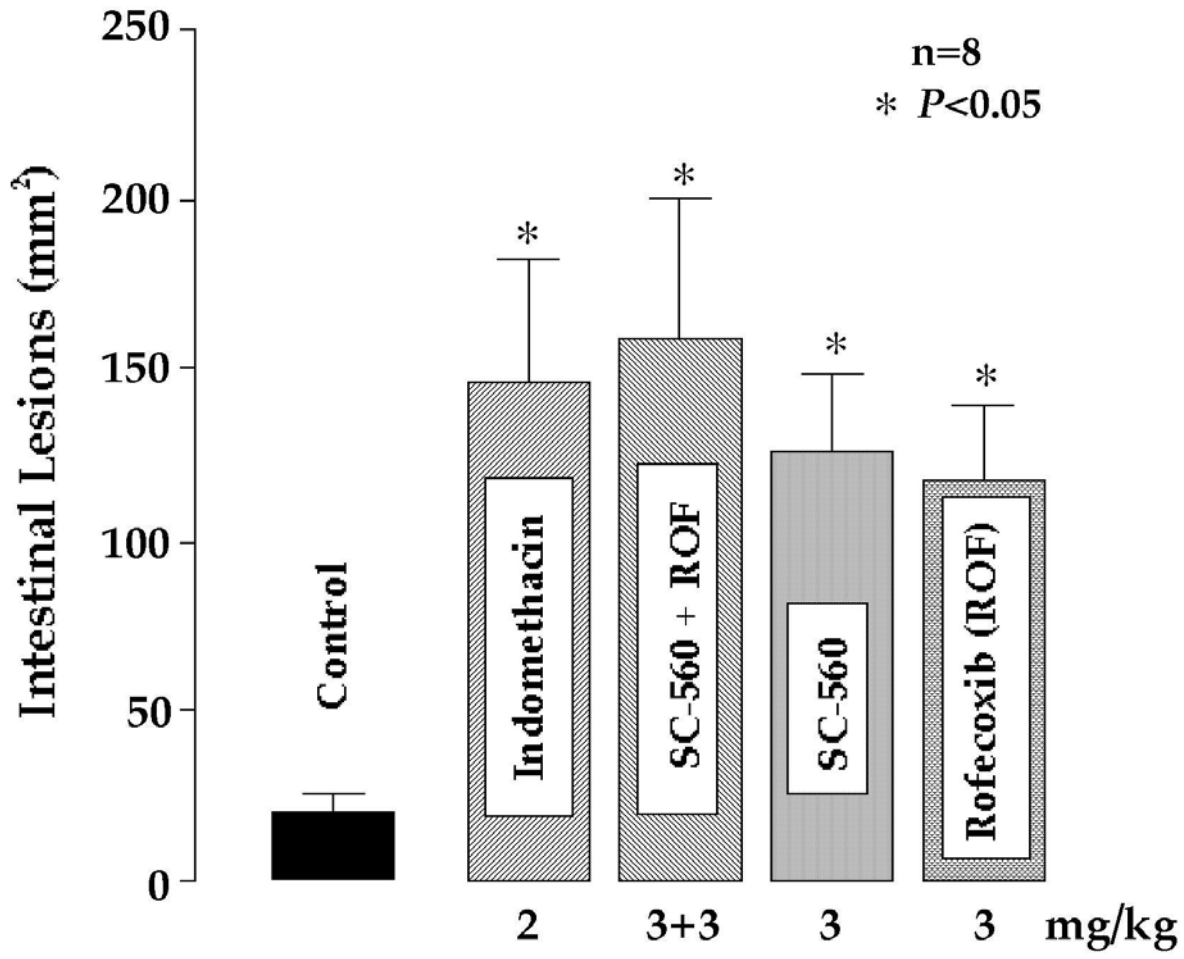


Figure 5

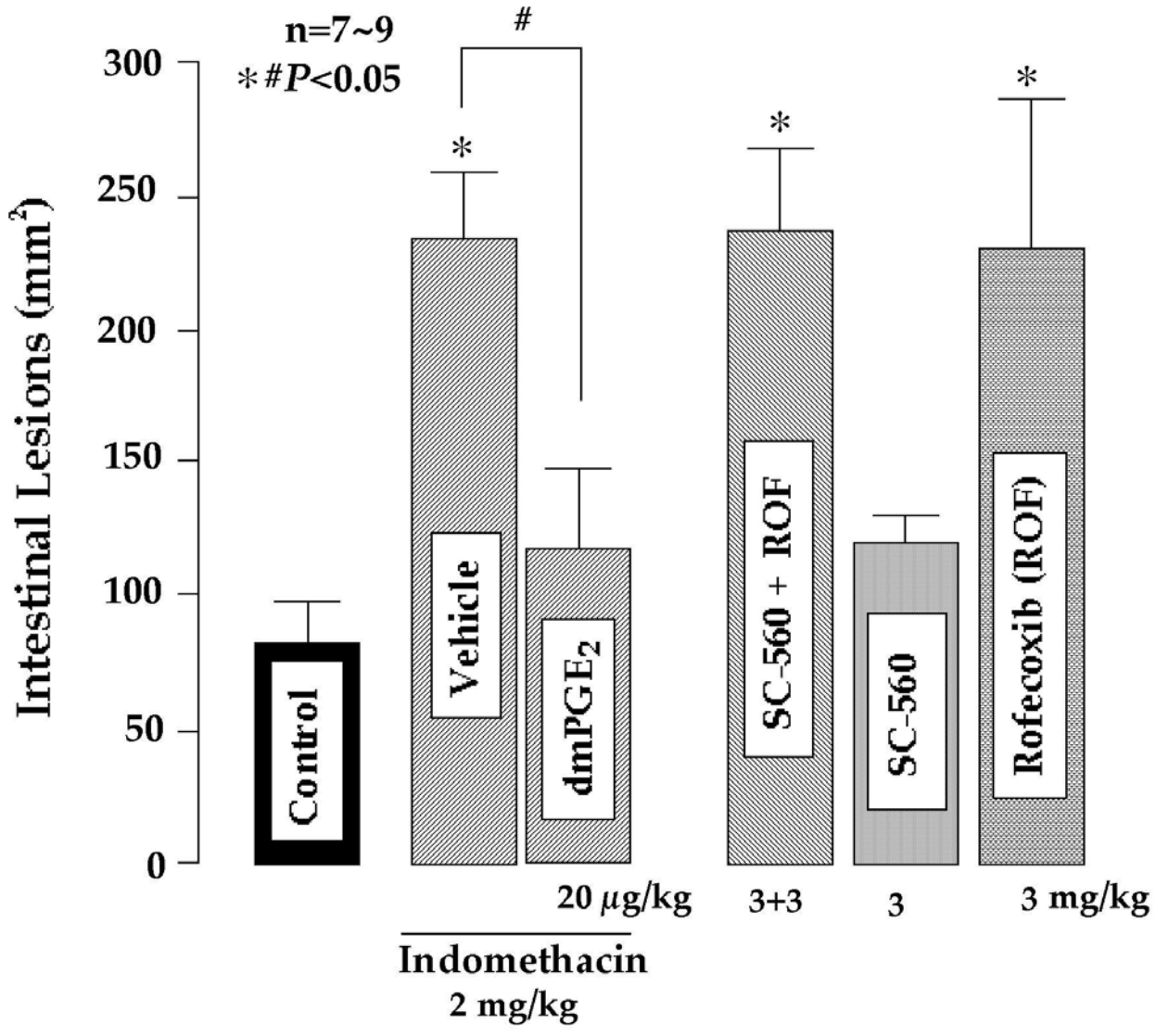


Figure 6

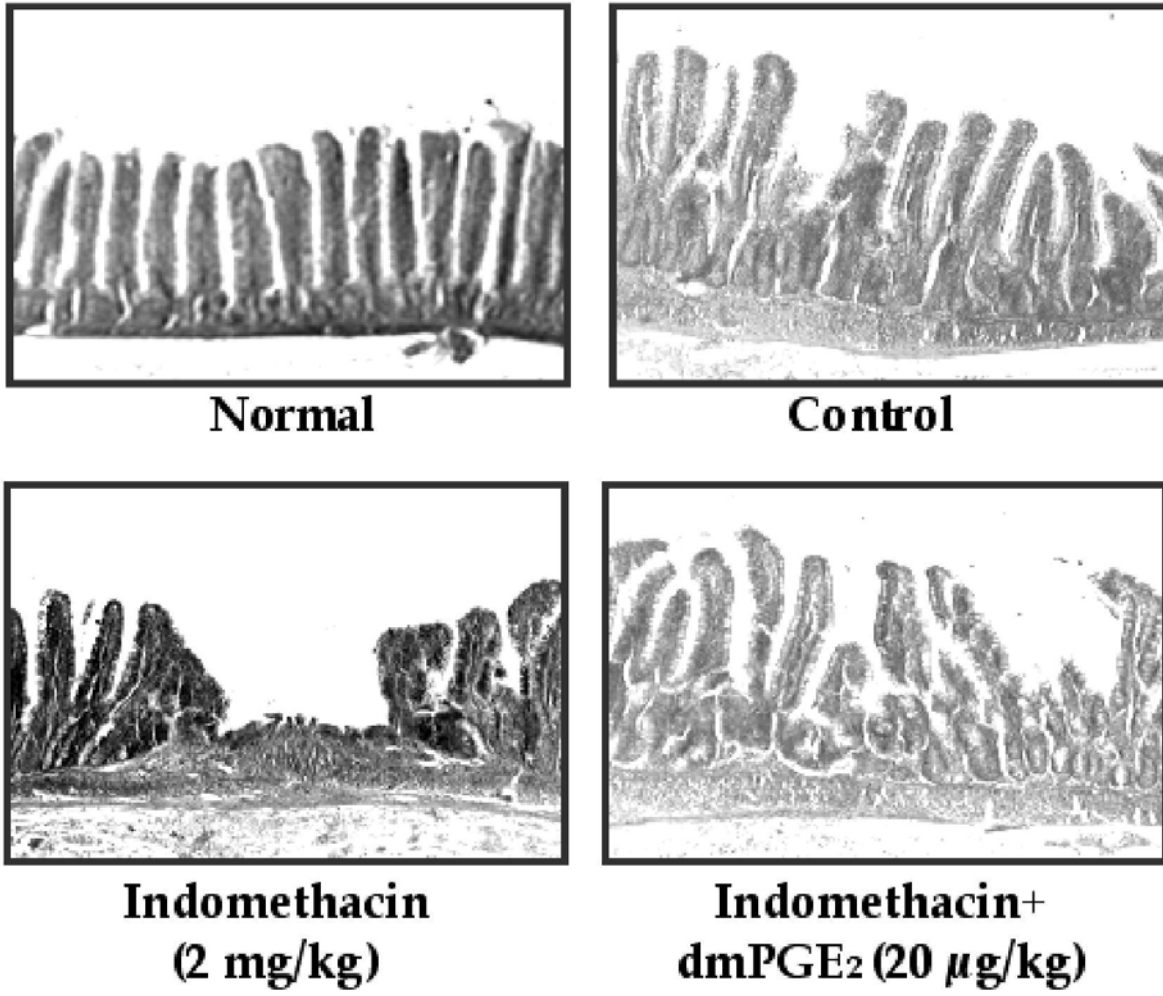


Figure 7

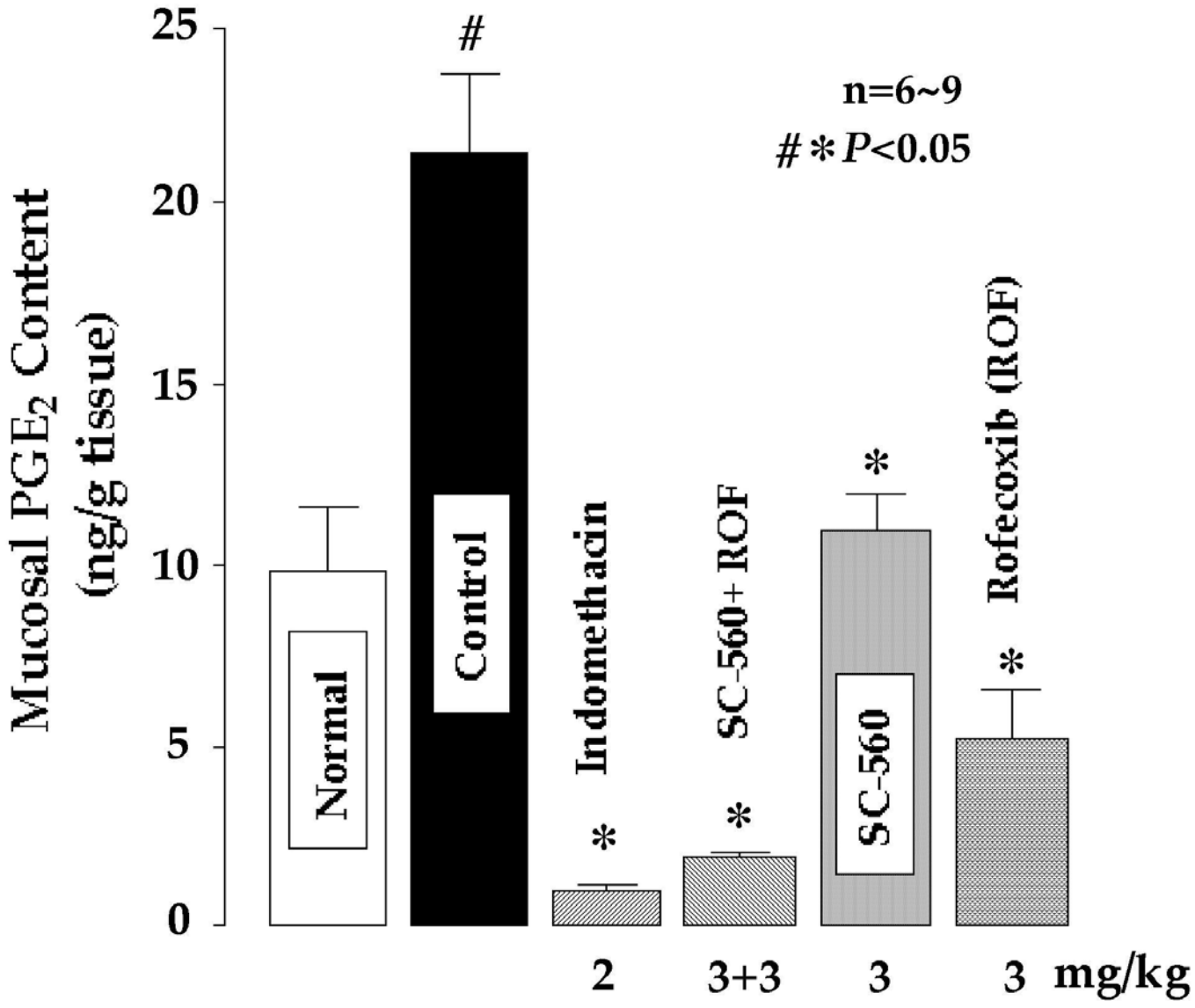


Figure 8

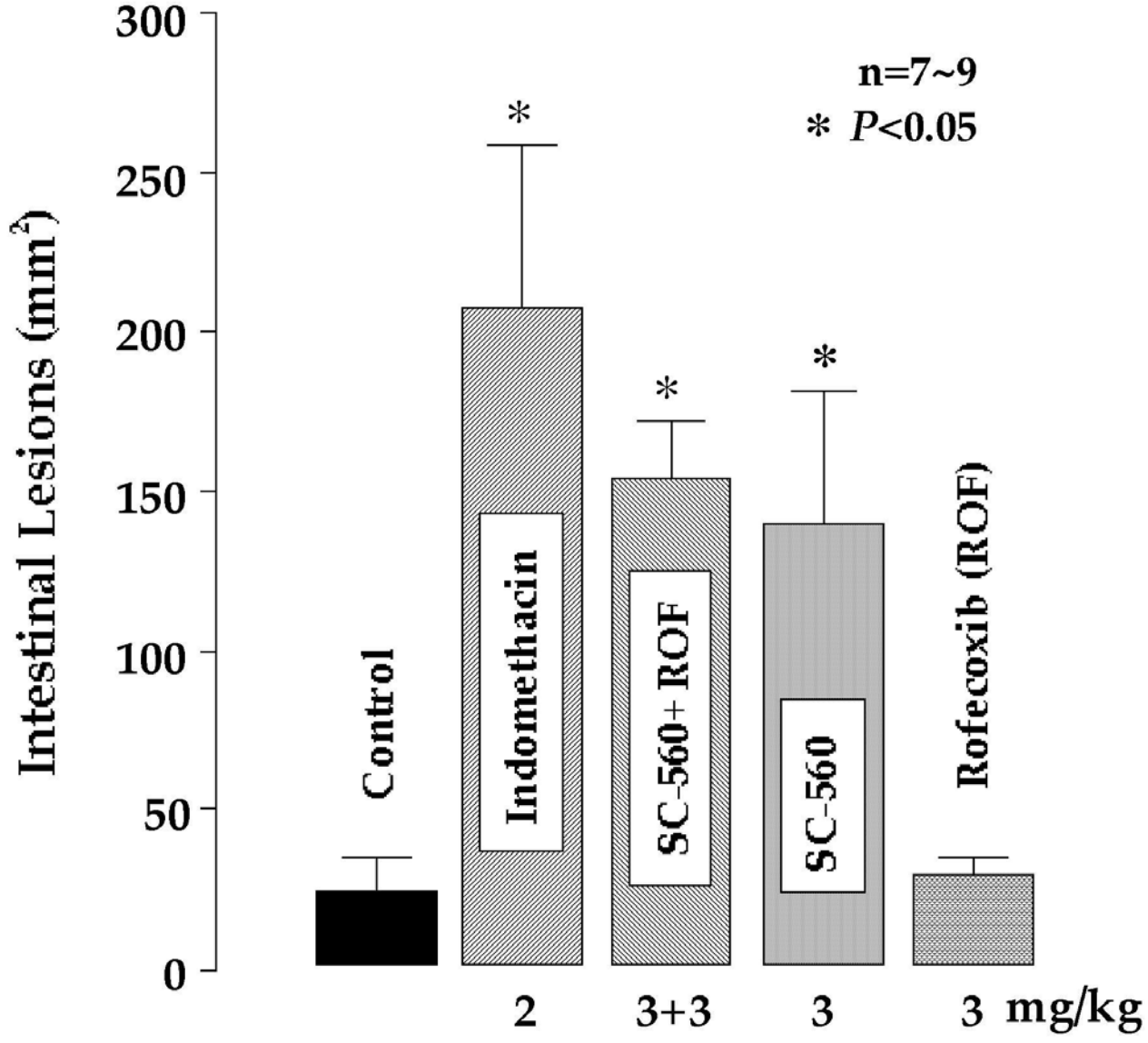


Figure 9

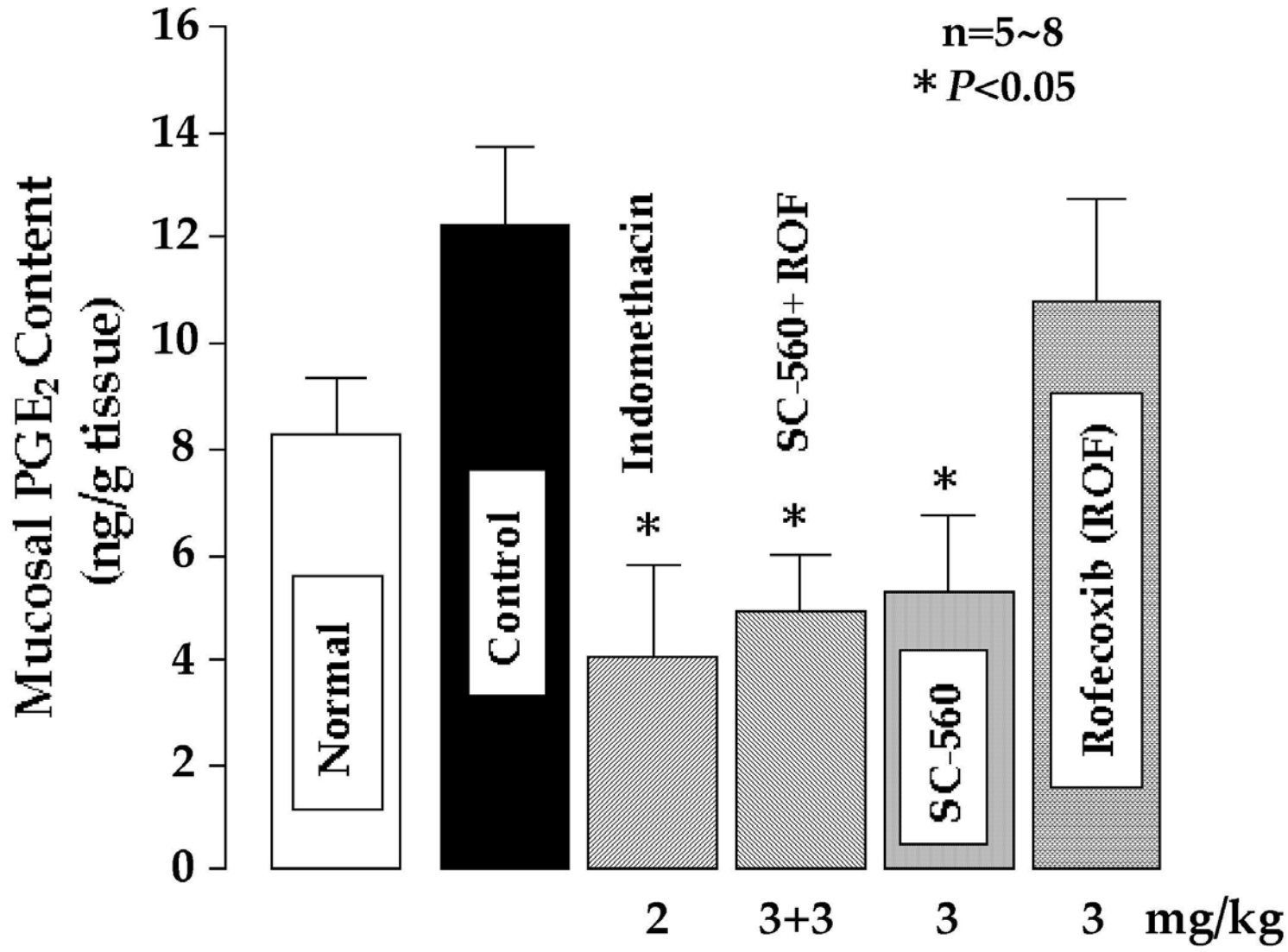


Figure 10

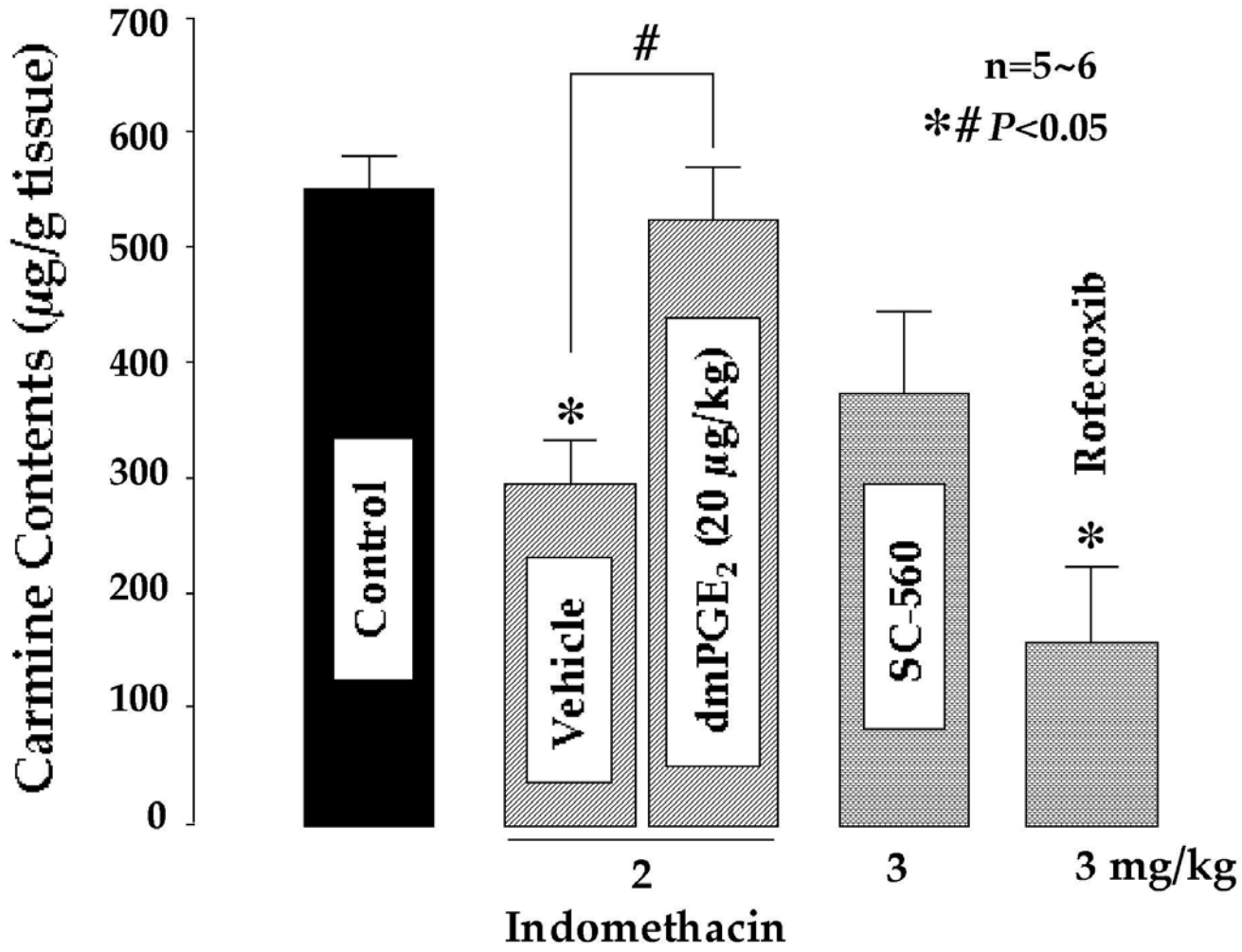


Figure 11A

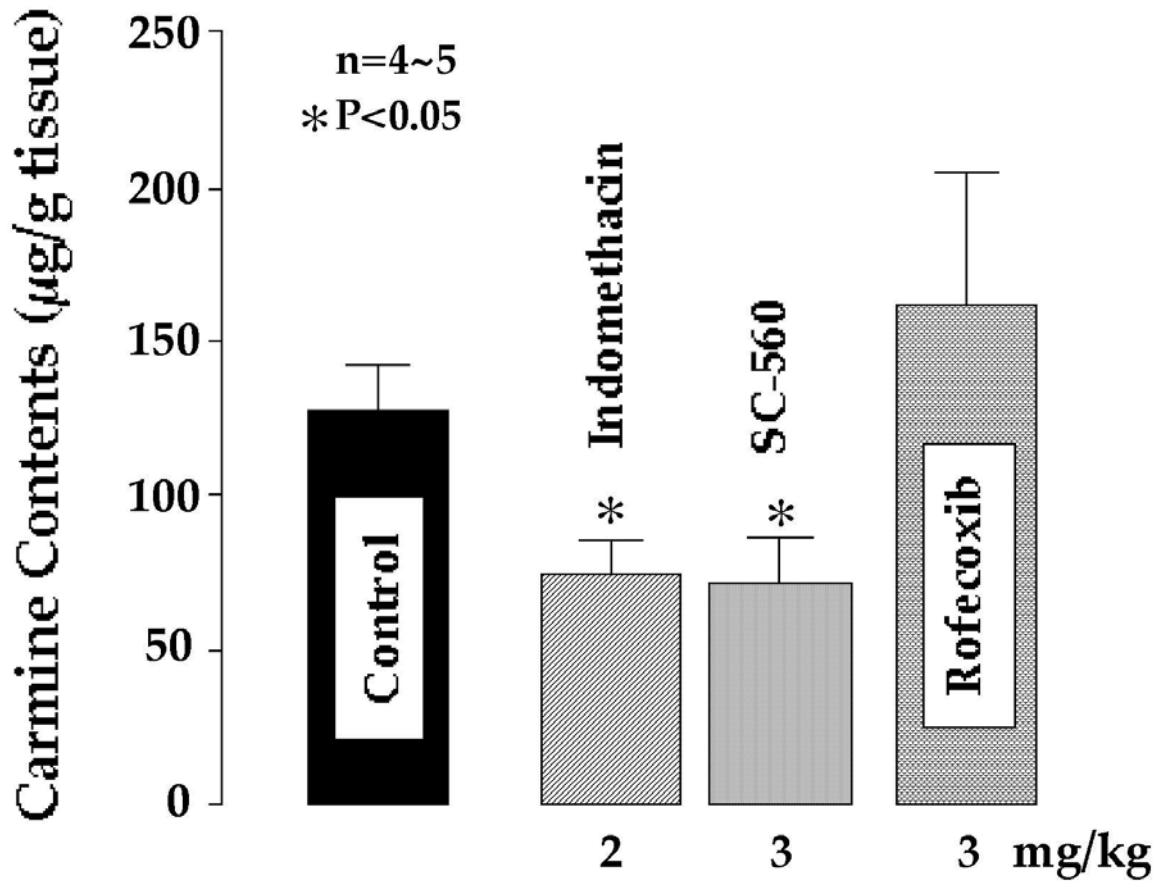


Figure 11B

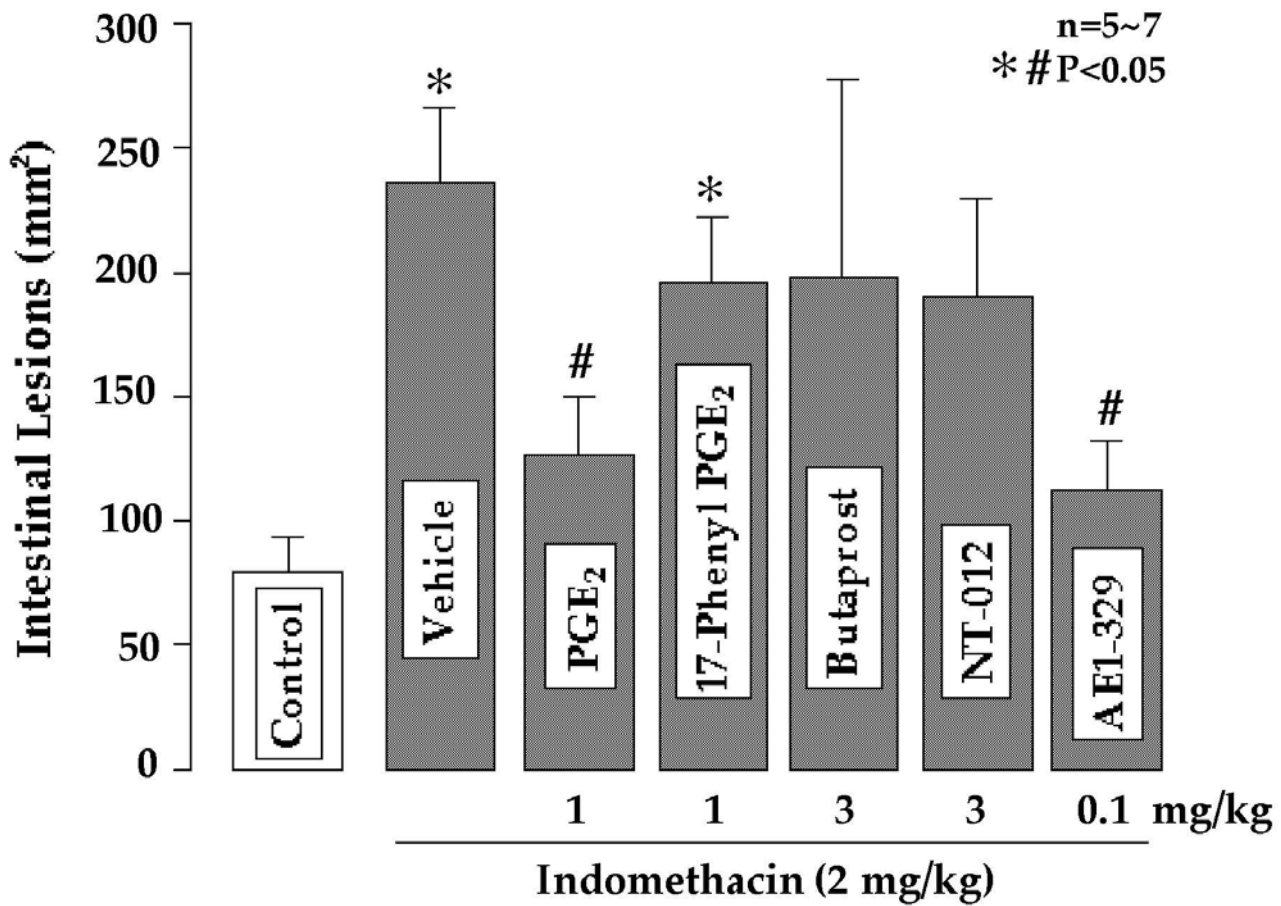


Figure 12A

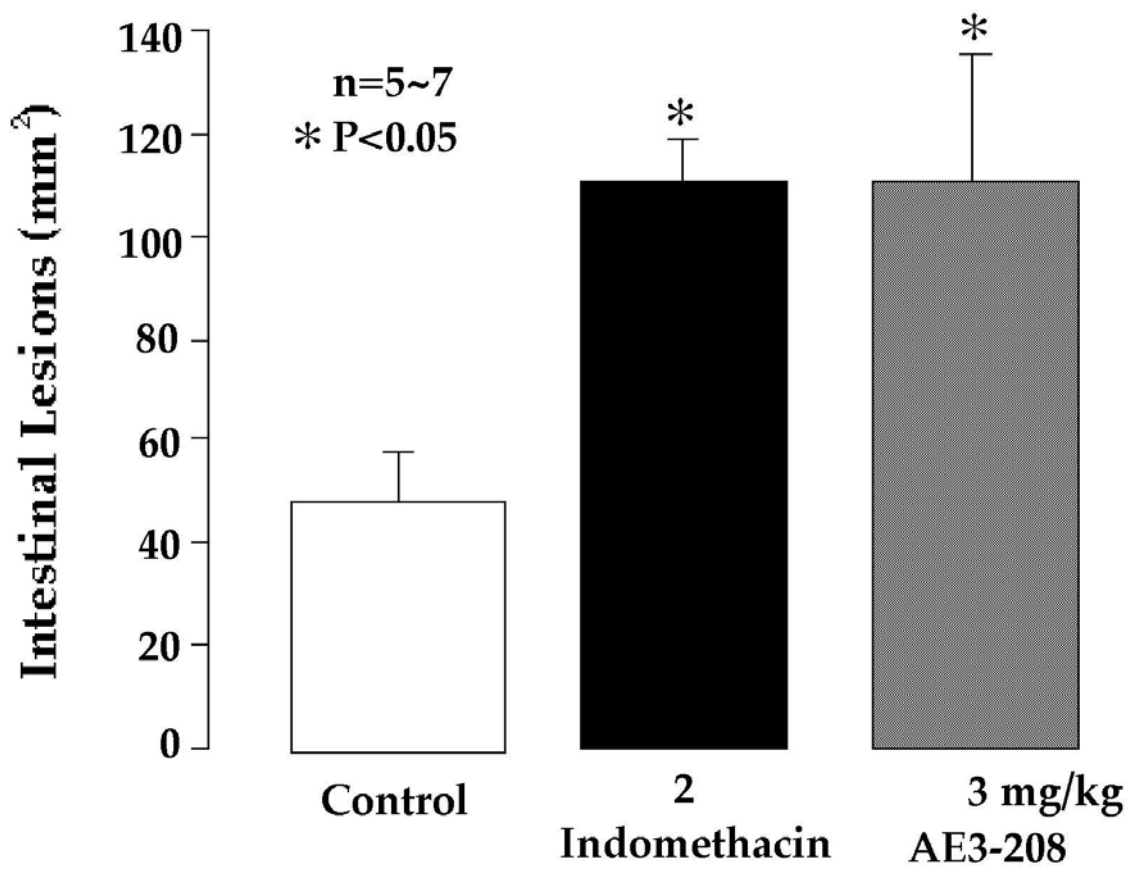


Figure 12B