

JPET #54288

Ranitidine Treatment during a Modest Inflammatory Response Precipitates Idiosyncrasy-like Liver Injury in Rats

James P. Luyendyk, Jane F. Maddox, Gregory N. Cosma, Patricia E. Ganey, Gary L. Cockerell, and Robert A. Roth

Department of Pharmacology and Toxicology
National Food Safety and Toxicology Center
Institute for Environmental Toxicology
Michigan State University, East Lansing, MI, 48824 USA. (JPL, JFM, PEG, RAR)

Investigative Toxicology
Pharmacia Corporation
Kalamazoo, MI, USA (GNC, GLC)

JPET #54288

Running Title: Inflammation and Ranitidine Idiosyncrasy

To whom correspondence should be sent:

Robert A. Roth
B440 Life Sciences
Department of Pharmacology and Toxicology
Michigan State University
East Lansing, MI 48824
Phone: (517) 353-9841
Fax: (517) 432-2310
rothr@msu.edu

Text pages: 23

Tables: 1

Figures: 5

References: 30

Abstract: 245

Introduction: 622

Discussion: 1517

Nonstandard abbreviations:

LPS, lipopolysaccharide

RAN, ranitidine

FAM, famotidine

PMN, neutrophil

PMN-CM, neutrophil-conditioned medium

JPET #54288

Abstract:

Drug idiosyncrasy is an adverse event of unknown etiology that occurs in a small fraction of people taking a drug. Some idiosyncratic drug reactions may occur from episodic decreases in the threshold for drug hepatotoxicity. Previous studies in rats have shown that modest underlying inflammation triggered by bacterial lipopolysaccharide (LPS) can decrease the threshold for xenobiotic hepatotoxicity. The histamine₂ (H₂)-receptor antagonist ranitidine (RAN) causes idiosyncratic reactions in people, with liver as a usual target. We tested the hypothesis that RAN could be rendered hepatotoxic in animals undergoing a modest inflammatory response. Male rats were treated with a nonhepatotoxic dose of LPS (44×10^6 EU/kg, iv) or its vehicle, then 2 hours later with a nonhepatotoxic dose of RAN (30 mg/kg, iv) or its vehicle. Liver injury was evident only in animals treated with both RAN and LPS as estimated by increases in serum alanine aminotransferase, aspartate aminotransferase and γ -glutamyl transferase activities within 6 h after RAN administration. LPS/RAN cotreatment resulted in midzonal liver lesions characterized by acute necrosuppurative hepatitis. Famotidine (FAM) is an H₂-antagonist for which the propensity for idiosyncratic reactions is far less than RAN. Rats given LPS and FAM at a dose pharmacologically equipotent to that of RAN did not develop liver injury. *In vitro*, RAN sensitized hepatocytes to killing by cytotoxic products from activated neutrophils, whereas FAM lacked this ability. The results indicate that a response resembling human RAN idiosyncrasy can be reproduced in animals by RAN exposure during modest inflammation.

JPET #54288

Adverse drug reactions of unknown etiology that occur in a small fraction of the treated population are defined as idiosyncratic. These reactions are typically unpredictable, show no obvious relation to dose, and display a variable time to onset in relation to start of drug therapy. A variety of drugs with different pharmacological properties cause idiosyncratic toxicity, with a common target organ being the liver. Idiosyncratic reactions not only cause human suffering but sometimes result in curtailing use of otherwise effective therapeutic agents.

Idiosyncratic drug responses are commonly thought to arise either from drug metabolism polymorphism or from an allergic response to a drug or its metabolite(s). However, for the vast majority of drugs, supporting evidence for either of these hypotheses is lacking. The ability of modest inflammation to potentiate the toxicity of numerous xenobiotic agents led us to hypothesize that some drug idiosyncrasies may result from episodes of mild inflammation occurring during drug therapy (Buchweitz *et al.*, 2002; Ganey and Roth, 2001).

For example, with respect to chemical-induced hepatotoxicity, induction of inflammation in rats by exposure to a nonhepatotoxic dose of bacterial lipopolysaccharide (LPS) results in a 10-20 fold increase in sensitivity to liver injury from the fungal toxin aflatoxin B₁ (AFB₁) (Luyendyk *et al.*, 2002). This increase in sensitivity is dependent on an LPS-stimulated inflammatory response involving neutrophils (PMNs) and cytokines (Barton *et al.*, 2000b; Barton *et al.*, 2001). Such augmentation of hepatotoxicity by LPS coexposure appears to occur with at least some pharmaceutical agents as well. For example treatment of rats with LPS precipitates liver injury in hypoxic rats exposed to halothane (Lind *et al.*, 1984). A recent study

JPET #54288

demonstrated that coadministration of nontoxic doses of LPS and the antipsychotic drug chlorpromazine results in hepatotoxicity and other effects that occur in idiosyncratic reactions to chlorpromazine in people (Buchweitz *et al.*, 2002). Thus, it appears that inflammation alters hepatotoxicity thresholds for some xenobiotics and pharmaceutical agents.

Another widely used drug associated with idiosyncratic hepatotoxicity is the histamine-2 (H₂) receptor antagonist, ranitidine (RAN). RAN is available over-the-counter for oral administration or by prescription for parenteral administration (s.c., i.m., i.v.) for treatment of duodenal ulcers, gastric hypersecretory diseases and gastroesophageal reflux disease. Idiosyncratic RAN hepatotoxicity occurs in less than 0.1% of people taking the drug (Vial *et al.*, 1991). Most liver reactions are mild and reversible; however, extensive liver damage and death have occurred in individuals undergoing RAN therapy (Ribeiro *et al.*, 2000). Idiosyncratic hepatotoxicity to RAN typically manifests as elevations in serum markers of hepatocellular injury with more modest increases in indicators of cholestatic injury. These reactions are typical of idiosyncrasy as the time of onset of hepatotoxicity relative to initiation of therapy varies greatly, and rechallenge with RAN does not necessarily result in a reoccurrence of toxicity (Halparin, 1984; Hiesse *et al.*, 1985). Indeed, in some cases the adverse response resolves despite continued therapy (Barr and Piper, 1981). Although direct evidence implicating inflammation as a contributing factor to these idiosyncratic reactions is lacking, it is interesting that examination of 24 reports describing 34 human cases of RAN idiosyncratic hepatotoxicity revealed prodromal signs consistent with endotoxemia

JPET #54288

(i.e. increased LPS burden in blood) or inflammation (e.g. diarrhea, fever, nausea/vomiting, and/or abdominal pain) in over 60% of the cases.

The purpose of this study was to test the hypothesis that underlying inflammation triggered by a nonhepatotoxic dose of LPS renders RAN hepatotoxic in rats, revealing a response resembling human RAN idiosyncrasy. Additionally, the hypothesis was tested that the H2 antagonist famotidine (FAM), for which the propensity to cause idiosyncratic reactions is markedly smaller, would not be rendered hepatotoxic by LPS. Finally, the ability of RAN to influence the killing of rat hepatocytes by cytotoxic products released by activated inflammatory cells was explored *in vitro*.

JPET #54288

Materials and Methods:

Materials. Unless otherwise noted, all chemicals were purchased from Sigma Chemical Co. (St. Louis, MO). Lipopolysaccharide derived from *E. coli* serotype O55:B5 with an activity of 6.6×10^6 EU/mg was used for these studies. This activity was determined using a colorometric, kinetic Limulus Amebocyte Lysate (LAL) assay (Kit #50-650U) purchased from Biowhittaker (Walkersville, MD).

Animals. Male, Sprague-Dawley rats (CrI:CD (SD)IGS BR; Charles River, Portage, MI) weighing 250-350 grams (*in vivo* studies) or 90-150 grams (*in vitro* studies) were used for these studies. Animals were fed standard chow (Rodent chow/Tek 8640, Harlan Teklad, Madison, WI) and allowed access to water *ad libitum*. They were allowed to acclimate for 1 week in a 12-h light/dark cycle prior to use.

Experimental Protocol. Rats fasted for 24 hours were given 44.4×10^6 EU/kg LPS or its saline vehicle, i.v. Two hours later 30 mg/kg RAN, 6mg/kg FAM or sterile phosphate-buffered saline (PBS) vehicle was administered i.v. RAN solution was administered at 2 ml/kg at a rate of approximately 0.15 ml/min. Three, 6, 12 and 24 hours later, separate groups of rats were anesthetized with sodium pentobarbital (50 mg/kg, ip) and killed by exsanguination. Blood was allowed to clot at room temperature, and serum was collected and stored at -20° C until use. Representative (3-4 mm) slices of the ventral half of the left lateral liver lobe were collected and fixed in 10% neutral buffered formalin.

Clinical Chemistry. Selected serum enzymes were analyzed using a Beckman-Coulter (Brea, CA) Synchron CX7 random access clinical analyzer powered by version 6.4 CX7 software. Hepatic parenchymal cell injury was estimated as increases in serum

JPET #54288

alanine aminotransferase (ALT) and aspartate aminotransferase (AST) activities. Biliary injury was estimated from increases in gamma-glutamyl transferase (GGT) activity.

Histopathology. Formalin-fixed liver samples (3-4 samples/rat) were embedded in paraffin, sectioned at 5 μm , stained for hematoxylin and eosin (H&E), and examined by light microscopy. All tissue sections were examined by the pathologist without knowledge of treatment (i.e., performed in blinded fashion). All lesions were assigned a score of 0 to 5, with 0 representing no significant lesion and increasingly higher numbers representing progressively more severe lesions.

Hepatocyte isolation. Hepatocytes were isolated using the Gibco Hepatocyte Product Line (Invitrogen, Carlsbad, CA) including liver perfusion medium, liver digest medium, and hepatocyte wash buffer (Cat. Nos 17701, 17703, 17704). All reagents were warmed to 37 $^{\circ}\text{C}$ prior to perfusion. Rats were anesthetized with sodium pentobarbital (50 mg/kg, ip), and the portal vein was cannulated. The liver was initially perfused with 150 ml perfusion medium at a rate of 12 ml/min with excess medium draining from the severed vena cava. This was followed immediately by perfusion with 100 ml of liver digestion medium at a rate of 12 ml/min. The liver was transferred carefully to a culture dish containing hepatocyte wash medium and gently scraped to separate cells. The resulting liver digest was passed through sterile gauze and spun briefly at 50xg to pellet hepatocytes. The resulting pellet was washed two additional times with 50 ml volumes of hepatocyte wash medium. Hepatocytes were then resuspended at a density of 2.5×10^5 cells/ml in Williams' Medium E (Invitrogen, Carlsbad, CA) containing 10% fetal bovine serum (FBS, Atlanta Biologicals, Norcross, GA) and plated in 12-well cell culture plates (Corning-Costar) at 0.80 ml/well. Cells were allowed to attach for 4-5 h before treatment.

JPET #54288

Polymorphonuclear leukocyte (PMN) isolation and conditioned medium (CM) preparation. Rat PMNs were isolated by glycogen elicitation, as described previously (Ganey *et al.*, 1994). Washed PMNs were suspended at a concentration of 2.5×10^6 cells/ml in Williams' Medium E. PMN-conditioned medium (PMN-CM) was prepared by treating PMNs with cytochalasin B (final concentration, 5 $\mu\text{g/ml}$), then 1 minute later with the PMN activator f-Met-Leu-Phe (fMLP) at a concentration of 100nM. PMNs were then incubated at 37°C for 30 min. They were removed by centrifugation and the supernatant (PMN-CM) collected. Aliquots were stored at -80°C until use.

Effect of RAN and FAM on PMN-CM induced cytotoxicity. Serum free Williams' Medium E containing various concentrations of PMN-CM (0, 25 or 50%) and either RAN (0, 175, 526, or 877 $\mu\text{g/ml}$) or FAM (0, 35, 105.2, or 175.4 $\mu\text{g/ml}$) was added after hepatocytes were attached (4-5h). After 16 h, the medium was collected, and the remaining attached cells were lysed with 1% triton X-100 followed by brief sonication. Media and lysates were centrifuged at 600xg for 5 min. Cytotoxicity was assessed by measuring ALT release into the medium using Sigma Diagnostics Infinity ALT reagent (Sigma, St. Louis, MO). ALT activity in the medium was expressed as a percent of total ALT activity (i.e., medium activity plus lysate activity).

Statistical Analyses: Results are presented as mean \pm SEM. For studies *in vivo*, one-way or two-way analysis of variance (ANOVA) was utilized as appropriate. Histopathology scores were compared using a rank sum test. For hepatocyte studies *in vitro*, one- or two-way repeated measures ANOVA was applied after appropriate data transformation. All individual group comparisons were made using Tukey's test. The criterion for significance was $p < 0.05$ for all studies.

JPET #54288

Results:

Dose-ranging studies. Rats were given LPS (44.4×10^6 EU/kg) 2 h before various doses of RAN (0, 10, 20, 25 or 30 mg/kg). Serum ALT activity was evaluated 24 h after RAN administration. A statistically significant increase in ALT activity was not observed in rats cotreated with LPS and RAN at doses of less than or equal to 25 mg/kg, whereas ALT activity was significantly increased in animals cotreated with LPS and 30 mg/kg RAN (Fig. 1A). No dose of RAN alone caused a significant increase in ALT activity, and doses above 30 mg/kg resulted in significant mortality (data not shown). A similar dose-response study was performed for LPS at 30 mg/kg RAN (Fig. 1B). Rats were given various doses LPS (0, 7.4, 14.8, 22.2 or 44.4×10^6 EU/kg) 2 h before 30 mg/kg RAN and ALT activity was evaluated 24 h after RAN. A significant increase in ALT activity was observed in animals cotreated with RAN and an LPS dose as low as 14.8×10^6 EU/kg. Based on these results, doses of RAN and LPS were selected to be 30 mg/kg and 44.4×10^6 EU/kg, respectively, for the remaining studies.

Development of hepatotoxicity after LPS/RAN cotreatment. Rats were given LPS or its vehicle 2 h before RAN or its vehicle. RAN or LPS given alone was without significant effect on ALT (Fig. 2A) activity compared to control at any time evaluated. Treatment with RAN caused a slight but statistically significant increase in AST activity at 12 h but was without effect at other times (Fig. 2B). Since AST is not specific for liver injury and RAN caused no change in serum ALT activity or liver histopathologic change (see below), the small increase in AST activity likely arose from an extrahepatic source. Cotreatment of rats with LPS/RAN resulted in a 6-10-fold increase in ALT (Fig. 2A) and a 7-14-fold increase in AST (Fig. 2B) activities that were significant as early as 6 h after

JPET #54288

RAN treatment and remained elevated through 24 h. Biliary injury, as reflected in serum GGT activity, increased by 6 h after administration of LPS/RAN and remained elevated by at least 1.5-fold through 24 h. RAN or LPS treatment alone had no effect (Fig. 2C).

Histopathological examination. Acute, multifocal, midzonal hepatic necrosis developed in LPS/RAN-cotreated rats as early as 3 h and increasing in severity and incidence through 24 h (Fig. 3). Necrotic foci varied in size and number and were characterized by hepatocellular cytoplasmic eosinophilia and nuclear pyknosis. Variable numbers of infiltrating PMNs, many of which were necrotic, were consistently present within hepatocellular necrotic foci. Qualitatively similar lesions developed in the same time frame in LPS/Veh-treated rats, but with much less severity and frequency as compared to LPS/RAN-cotreated rats. This lesion was not present in any other treatment group. Table 1 presents a summary of the severity of the liver lesion in rats treated with LPS and or RAN over 24 h.

Additional histopathological changes included vasculitis of mild to moderate severity in livers of all rats treated with LPS, irrespective of drug treatment. This began by 3 h in LPS/RAN-treated rats and somewhat later (6 h) in rats treated only with LPS. Diffuse sinusoidal hypercellularity occurred within 3 h to a similar degree in all 3 groups treated with RAN and/or LPS. This comprised hypertrophy of Kupffer cells and increased numbers of sinusoidal PMNs.

Comparison of RAN and FAM. The anti-secretory potency of FAM is at least 5 times greater than RAN in rats (Scarpignato *et al*, 1987). For these studies, doses of RAN and FAM that inhibit gastric acid secretion to a similar degree in rats (30 mg/kg RAN and 6 mg/kg FAM) were used. This dose of FAM was not hepatotoxic when administered

JPET #54288

alone (data not shown). Significant increases in markers of hepatic parenchymal cell injury were not observed in animals cotreated with LPS/FAM after 24 h, whereas marked elevations were observed in animals given LPS/RAN (Fig. 4A and 4B). Similar results were observed for GGT activity (Fig. 4C). Histopathologic evaluation revealed midzonal hepatocellular necrosis in livers of rats treated with LPS/RAN, but this was absent in LPS/FAM-treated rats. Compared to rats treated with LPS alone, no significant increase in ALT activity was observed in rats cotreated with LPS and a dose of FAM that was equimolar to that of RAN (data not shown).

Effect of RAN on killing of hepatocytes by PMN-CM. Cytotoxicity was evaluated by release of ALT into culture medium after 16 h of incubation with RAN/PMN-CM. PMN-CM alone caused a concentration-dependent increase in ALT release (Fig. 5), as reported previously (Ho *et al*, 1996). By itself, RAN did not cause significant ALT release at any concentration used (Fig. 5A). However, it enhanced the hepatocellular killing activity of PMN-CM in a concentration-dependent manner. Pharmacologically equipotent concentrations of FAM were tested for comparison. FAM alone at the largest concentration used caused a very slight, but statistically significant increase in ALT release (Fig. 5B). The cytotoxicity of PMN-CM was unaffected by FAM at any concentration of the drug tested.

JPET #54288

Discussion:

It is widely accepted that idiosyncratic drug reactions arise from production of reactive drug metabolites capable of causing tissue damage or from a specific immune response to drug or drug metabolite haptens. These modes of action have been proposed for RAN idiosyncrasy (Vial *et al.*, 1991), but supporting evidence is lacking, and neither appears to explain easily all features observed in clinical cases of RAN hepatotoxicity. For example, time of onset of hepatotoxicity relative to the initiation of RAN therapy varies greatly: some episodes appear as early as one week, whereas others do not occur until months after the start of maintenance therapy (Hiesse *et al.*, 1985; Halparin, 1984, Ramrakhiani *et al.*, 1998). Furthermore, elevations in markers of hepatocellular damage resolve despite continued RAN therapy (Barr and Piper, 1981), which seems unlikely to occur if accumulation of reactive metabolites is necessary. A role for a specific immune response in RAN idiosyncrasy is equally unsupported. Clinical signs of allergic responses such as eosinophilia have been observed in some cases (Devuyst *et al.*, 1993; Souza Lima, 1984) but is not a consistent finding (Hiesse *et al.*, 1985; Barr and Piper, 1981). Anti-RAN antibodies have not been identified. Additionally, an autoimmune component of RAN idiosyncrasy has not been identified conclusively. Of 14 cases for which the presence of autoantibodies was assessed, only one described the presence of anti-smooth muscle antibodies, albeit at a very low concentration (Barr and Piper, 1981). Additionally, rechallenge with RAN does not always result in a recurrence of toxicity (Graham *et al.*, 1985), as might be expected with drug allergy. Thus, current hypotheses regarding mechanisms of RAN-induced liver injury are not consistent with all of the clinical features of these reactions.

JPET #54288

Interestingly, prodromal indicators consistent with inflammation and endotoxemia are observed in many cases of RAN idiosyncrasy. Evaluation of 34 cases of RAN-related liver injury revealed accounts of diarrhea, fever, nausea/vomiting and/or abdominal pain in nearly 60% of the cases. Exposure of people to inflammagens such as LPS is episodic and commonplace (Roth *et al*, 1997). Indeed, health care providers have noted associations between transient illness characterized by signs consistent with inflammation/endotoxemia and increases in liver enzymes in serum (Barr and Piper, 1981; Halparin, 1984). In addition, factors known to cause translocation of endogenous LPS across the gastrointestinal lumen such as excessive alcohol consumption and surgery have been noted in some cases of RAN idiosyncrasy (Halparin, 1984; Hiesse, 1985). Thus, although no definitive studies in humans have been reported, it appears that hepatotoxic responses to RAN are often accompanied by signs consistent with inflammation.

Modest inflammation can markedly increase sensitivity to hepatotoxic effects of xenobiotic agents (Ganey and Roth, 2001; Luyendyk *et al*, 2002). Thus, it is likely that the liver may emerge as a target organ if an inflammatory episode occurs during RAN treatment. The studies presented herein showed that a normally nonhepatotoxic dose of RAN is rendered hepatotoxic when administered to rats undergoing acute inflammation triggered by LPS. Rats cotreated with LPS/RAN showed a larger change in serum markers of parenchymal cell injury (e.g., ALT, AST) as compared to cholestasis (e.g., GGT). These data are consistent with observations made in clinical cases of human RAN idiosyncrasy, in which increases in serum markers of hepatocellular injury were usually greater than markers of cholestatic injury. Thus, the nature of alterations in serum

JPET #54288

markers of liver damage after treatment of rats with LPS/RAN is similar to RAN idiosyncrasy in people. It should be borne in mind, however, that this model involves acute administration of RAN and may represent one of several mechanisms of idiosyncratic liver injury. Case reports of severe RAN idiosyncrasy describe marked acute inflammatory changes such as intra-acinar accumulation of plasma cells, macrophages, eosinophils and PMNs, accompanied by bridging hepatocellular necrosis (Lauritsen *et al*, 1984; Ribeiro *et al*, 2000). Consistent with the elevated serum ALT and AST activities, lesions in LPS/RAN-treated rats were characterized by acute midzonal hepatocellular necrosis accompanied by large numbers of infiltrating PMNs. The elevation in GGT activity did not have an obvious histological correlate. Although several confounding factors impinge on comparing lesions observed in severe cases of RAN idiosyncrasy in humans and LPS/RAN-treated rats (e.g., time of liver sampling), similar features such as marked inflammatory cell infiltrates and severe hepatocellular necrosis are found in both.

To our knowledge, there have only been 3 published reports linking FAM administration to hepatotoxicity as compared to the 34 published reports for RAN. One report described a hepatotoxic response that occurred greater than 2 months after FAM therapy was discontinued, leading the authors to question whether FAM was responsible (Jimenez-Saenz *et al.*, 2000). The link between FAM and idiosyncratic hepatotoxicity in another case was confounded by earlier RAN treatment, and the authors noted that a RAN contribution could not be ruled out (Ament *et al*, 1994). FAM-associated hepatotoxicity has been observed in a third patient who also developed hepatotoxicity after treatment with the H₂-antagonist cimetidine (Hashimoto *et al*, 1994), suggesting a

JPET #54288

general sensitivity to H₂-receptor antagonists. Accordingly, FAM has been associated with few published reports of idiosyncratic hepatotoxicity, and in those cases the contribution of FAM to hepatotoxic responses described was not clear. Thus, unlike RAN, FAM has little propensity to cause idiosyncratic hepatotoxicity.

We tested the hypothesis that FAM would not have the same hepatotoxic interaction with LPS that occurs with RAN. For people the recommended dose of FAM is less than that for RAN, since FAM is a more potent H₂ receptor blocker (Lin, 1991). Accordingly, pharmacologically equipotent doses of the two drugs were selected based on their relative antisecretory effect and pharmacologic potencies in rats (Scarpignato *et al.*, 1987). Cotreatment of rats with LPS and RAN resulted in the expected hepatocellular damage as marked by increases in serum ALT and AST activities, whereas cotreatment of rats with FAM and LPS was without significant effect. Furthermore, LPS/FAM did not cause an elevation in GGT activity. These results suggest that the ability of inflammation to cause a drug in this class to produce liver injury may be selective for those drugs that have a propensity to cause idiosyncratic reactions in humans.

Rats treated with large doses of LPS develop acute liver injury characterized by midzonal necrosis accompanied by Kupffer cell swelling and marked PMN accumulation (Hewett *et al.*, 1992). Liver lesions resulting from chemical-LPS synergy can resemble those produced by hepatotoxic doses of the chemical or LPS or both (Barton *et al.*, 2000a; Yee *et al.*, 2000). LPS/RAN treatment caused an acute, midzonal, suppurative, necrotizing hepatitis that resembled lesions in animals treated with a hepatotoxic dose of LPS. This result suggests that RAN may increase hepatic parenchymal cell sensitivity to an LPS-like hepatotoxic response. In livers of rats treated with LPS/RAN, inflammatory

JPET #54288

infiltrates comprised predominately PMNs, suggesting the possibility of a role for these cells in LPS/RAN liver injury. In other models of interaction between xenobiotic agents and LPS, PMNs are present in the liver lesions and contribute to the hepatotoxic response (Barton *et al*, 2000b; Yee *et al*, 2003). PMNs are also critically involved in the hepatotoxic response to large, toxic doses of LPS and probably act through the release of cytotoxic factors when these cells are activated (Hewett *et al*, 1992; Ho *et al*, 1996).

The exact role of PMNs in LPS/RAN liver injury has not been evaluated. Interestingly, RAN attenuates liver injury after ischemia-reperfusion, probably by inhibiting release of cytotoxic factors by PMNs (Okajima *et al*, 2002). Previous studies demonstrated that RAN was nontoxic to hepatocytes even at high (e.g., 5mM) concentrations (Zimmerman *et al*, 1986), and our results confirmed these previous findings (Fig. 5). However, hepatocytes treated with RAN were rendered more sensitive to killing by cytotoxic factors released by activated PMNs. In the context of observations in LPS/RAN-treated rats, these results suggest that RAN may act by increasing hepatocellular sensitivity to PMN-derived factors. In contrast, FAM did not increase the sensitivity of hepatocytes to killing by PMN-derived cytotoxic factors. Since pharmacologically equipotent concentrations were used, this suggests that the sensitizing effect of RAN on hepatocytes is independent of H2 receptor blockade. Further studies are needed to understand the mechanism by which RAN alters hepatocyte sensitivity to PMN-derived products.

In summary, RAN was rendered hepatotoxic in rats undergoing a mild inflammatory response triggered by LPS. LPS/RAN-cotreated animals developed midzonal necrosuppurative hepatitis, and a liver-related clinical chemistry pattern

JPET #54288

resembling human cases of RAN idiosyncrasy. In contrast, animals cotreated with LPS and a pharmacologically equipotent or equimolar dose of FAM did not develop liver damage, a result consistent with the far lesser (and debatable) propensity of FAM to cause idiosyncrasy in people. Treatment of hepatocytes *in vitro* with RAN, but not with FAM, increased hepatocellular sensitivity to cytotoxicity from PMN-derived factors. Overall, our demonstration that modest inflammation causes the emergence of liver as a target for RAN toxicity in rats suggests a role for inflammation in idiosyncratic reactions to this H₂-antagonist. In addition, the results raise the possibility of developing animal and cell-based models for predicting which drug candidates are more or less likely to cause idiosyncratic reactions in people and for studying the underlying mechanisms by which these reactions occur.

JPET #54288

Acknowledgments: The authors thank Dave Blakeman for technical assistance.

JPET #54288

References:

- Ament PW, Roth JD and Fox CJ (1994) Famotidine-induced mixed hepatocellular jaundice. *Ann Pharmacother* **28**: 40-42.
- Barr GD and Piper DW (1981) Possible ranitidine hepatitis. *Med J Aust* **2**: 421.
- Barton CC, Hill DA, Yee SB, Barton EX, Ganey PE and Roth RA (2000a) Bacterial lipopolysaccharide exposure augments aflatoxin B(1)-induced liver injury. *Toxicol Sci* **55**: 444-452.
- Barton CC, Ganey PE and Roth RA (2000b) Lipopolysaccharide augments aflatoxin B(1)-induced liver injury through neutrophil-dependent and -independent mechanisms. *Toxicol Sci* **58**: 208-215.
- Barton CC, Barton EX, Ganey PE, Kunkel SL and Roth RA (2001) Bacterial lipopolysaccharide enhances aflatoxin B1 hepatotoxicity in rats by a mechanism that depends on tumor necrosis factor alpha. *Hepatology* **33**: 66-73.
- Buchweitz JP, Ganey PE, Bursian SJ and Roth RA (2002) Underlying endotoxemia augments toxic responses to chlorpromazine: is there a relationship to drug idiosyncrasy? *J Pharmacol Exp Ther* **300**: 460-7.
- Devuyst O, Lefebvre C, Geubel A and Coche E (1993) Acute cholestatic hepatitis with rash and hypereosinophilia associated with ranitidine treatment. *Acta Clin Belg* **48**: 109-114.
- Ganey PE, Bailie MB, VanCise S, Colligan ME, Madhukar BV, Robinson JP and Roth RA (1994) Activated neutrophils from rat injured isolated hepatocytes. *Lab Invest* **70**: 53-60.
- Ganey PE and Roth RA (2001) Concurrent Inflammation as a Determinant of Susceptibility to Toxicity from Xenobiotic Agents. *Toxicology* **169**: 195-208.
- Graham DY, Opekun AR, Smith JL and Schwartz JT (1985) Ranitidine and Hepatotoxicity. *Ann Intern Med* **102**: 416.
- Halparin LS (1984) Adverse effects of ranitidine therapy. *Can Med Assoc J* **130**: 668-669.
- Hashimoto F, Davis RL and Egli D (1994) Hepatitis following treatments with famotidine and then cimetidine. *Ann Pharmacother* **28**: 37-39.
- Hewett JA, Schultze AE, Van Cise S and Roth RA (1992) Neutrophil depletion protects against liver injury from bacterial endotoxin. *Lab Invest* **66**: 347-361.

JPET #54288

Hiesse C, Cantarovich M, Santelli C, Francais P, Charpentier B, Fries D and C Buffet (1985) Ranitidine hepatotoxicity in a renal transplant patient. *Lancet* **1**: 1280

Ho JS, Buchweitz JP, Roth RA and Ganey PE (1996) Identification of factors from rat neutrophils responsible for cytotoxicity to isolated hepatocytes. *J Leukoc Biol* **59**: 716-724.

Jimenez-Saenz M, Arguelles-Arias F, Herrerias-Gutierrez JM and Duran-Quintana JA (2000) Acute Cholestatic Hepatitis in a Child Treated with Famotidine. *Am J Gastroenterol* **95**: 3665-6.

Lauritsen K, Havelund T and Rask-Madsen, J (1984) Ranitidine and Hepatotoxicity. *Lancet* **2**: 1471.

Lin JH (1991) Pharmacokinetic and Pharmacodynamic Properties of Histamine H₂-Receptor Antagonists: Relationship Between Intrinsic Potency and Effective Plasma Concentrations. *Clin Pharmacokinet* **20**: 218-236.

Lind RC, Gandolfi AJ, Sipes IG and Brown BR Jr (1984) The involvement of endotoxin in halothane-associated liver injury. *Anesthesiology* **61**: 544-50.

Luyendyk JP, Shores KC, Ganey PE and Roth, RA (2002) Bacterial lipopolysaccharide exposure alters aflatoxin B₁ hepatotoxicity: Benchmark analysis for markers of liver injury. *Toxicol Sci* **68**: 220-5.

Okajima K, Harada N and Uchiba M (2002) Ranitidine reduces ischemia/reperfusion-induced liver injury in rats by inhibiting neutrophil activation. *J Pharmacol Exp Ther* **301**: 1157-65.

Ramrakhiani S, Brunt EM and Bacon BR (1998) Possible cholestatic injury from ranitidine with a review of the literature. *Am J Gastroenterol* **93**: 822-6.

Ribeiro JM, Lucas M, Baptista A and Victorino R-MM (2000) Fatal hepatitis associated with ranitidine. *Am J Gastroenterol* **95**: 559-560.

Roth RA, Harkema JR, Pestka JP and Ganey PE (1997) Is exposure to bacterial endotoxin a determinant of susceptibility to intoxication from xenobiotic agents? *Toxicol Appl Pharmacol* **147**: 300-311.

Scarpignato C, Tramacere R and Zappia L (1987) Antisecretory and antiulcer effect of H₂-receptor antagonist famotidine in the rat: comparison with ranitidine. *Br J Pharmacol* **92**: 153-159.

Souza Lima MA (1984) Hepatitis associated with ranitidine. *Ann Intern Med* **101**: 207-8.

JPET #54288

Vial T, Goubier C, Bergeret A, Cabrera F, Evreux J-C and Descotes J (1991) Side Effects of ranitidine. *Drug Saf* **6**: 94-117.

Yee SB, Kinser S, Hill DA, Barton CC, Hotchkiss JA, Harkema JR, Ganey PE and Roth RA (2000) Synergistic hepatotoxicity from coexposure to bacterial endotoxin and the pyrrolizidine alkaloid monocrotaline. *Toxicol Appl Pharmacol* **166**: 173-85.

Yee SB, Hanumegowda UM, Hotchkiss JA, Ganey PE and Roth RA (2003) Role of neutrophils in the synergistic liver injury from monocrotaline and bacterial lipopolysaccharide exposure. *Toxicol Sci* **72**: 43-56.

Zimmerman HJ, Jacob L, Bassan H, Gillespie J, Lukacs L and Abernathy CO (1986) Effects of H₂-Blocking Agents on Hepatocytes *in Vitro*: Correlation with Potential for Causing Hepatic Disease in Patients. *Proc Soc Exp Biol Med* **182**: 511-514.

JPET #54288

Footnotes

This work was supported by grants from Pharmacia Corporation and NIH (ES01439).

James Luyendyk was partially supported by training grant number 5 T32 ES07255 from the National Institute of Environmental Health Sciences (NIEHS), NIH.

JPET #54288

Figure Legends:

Fig 1. Dose-ranging studies with RAN and LPS. (A) Rats were treated with 44.4×10^6 EU/kg LPS, (iv), then two hours later with various doses of RAN (0, 10, 20, 25 or 30 mg/kg) (iv). n= 3-10 animals per group. (B) Rats were treated with various doses of LPS (0, 7.4, 14.8, 22.2 or 44.4×10^6 EU/kg), (iv), then two hours later with 30 mg/kg RAN, (iv). n= 4-7 animals per group. Hepatic parenchymal cell injury was estimated 24 h after RAN administration from increases in serum ALT activity. Data are expressed as mean \pm SEM. *Significantly different from respective control group ($p < 0.05$).

Fig 2. Hepatotoxicity from LPS/RAN cotreatment. Rats were treated with 44.4×10^6 EU/kg LPS or its vehicle (iv), then two hours later with 30 mg/kg RAN or its vehicle (iv). Hepatic parenchymal cell injury was estimated 3, 6, 12 or 24 h after RAN administration by increases in serum (A) ALT and (B) AST activities. Cholestatic injury was estimated from increases in serum (C) GGT activity. n= 6-17 rats per group. Data are expressed as mean \pm SEM. *Significantly different from all other groups at the same time.

#Significantly different from Veh/Veh-treated rats at that time ($p < 0.05$).

Fig 3. Representative photomicrographs of liver after LPS/RAN cotreatment. Rats were treated with 44.4×10^6 EU/kg LPS or its vehicle (iv), then two hours later with 30 mg/kg RAN or its vehicle (iv). Livers were removed 3 (A), 6 (B), 12 (C) or 24 h (D) after RAN administration, fixed in 10% neutral-buffered formalin, stained for H&E, and examined by light microscopy. Acute, multifocal, necropurulent hepatitis (arrows) was present at each time period, and increased in severity and frequency from 3 to 24 h. The inset in

JPET #54288

panel D shows infiltrating PMNs, many of which are necrotic themselves. CV indicates central vein.

Fig 4. Comparison of LPS/RAN and LPS/FAM cotreatments. Rats were treated with 44.4×10^6 EU/kg LPS or its vehicle (iv), then two hours later with either 30 mg/kg RAN, a pharmacologically equipotent dose of FAM (6 mg/kg) or vehicle (iv). Hepatic parenchymal cell injury was estimated 24 h after H2 antagonist administration as increases in serum (A) ALT and (B) AST activities. Cholestatic injury was estimated as increases in serum (C) GGT activity. Data are expressed as mean \pm SEM. n=5-21 rats per group. *Significantly different from LPS/Veh-treated rats ($p < 0.05$).

Fig 5. Effect of RAN and FAM on killing of hepatocytes by PMN-CM. Rat hepatocytes were cultured at a cell density of 2.5×10^5 cells/ml in Williams' Medium E containing 10% FBS. Four h later the medium was changed to serum-free medium containing conditioned medium from activated PMNs (PMN-CM) at a concentration of 0, 25 or 50%, and either (A) RAN or (B) FAM at the concentrations indicated. Cytotoxicity was evaluated as ALT released into culture medium 16 h later. Data are expressed as mean \pm SEM. For RAN treatment, n=6 separate hepatocyte isolations. For FAM treatment, n=3 separate hepatocyte isolations. *Significantly different from respective treatment in the absence of PMN-CM. # Significantly different from the value at the same % PMN-CM in absence of drug. ($p < 0.05$).

JPET #54288

Table 1

Midzonal Hepatic Necrosis after LPS/RAN Cotreatment

Treatment	Time after RAN (h)			
	3	6	12	24
Veh/Veh	0	0	0	0
LPS/Veh	0	0.2 (0-1)	0.3 (0-2)	0.5 (0-2)
Veh/RAN	0	0	0	0
LPS/RAN	0.2 (0-1)	0.7 (0-3)	1.6 (0-3)*	2.0 (0-4)*

Rats were treated with 44.4×10^6 EU/kg LPS or its vehicle (iv), then two hours later with 30 mg/kg RAN or its vehicle (iv). Livers were removed 3, 6, 12 or 24 h after RAN treatment, fixed in 10% neutral buffered formalin, and evaluated by light microscopy.

Lesions characterized by midzonal hepatocellular necrosis were assigned a histopathology score based on the following scale: 0, no significant lesion; 1, minimal; 2, mild; 3, moderate; 4, marked; 5, severe. n= 6-17 rats per group. Data are expressed as mean and range of scores for each group.

* Significantly different from Veh/Veh-treated rats at that time (p<0.05).

Figure 1

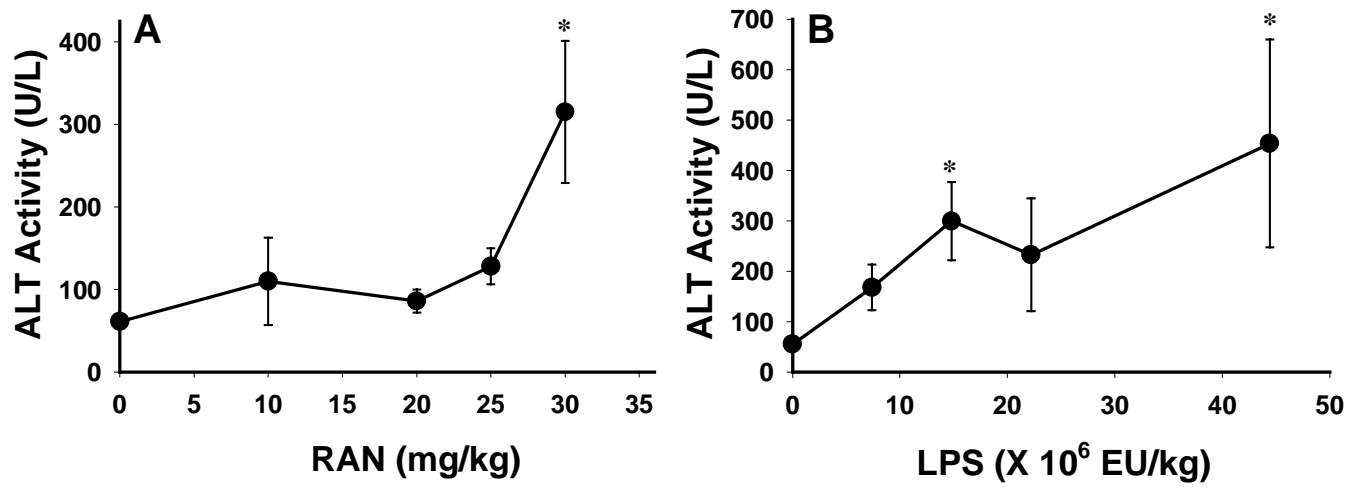


Figure 2

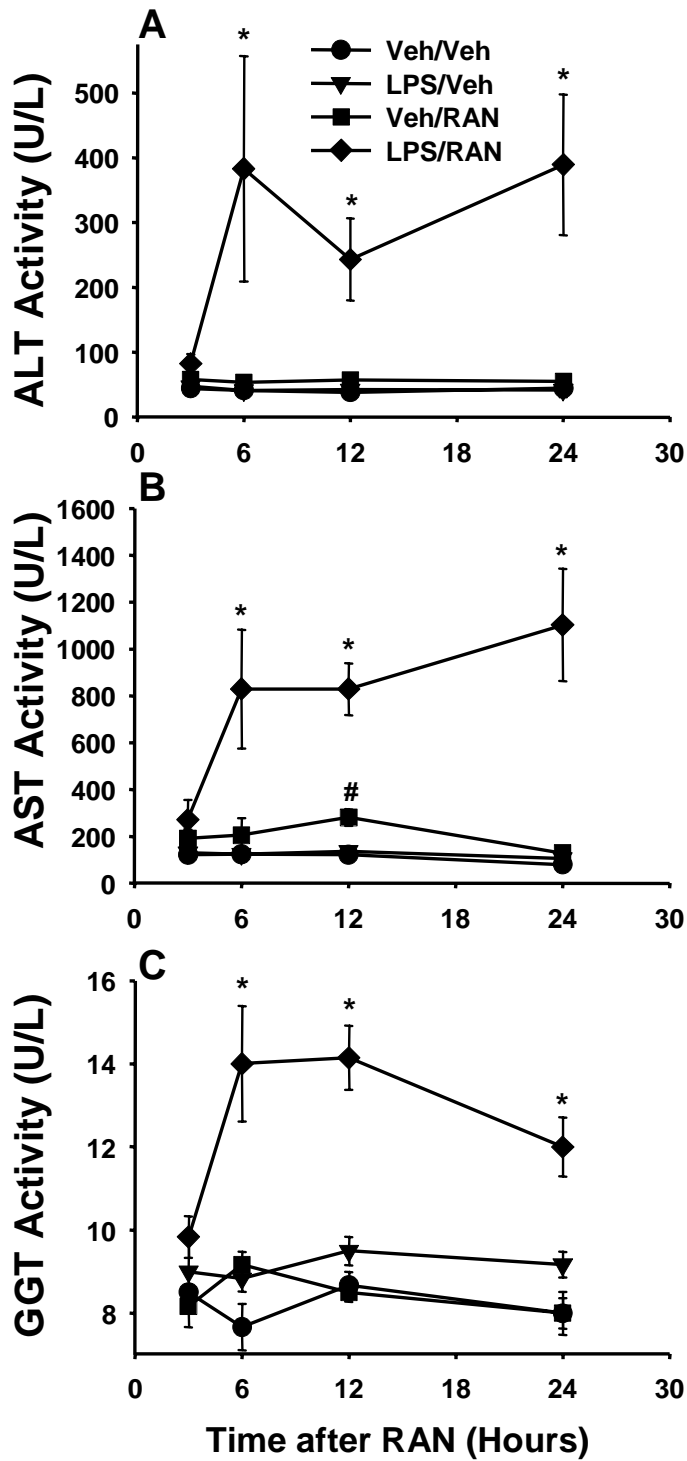


Figure 3

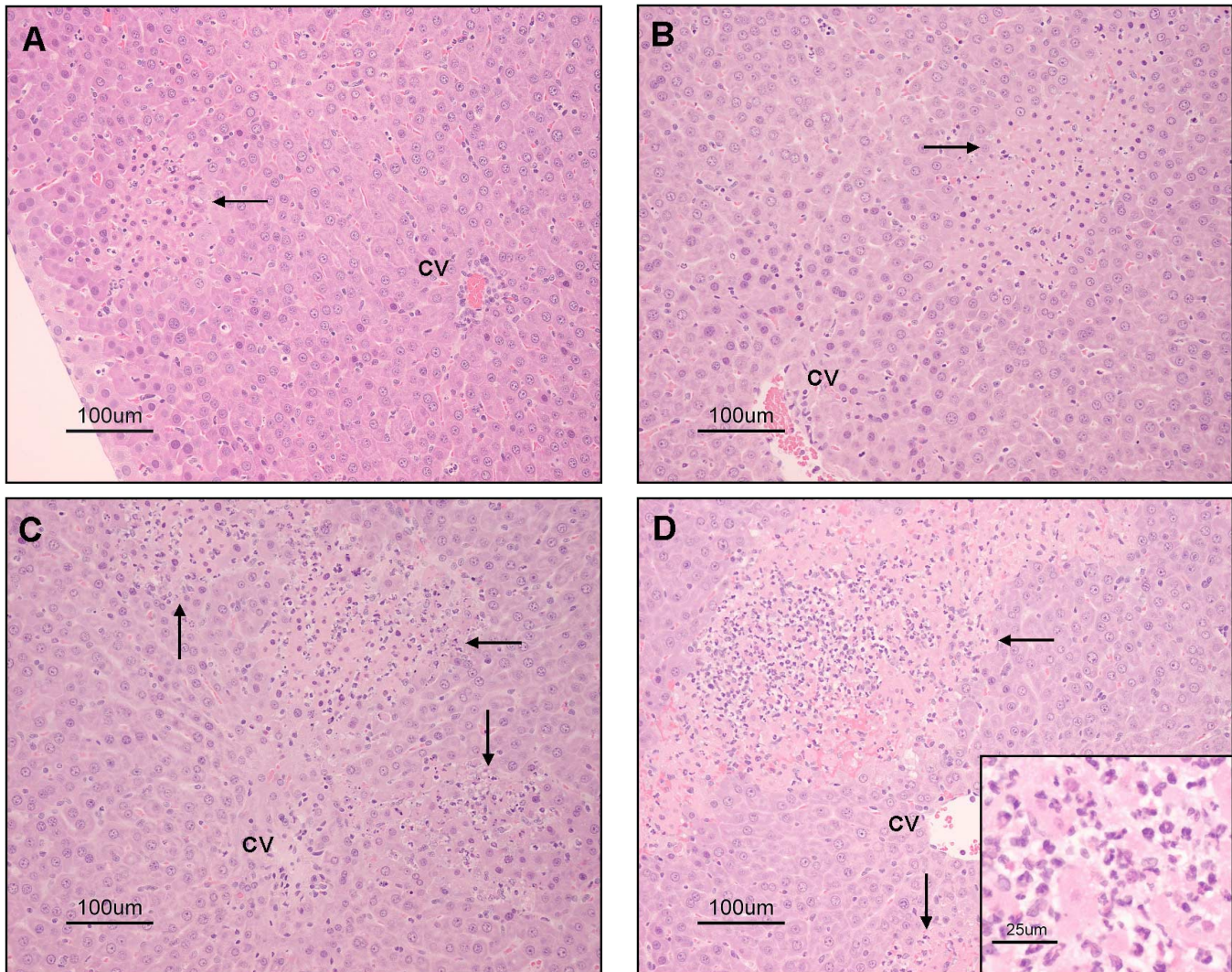


Figure 4

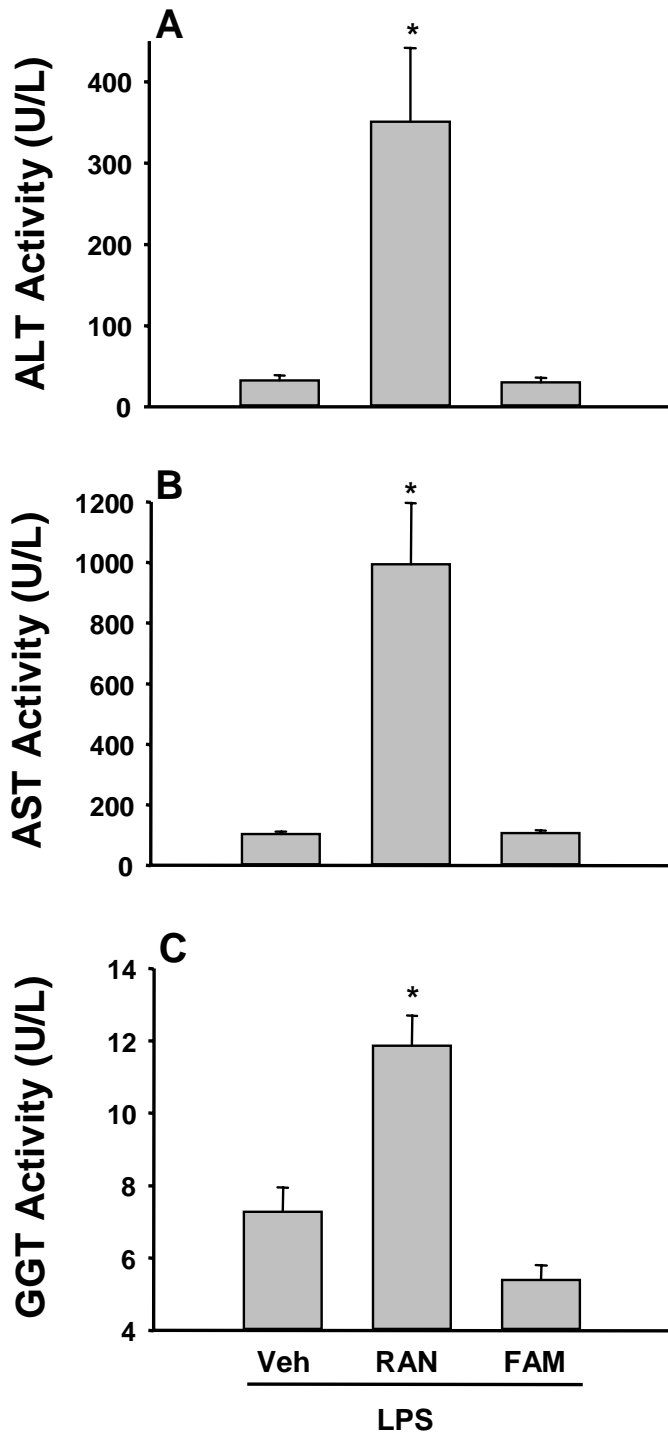


Figure 5

