

Correction to “Magnetic Resonance Imaging Detection and Time Course of Cerebral Microhemorrhages during Passive Immunotherapy in Living Amyloid Precursor Protein Transgenic Mice”

In this article [Luo F, Rustay NR, Seifert T, Roesner B, Hradil V, Hillen H, Ebert U, Severin JM, Cox BF, Llano DA, Day M, and Fox GB (2010) *J Pharmacol Exp Ther* 335:580–588], Fig. 8 was printed in black and white instead of color because of an error during figure processing at the printer. The corrected figure appears below.

The online version of this article has been corrected in departure from the print version.

The printer regrets this error and apologizes for any confusion or inconvenience it may have caused.

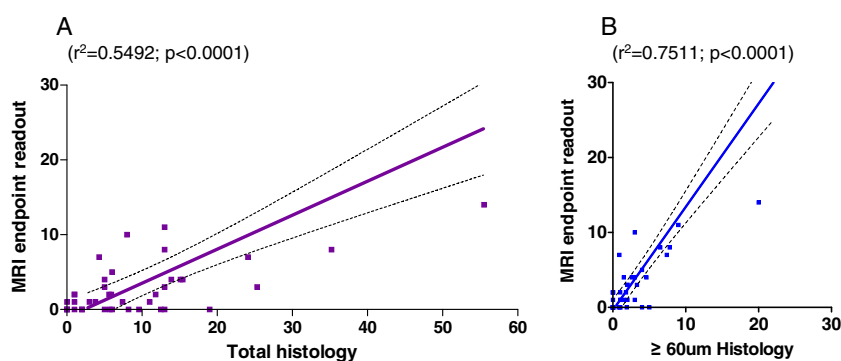


Fig. 8. Correlation of MRI and histology in two longitudinal studies. A, MRI quantification of microhemorrhages versus histology quantification of all detectable microhemorrhages. B, MRI quantification of microhemorrhages versus histology quantification of microhemorrhages with lesion size $\geq 60 \mu\text{m}$.